Korean J Med Mycol 22(4), 2017
http://dx.doi.org/10.17966/KJMM.2017.22.4.182

Letter to the Editor

Imagery Conduciveness in the Diagnosis of Cryptococcal Meningitis

Osung Kwon[1], Hyejoo Ra[2], Jaehan Park[2] and Joonsoo Park[1†]

Department of Dermatology, School of Medicine, Catholic University of Daegu, Daegu, Korea[1]
Department of Neurology, School of Medicine, Catholic University of Daegu, Daegu, Korea[2]

Fungal meningitis has been recognized as a rarer clinical entity that heavily depends on the immunity of the host and virulence factors of fungi[1]. However, incidence of fungal meningitis continues to expand as susceptible risk factors such as organ transplants, chemotherapies, acquired immunodeficiency syndromes increase[2]. An aggressive diagnostic approach through various modalities and subsequent antifungal therapy is imperative to reduce morbidity and mortality.

An 80-year-old male patient was brought to the emergency department complaining of confusion for the past day. The patient was admitted at a secondary-based hospital due to fever and progressive weakness associated with poor oral intake for the past 10 days. Other than chronic hepatitis C infection, the patient was in good health. Neurological evaluation confirmed of drowsy mental status combined with disorientation and speech impairment. Other than fever (38.3℃), leukocytosis (14,900/mm^3) and hyponatremia (122 mEq/L), vital signs and routine laboratory test were within normal limits. Non-enhanced views of computed tomography (CT) revealed no specific hemorrhages or bony abnormalities.

Magnetic resonance imaging (MRI) with T1 weighted gadolinium enhanced image revealed prominent leptomeningeal enhancement of pial surface ambient to cistern and cerebral hemisphere (Fig. 1A, 1B). The nature of the enhancement exhibited smooth, thick, and irregularly discontinuous in nature. Concomitant cerebrospinal fluid (CSF) analysis (leukocyte 90/HPF, PMN 30/HPF, lymphocytes 70/HPF, erythrocytes 60/HPF, glucose 31 mg/dl (serum glucose 102 mg/dl), protein 160.3 mg/dl) was not consistent with that of viral meningitis and empirical intravenous ceftriaxone 2 g and oral azithromycin 500 mg was started. *Cryptococcus* antibody along with fungal culture, however, was also tested upon irregularity of focally thickened leptomeningeal enhancement observed in MRI. After administration of intravenous antibiotics for one week, fever persisted and mental confusion did not improve. Follow-up MRI performed and was correlated a higher degree of fungal infection. Multiple patchy nodular enhancement in the basal and

Received: September 30, 2017, Revised: November 21, 2017, Accepted: November 28, 2017
†Corresponding author: Joonsoo Park, Department of Dermatology, School of Medicine, Catholic University of Daegu, 33 Duryugongwon-ro 17gil, Namgu, Daegu, 42472, Korea.
Tel: +82-53-650-4161, Fax: +82-53-650-4891, e-mail: magincia@cu.ac.kr
Copyright@2017 by The Korean Society for Medical Mycology (pISSN:1226-4709, eISSN:2465-8278). All right reserved.
This is an open-access article distributed under the terms of the Creative Commons Attribution Non-Commercial License(http://creativecommons.org/licenses/by-nc/3.0/), which permits unrestricted non-commercial use, distribution, and reproduction in any medium, provided the original work is properly cited. http://www.ksmm.org

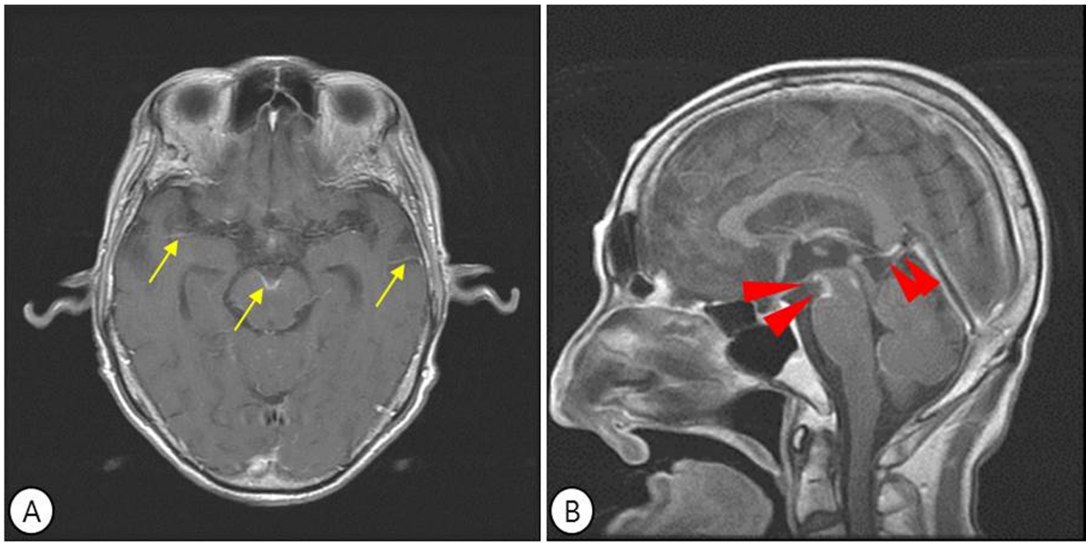

Fig. 1. Initial contrast-enhanced magnetic resonance images **(A)** Axial gadolinium-enhanced T1-weighted magnetic resonance image shows patchy thickened and prominent leptomeningeal enhancement of pial surfaces ambient to cistern and cerebrohemispheres in a discontinuous manner (yellow arrows). **(B)** Sagittal gadolinium-enhanced T1-weighted magnetic resonance image displaying leptomeningeal enhancement around cistern (red arrowheads)

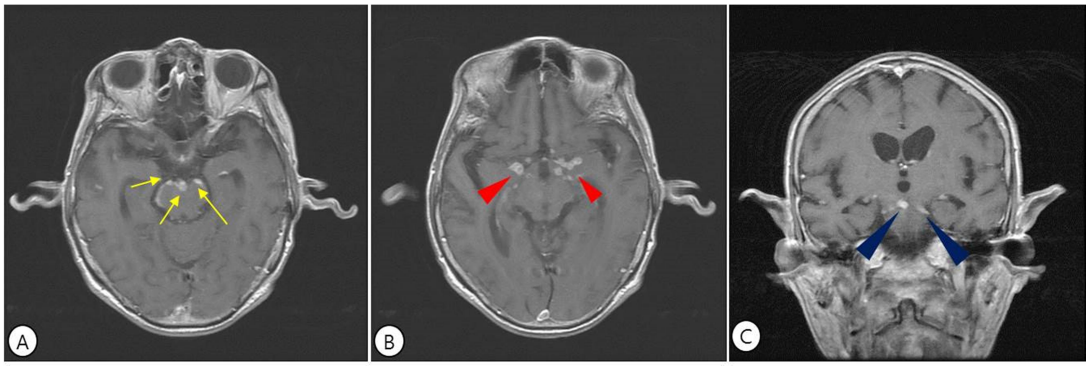

Fig. 2. (A) Axial gadolinium-enhanced T1-weighted magnetic resonance image shows reveals progressed nature of thickening of prominent leptomeningeal enhancement of pial surfaces ambient to cistern and cerebrohemispheres (yellow arrows). **(B)** Axial gadolinium-enhanced T1-weighted magnetic resonance image presents multiple patchy nodular enhancement in the basal cistern and perimesencephalic cistern, suspicious of granulomatous changes (red arrowheads). **(C)** Coronal gadolinium-enhanced T1-weighted magnetic resonance image presents multiple patchy nodular enhancement in the basal cistern, suspicious of granulomatous changes (blue arrowheads).

perimesencephalic cisterns were more definitive of fungal meningitis (Fig. 2A, 2B, 2C). The fungal infectivity was confirmed by positive *Cryptococcus* immunoglobulin test and the medication was changed to intravenous amphotericin B (60 mg) and fluconazole (400 mg). Colonies of the fungal culture

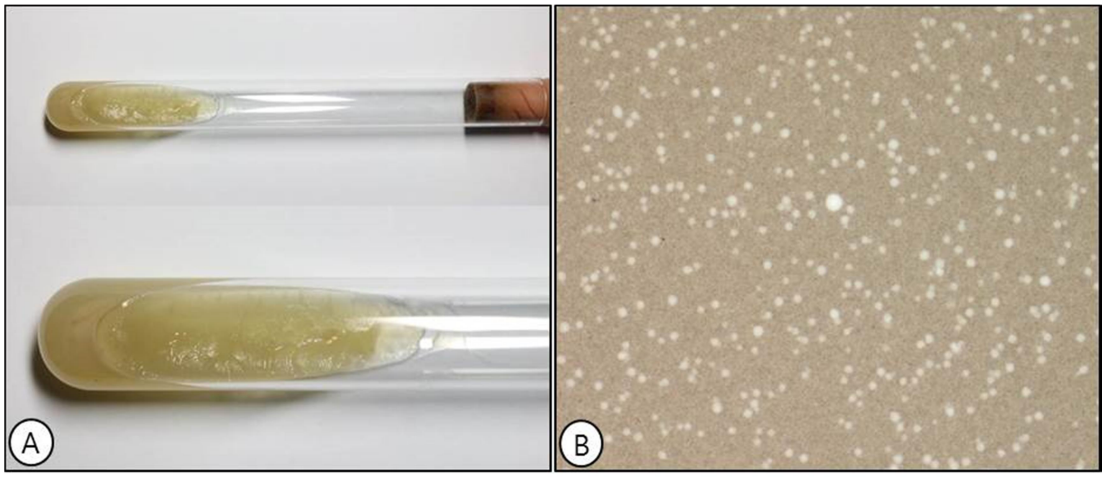

Fig. 3. (A) Shiny amorphous surfaced colonies with mucous texture are presented on glucose-peptone agar. **(B)** Numerous yeasts surrounded by highlighted capsules are shown with India ink preparation under direct light microscopy (India ink ×400).

exhibited shiny light brownish color with mucoid texture and presented highlighted capsules under direct microscopy of India ink, consistent with that of *Cryptococcus* (Fig. 3A, 3B). Subsequent improvement of in CSF study was observed after 3 weeks of antifungal therapy.

Fungal meningitis is known as a mycotic infection to the central nervous system (CNS)[3]. Immunity and age are the two most important risk factors of the entity. It is prevalently caused by yeasts especially; *Cryptococcus* and positive antibody to the organism through CSF analysis generates a confirmative diagnosis[4]. Although the diagnosis based on mycological evaluation, neuroimaging exhibits diagnostic value as disease correlation is observed over 40% of the patients[5-7].

CT scans are regarded nonspecific in most cases for CNS cryptococcosis as 43% of the patients demonstrated unremarkable findings in a retrospective study[8]. MRI provides a more sensitive diagnostic tool for the study[9]. While typical enhancement of the meninges is thin, symmetric, linear, and discontinuous leptomeningeal enhancement in fungal infection may exhibit thicker and nodular nature with poor demarcations[1]. The *Cryptococci* produce a mucoid material in inflammatory response and deposition of thick gelatinous exudates containing inflammatory cells, fibrin, and clotted materials also prone to developing arachnoiditis[10,11]. The perivascular spaces may be enlarged as a result of the production of voluminous mucoid material and invites a number of differentials including tuberculosis, sarcoid, or meningeal carcinomatosis[1]. However the imaging appearance of smooth and nodular leptomeningeal enhancement is often encountered in fungal infections and generates further confirmative measures for mycological elucidation.

In the present case, the patient was not immunologically challenged and the laboratory results including CSF study was insufficient to indicate that of a fungal infection. Neurological abnormalities were masked by senility and hyponatremia for muscular weaknesses. Empirical coverage of antibiotics is prevalently administered upon CSF study

inconsistent with viral meningitis. However, the insidious nature along with pictorial clues to fungal meningitis in MRI delivered a sounder course of treatment. This case underlines the imagery features and its clinical conduciveness in confronting cases of fungal meningitis.

[Korean J Med Mycol 2017; 22(4): 182-185]

Key Words: Cryptococcus, Meningitis, MRI

Conflict of interest

In relation to this article, I declare that there is no conflict of interest.

REFERENCES

1. Gavito-Higuera J, Mullins CB, Ramos-Duran L, Olivas Chacon CI, Hakim N, Palacios E. Fungal infections of the central nervous system: a pictorial review. J Clin Imaging Sci 2016;6:24
2. Mohan S, Jain KK, Arabi M, Shah GV. Imaging of meningitis and ventriculitis. Neuroimaging Clin N Am 2012;22:557-583
3. Mathur M, Johnson CE, Sze G. Fungal infections of the central nervous system. Neuroimaging Clin N Am 2012;22:609-632
4. Perfect JR, Durack DT. Fungal Meningitis. In: Scheld WM, Whitely RJ, Durack DT. Infections of the central nervous system. 2nd ed. Philadelphia: Lippincott-Raven Publishers, 1997:721-724
5. Dubbioso R, Pappata S, Quarantelli M, D'Arco F, Manganelli F, Esposito M, et al. Atypical clinical and radiological presentation of cryptococcal choroid plexitis in an immunocompetent woman. J Neurol Sci 2013;334:180-182
6. Nakajima H, Takayama A, Fujiki Y, Ito T, Kitaoka H. Refractory *Cryptococcus neofromans* meningoencephalitis in an immunocompetent patient: paradoxical antifungal therapy-induced clinical deterioration related to an immune response to cryptococcal organisms. Case Rep Neurol 2015;7:204-208
7. Sarkis RA, Mays M, Isada C, Ahmed M. MRI findings in cryptococcal meningitis of the non-HIV population. Neurologist 2015;2:40-45
8. Popovich MJ, Arthur RH, Helmer E. CT of intracranial cryptococcosis. AJR Am J Roentgenol 1990; 154:603-606
9. Patronas NJ, Makariou EV. MRI of choroidal plexus involvement in intracranial cryptococcosis. J Comput Assist Tomogr 1993;17:547-550
10. Aiken AH. Central nervous system infection. Neuroimaging Clin N Am 2010;20:557-580
11. Arnder L, Castillo M, Heinz ER, Scatliff JH, Enterline D. Unusual pattern of enhancement in cryptococcal meningitis: *in vivo* findings with postmortem correlation. J Comput Assist Tomogr 1996;20:1023-1026