대한의진균학회지 제 1권 제 1호 1996
Kor J Med Mycol Vol. 1, No. 1, 1996

A Case of Cutaneous Pseudallescheriasis

**Dong Jun Kim, Ho Youn Jo, Seung Hyun Hong, Gil Ju Yi*
Il Hwan Kim and Chil Hwan Oh**

*Department of Dermatology, Korea University, College of Medicine, Seoul, Korea
and Kwangju Armed Forces General Hospital*, Kwangju, Korea*

INTRODUCTION

Pseudallescheria boydii is a true fungus (Eumycota) frequently isolated from soil, polluted water, sewage, etc[1]. It is an opportunistic pathogen and a principal cause of mycetoma of the extremities. This disease is widely distributed in temperate and subtropical area. Pseudallescheria infection other than mycetoma are usually associated with immunosuppressive therapy, malignant lesion or other underlying disorders[1-5]. The diseases caused by *P. boydii* include cutaneous and subcutaneous granulomata, sinusitis, brain abscess, meningitis, pulmonary colonization, fungus ball, invasive pneumonitis, endocarditis, arthritis, osteomyelitis, and disseminated systemic disease[2,5]. The lung is the most common site of extracutaneous infection by *P. boydii*[2]. We report a case of cutaneous *P. boydii* infection and review the literatures.

REPORT OF A CASE

A 70-year-old female farmer visited our clinic due to pruritic skin lesions on the both forearms and hands for about 5 months. Skin lesions showed the dusky erythematous oozing papules and plaques with crusts on the both forearms and hands, especially dorsal aspect (Fig. 1A, B). There was no lymphadenopathy and hepatosplenomegaly. There had been no history of preceding trauma to lesion sites.

Roentgenogram examination of the chest, both forearm and hands disclosed no abnormality. The hematocrit was 38 per cent, leukocyte count 7500/mm^3. Differential count showed normal finding. Blood chemistry values were within normal limits. The fasting blood sugar and pc 2hr was within normal limits. Urinalysis disclosed no abnormality. The CMI multitest showed negative finding to all antigens. Serum immunoelectrophoresis and protein electrophoresis showed normal findings.

Previously reported methods were used to identify isolates of P. boydii on the basis of morphologic features. The histopathologic examination of skin lesion revealed hyphae and spores and inflammatory cell infiltration consisted of lymphocytes, neutrophils, and histiocytes in the upper dermis(Fig. 2,3). The transmission electron microscopic finding revealed the conidium in biopsy specimen(Fig. 4). Fungus culture with a piece of tissue on Sabouraud media showed brownish gray colored cottony aerial mycelia with a gray-green reverse side within one week at both 25°C and 37°C(Fig. 5). Fungi are characterized by branched conidiophores with a single or a group of conidia at the tips with or without annelation(Fig. 6). In scanning electron micro-

†Corresponding Author: Dong Jun Kim, Department of Dermatology, Guro Hospital, College of Medicine, Korea University, 80, Guro-dong, Guro-ku, Seoul, 152-050, Korea.

Fig. 1A. Dusky erythematous oozing papules and plaques with crust on the both forearms and hands.

Fig. 1B. Close observation.

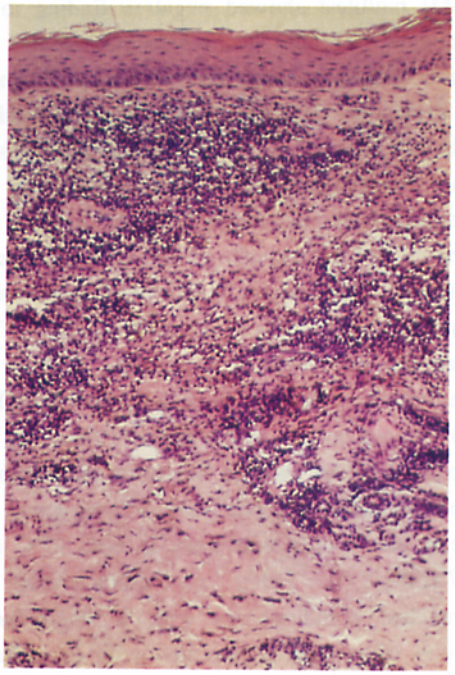

Fig. 2. Inflammatory cells infiltration consisted of lymphocytes, neutrophils, and histiocytes in the upper dermis (H & E stain, ×100).

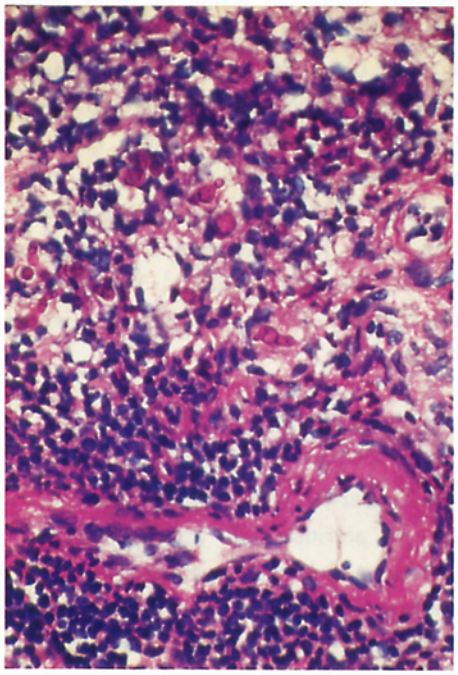

Fig. 3. Hyphae and spores in the upper dermis (PAS stain, ×200).

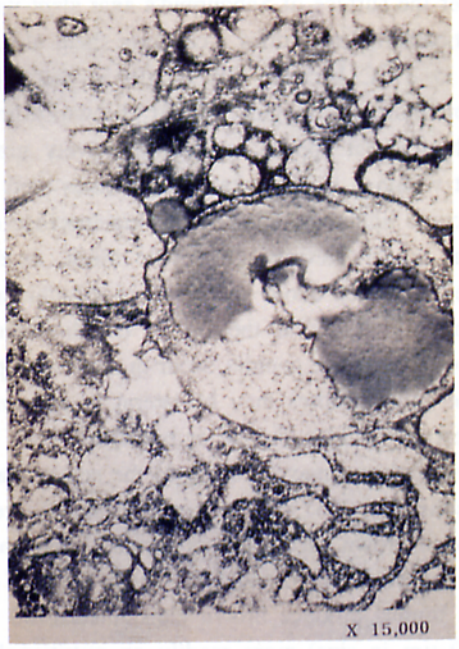

Fig. 4. Transmission electron microscopic finding :conidium in biopsy specimen.

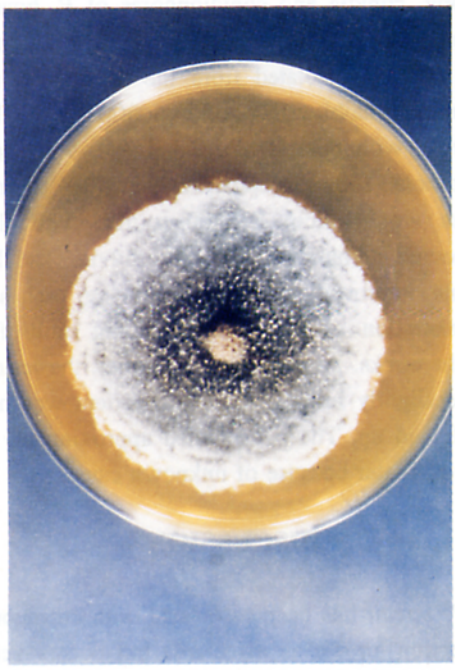

Fig. 5. Brownish gray colored cottony aerial mycelia on Sabouraud's media at a week at 25°C.

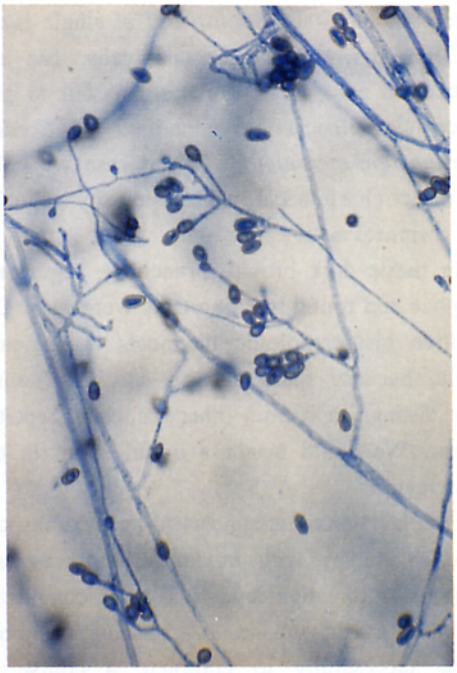

Fig. 6. Branched conidiophores with a single or a group of conidia at the tips with or without annelation.

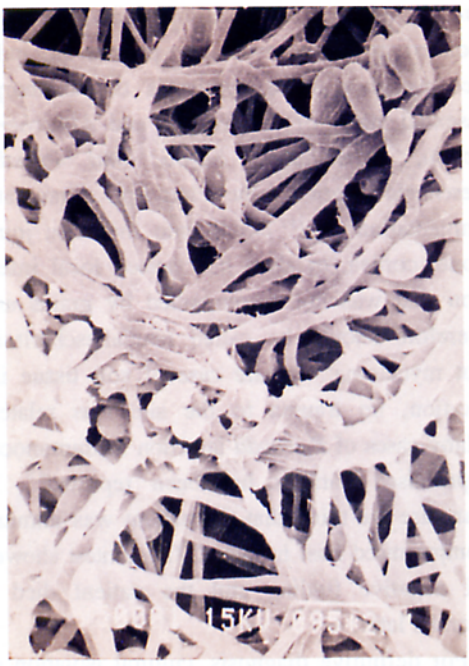

Fig. 7. In scanning electron microscopy of slide culture, conidia and conidiophores of *P. boydii* were seen(×15000).

scopy, conidia and conidiophores of *P. boydii* were seen in slide culture(Fig. 7). The *P. boydii* that was isolated from the lesion had an minimal inhibitory concentration(MIC) of 0.2 μg/mL with miconazole, 0.8 μg/mL with itraconazole and ketoconazole, and 10 μg/mL with amphotericin B, 100 μg/mL with flucytocine, terbinafine and griseofulvin. The lesions improved gradually following oral administration of itraconazole 200mg daily for eight weeks. After eight weeks later, the lesion was slightly improved but the patient was not followed up. The patient died approximately 4 months later because of unknown cause.

DISCUSSION

P. boydii has been associated with cutaneous infection known as mycetoma but occurs very infrequently in extracutaneous sites[1,2,6]. It is in the class of perfect fungi known as Ascomycetes[1]. Disease due to *P. boydii* are reported infrequently. In 1911, Saccardo described a new fungus, *Monosporium apiospermum*, that was isolated from a mycetoma patient in Italy. *Scedosporium apiospermum* is the anamorph (asexual state) of this fungus and *Allescheria boydii, Petriellidium boydii, and Pseudallescheria boydii* are the telomorph[1]. Traumatic implantation of *P. boydii* into the knee joint, bone, cornea, or skull has caused local infection that was not accompanied by grains and therefore should be called peudallescheriasis, not mycetoma[1]. In rare case of soft tissue infec-tion, no trauma to the site was related. Many cases of *P. boydii* infection in immunocompromised patients has been reported[4,5]. In our case we think that the patient was immune compromised host in that CMI multitest showed all negative finding and the patient died 4 months later.

For definitive diagnosis, cultural isolation of the fungus is necessary. This can be by spreading sputum, pus, urine, and biopsy material over the surface of Sabouraud's agar slant with antibacterial antibiotics incubating them at 25° C to 37° C because this fungus is thermally monomorphic fungus[7]. Light brownish-gray colonies that appear cottony to velvety grow out within 1 to 2 weeks. The colonies tend to become lighter in color during maintenance on agar media. Reverse is grey to black. In the asexual state, ovoid or pyriform conidia are produced singly at the tip of conidiophores. Occasionally the conidia occur in small groups. The conidiophores may be lateral or terminal, short or elongate, simple or branched. Tufts of conidiophores may be seen. In the sexual state , spherical thin walled semi-transparent, yellow to brown ascocarps are formed, each containing round or ovoid asci. Many isolates of the fungus produce brown cleistothecia(100 to 200 μm in size) more readily on nutritionally poor media such as corn meal or potato dextrose agar. The formation of cleistothecia is initiated with coiled ascogonia, which develop into mature fruiting bodies within 10 days. The ascocarp wall is composed of single layers of thin, flat, brown polygonal cells. The asci contain 8 ascospores. Isolates that fail to produce cleistothecia are identified as *Scedosporium apiospermum*[1,6,7]. In our case we failed to detect cleistothecia or ascospore by culturing on cornmeal agar.

In tissue dark brown, branching, segmented hyphae and round budding cells were seen. Definitive histopathologic diagnosis is not possible, because there are no specific features that distinguish it from other branching septated fungi. We could detect a ovoid spore in the histiocyte.

Pseudallescheriasis appears to be most responsive to therapy with imidazole, moderate unresponsive to amphotericine B, and completely resistant to flucytosine. Itraconazole has been used successfully to complete a course of therapy[8-14]. The MIC values of this case was consistent with previously reported cases of

peudallescheriasis[9]. The clinical response of our patient to itraconazole was significant. The optimal dose and duration of therapy are unknown but are made according to severity of infection and rate of response.

REFERENCES

1. Kwon-Chung KJ, Bennett JE. *Medical mycology*. 5th ed. Philadelphia. London; Lea & Febiger. 1992; 678-694
2. Travis LB, Roberts GD, Wilson WR. *Clinical significance of Pseudallescheria boydii*. Mayo Clin Proc 1985; 60: 531-537
3. Weber EA, Edberg SC, Singer JM. *Pulmonary infection with Allescheria boydii*. Am J Clin Pathol 1976; 66: 1019-1024
4. Scherr GR, Evans SG, Kiyabu MT, Klatt EC. *Pseudallescheria boydii infection in the acquired immunodeficiency syndrome*. Arch Pathol Lab Med 1992; 116: 535-536
5. Winston DJ, Jordan MC, Rhodes J. *Allescheria boydii infections in the immunosuppressed host*. Am J Med 1977; 63: 830-834
6. Kim SJ, Won YH, Chun IK. *A case of mycetoma due to Pseudallescheria boydii*. Kor J Dermatol 1993; 31(5): 765-768
7. Larone DH. *Medically important fungi. A guide to identification*. 2nd ed. Washinton D.C.; American Society for Microbiology. 1993: 100-101
8. Piper JP, Golden, Brown D, et al. *Successful treatment of Scedosporium apiospermum supprative arthritis with itraconazole*. Pediatr Infect Dis 1990; 9: 674-675
9. Balows A, Hausler WJ, Herrmann KL, Isenberg HD, Shadomy HJ. *Manual of clinical micr-obiology*. 5th ed. Washington D.C.; American Society for Microbiology. 1991: 1178
10. Luwick LI, Galgiani JN, Johnson RH, Stevens DA. *Visceral fungal infection due to Petriellidium boydii(Allescheria boydii)*. Am J Med 1976; 61: 632-639
11. Anderson RL, Carroll TF, Harvey JT, Myers MG. *Petrillidium (Allescheria) boydii orbital and brain abscess treated with intravenous miconazole*. AM J Oph 1984; 97: 771-775
12. Ruxin TA, Steck WD, Helm TN, Bergfeld WF, Bolwell BJ. *Pseudallescheria boydii in a immunocompromized host*. Arch Dermatol 1996; 132: 382-384
13. Restrepo A. *Treatment of tropical mycoses*. J Am Acad Dermatol 1994; 31: S91-S102
14. Lutwick LI, Rytel MW, Yanetz JP, Galgiani JN, Stevens DA. *Deep infections from Petriellidium boydii treated with miconazole*. JAMA 1979; 241: 272-173

=국문초록=

피부 Pseudallescheriasis 1예

고려대학교 의과대학 피부과학교실, 국군광주병원 피부과학교실*

김동준 · 조호연 · 홍승현 · 이길주* · 김일환 · 오칠환

*Pseudallescheria boydii*는 토양과 오염된 물 등에 광범위하게 존재하는 ascomycotina 계통의 eumycota로서 피부에 균종을 발생시키는 흔한 원인균이며 간혹 면역손상환자에서 폐, 부비동, 각막, 뇌, 골수, 심내막 등을 침범할 수 있다

환자는 70세 여자로서 내원 5개월 전부터 양측 전박부와 수부의 배측 부위에 소양감을 동반한 피부병변을 주소로 내원하였다. 환자의 직업은 농부로 과거력 및 가족력상 특이사항은 없었으며 특히 외상의 병력은 없었다. 내원시 시행한 이학적검사상 양측 전박부와 수부의 배측 부위에 삼출성의 홍반성 판과, 다수의 구진, 가피소견이 관찰되었다.

병변에서 시행한 KOH 진균도말검사상 음성소견 보였으나, 피부생검상 상부진피에 미세농양 주위로 주로 림프구, 호중구, 조직구로 구성된 염증세포의 침윤과 포자가 관찰되었다. 병변부 조직에서 시행한 진균 배양검사에서 회백색의 집락이 1주 후에 관찰되었으며 집락을 현미경하에서 관찰한 결과 1개 또는 여러 개의 conidia를 갖는 분리된 conidiophores가 관찰되었고, 병변조직의 전자현미경 검사상 spore 구조가 관찰되었다.

이상의 소견으로 *Pseudallescheria boydii*에 의한 피부감염으로 진단하고 itraconazole 1일 200mg씩 8주간 경구투여하여 피부증상의 호전이 있었으나 4개월 후 사망하였다.