Kor J Med Mycol 4(1), 1999

Cutaneous Infection by *Geotrichum candidum*

Han Gyu Choi, Seong Jun Seo, Chang Kwun Hong and Byung In Ro

Department of Dermatology, College of Medicine, Chung Ang University, Seoul, Korea

INTRODUCTION

Geotrichum(G.) candidum is a common fungus that is rarely pathogenic for man[1], first described by Link in 1809, and according to Dodge[2] this fungus is classified as a subspecies of *Eremnascaeae imperfectae*. This species is largely saprophytic and is usually found in soil, decaying matters, and milk product, although isolation from skin, sputum, and feces of man is not unusual[3,4,5,6]. Geotrichosis, caused by *G. candidum* may occur as an infection of the lung simulating chronic pulmonary tuberculosis or disseminated infection[7]. Very rarely, skin and mucous membrane infection has been documented. These infections usually affect immunocompromised hosts[8,9]. Literature concerning skin or soft tissue infection with this fungus is limited, especially in immunocompetent persons there are only a few reports by this organism. In this paper we report a case of cutaneous geotrichosis involving skin in a healthy woman, in which case steroid and trauma was supposed to play some roles in the pathogenesis.

CASE REPORT

A twenty-one-year-old woman was first seen in Feb. 1998 because of erythema on her left shin, which had been slowly enlarging, accompanied by oozing and mild itching sensation. Seven months ago, she had hurt her left shin by scratching it on a rock while climbing a mountain. A week later, the scratch wound site was spread with scale and oozing. She was treated by application of a topical steroid (Dermovate®) and oral medication of triamcinolone at a drug store. Her skin lesion disappeared with this treatment, but a similar lesion recurred three times on the same site over the next seven months. Each time, she was treated with same medication as above.

The lesion was painless, just slightly itch and there was no associated systemic complaints. A well defined 4x3 cm erythematous scaly oozing patch was detected upon the left shin (Fig. 1). General examination and laboratory tests were all not-contributory. Her hemoglobin, blood, urine data, serologic test for VDRL and chest PA were all within normal limit.

Direct microscopic examination revealed numerous hyphal elements with diverse separation. Branching was not pronounced as is usually observed in dermatophytosis. The scaly material from margin of lesion was inoculated directly on Sabouraud's glucose agar, and incubated at both 37℃ and room temperature. At 37℃, growth ensured slowly over a period of four to five days. The colony was subsurfaced in location and egg white in color with furrows radiating from a central core, and aerial hyphae were absent. It was yeast-like, and soft in texture and easily emulsified. At

Corresponding author: Han Gyu Choi, Department of Dermatology, Chung Ang University, 82-1, 2-ka, Pil-dong, Chung-ku, Seoul 100-272, Korea

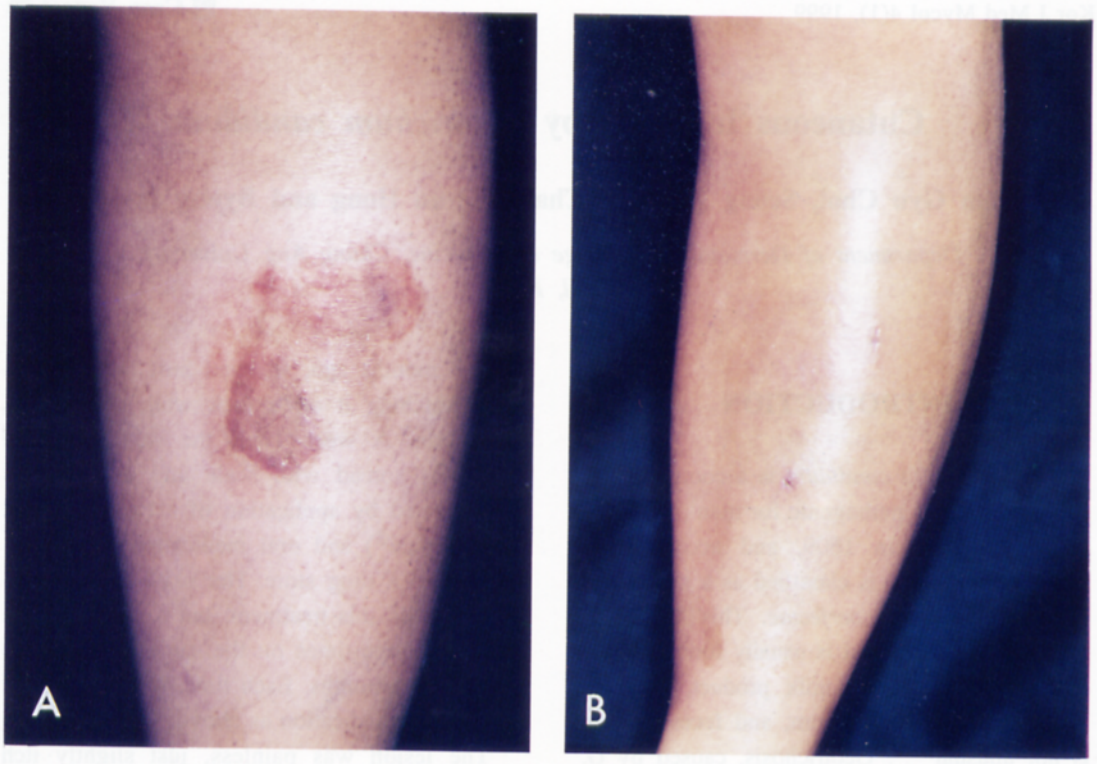

Fig. 1. A: A localized well defined erythematous scaly patch on the left shin, **B:** Clinical improvement after treatment with itraconazole 200 mg/day and isoconazole nitrate cream for 4 weeks.

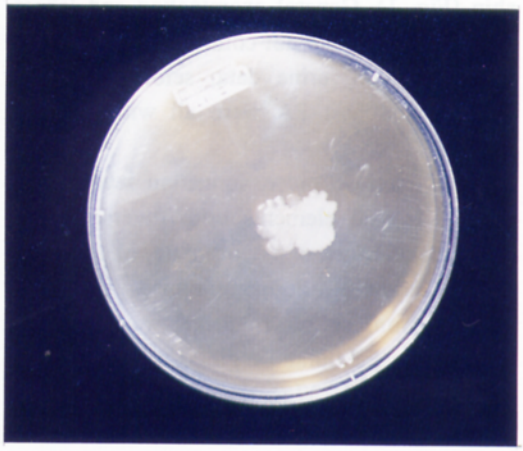

Fig. 2. A rapid growing, egg white, moist, yeast-like colony after 72 hours' inoculation on Sabouraud's glucose agar at room temperature.

room temperature a similar colonial morphology developed within 48 hours (Fig. 2). Blastospores were abscent in subcultures on corn meal agar. Microscopically the colonies were seen to be composed of hyphal elements, which fragmented easily into rectangular and oval cells (Fig. 3). Biochemical study was done with the Vitec-YBC technique. It revealed lack of carbohydrate fermentation and urease activity. Assimilation test was positive in glucose and galactose but not in cellobiose, lactose, maltose, or sucrose.

A 4 mm punch biopsy specimen was taken from the margin of scaly erythema and a part of it was inoculated on Sabouraud's glucose agar. Hyphal elements and spores were observed upon the mild hyperkeratotic stratum corneum. Dermis showed a densely mixed inflammatory infiltrate which was composed of lymphocytes, neutrophils, monocytes and small number of eosinophils (Fig. 4). Whitsh yeast-like colony also cultured from tissue culture after several days at room temperature.

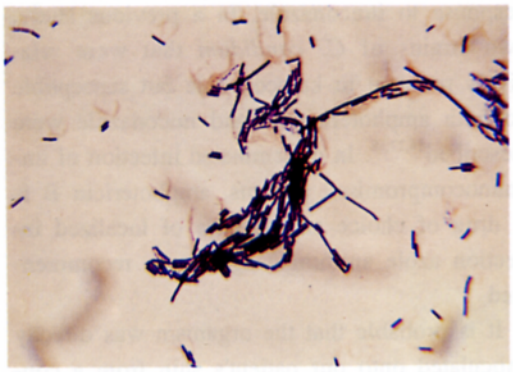

Fig. 3. Easily fragmented hyphal elements, some of which are rectangular or oval shape with rounded ends (periodic acid-Schiff stain, ×400).

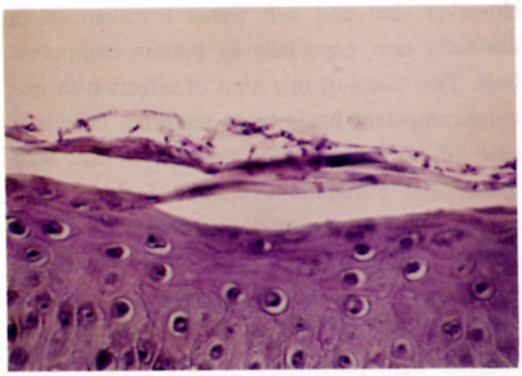

Fig. 4. Hyphae and spores are seen upon the hyperkeratotic stratum corneum (periodic acid-Schiff stain, ×400).

For treatment we started with itraconazole 200 mg per day and 1% isoconazole nitrate cream, and repeated direct microscopic exam and fungal culture on fifth and twelveth day after first visit. Direct examinations showed no fungal elements at all, but similar colonies were cultured repeatedly. Identification of the fungal element as *G. candidum* was based in this patient upon the clinical, repeated cultures, microscopic features and biochemical data. We continued this treatment for six weeks, and the lesion was slowly recovered and completely healed, leaving postinflammatory hyperpigmentation.

DISCUSSION

G. candidum has been recognized as a saprophytic commensal most often involving the lungs in patients with cavitary pulmonary lesions or disseminated infection in immunocompromised hosts such as leukemia or cancer patients receiving chemotherapeutic agents[8,10,11]. It is capable of producing lesions in the mouth, intestinal tract, bronchi, and lungs, also reported to occur on the skin as a pathogen, although some consider the organism to be a saprophyte. The organism has frequently been isolated from the skin, mouth, and intestinal tract of normal persons[11]. It can also be found in the stool in 25 to 40 per cent of normal subjects and has been identified in the stool in patients with a variety of enteritides and colitides but has not generally been thought to be causa[19,13].

The isolation of a species of *Geotrichum* from a clinical lesion, therefore, would not be tantamount to a diagnosis of geotrichosis. However, the finding of rectangular and oblong cells with square or round ends from smeared or biopied materials is diagnostic if cultures are obtained which appear yeast-like and form arthrospores by segmentation of the hyphae[14]. We believe that the isolation of the organism on repeated cultures, the identification in tissue by histologic means, and the clinical picture support the diagnosis in this case. This organism is distinguished from *Trichosporon* by not producing urease and it differs from *Blastoschizomyces capitatus* by its assimilation of D-xylose. In general, *Geotrichum* is distinguished from the majority of arthroconidial filamentous fungi by its creamy or waxy, rather than wooly colonies, more specifically, it differs from *Malbranchea* and *Coccidioides* by the absence of disjunctors between the arthroconidia.

The usual pulmonary or disseminated form of this infection in immunocompromised patients has been reported not-uncommonly[8,9].

However skin and soft tissue involvement is distinctly rare, especially in immunocompetent host. Two cases of this kind of infection in immunocompetent hosts were reported. One is a case of soft tissue infection of thumb web space after traumatic avulsion of skin[14]. The other case is a traumatic joint infection after splinter injury of right third metacarpophalangeal joint[15]. These two cases share common features in several points with this case. The patients were previously healthy persons with no immunodeficient or immunosuppressed state, and before the occurrence of disease, they experienced trauma upon the site of lesions. Our patient experienced a traumatic abrasion injury before the onset of the lesion and received an oral and potent topical steroid, which is supposed to act a certain role in the pathogenesis.

Histopathologically fungal hyphae were observed on skin specimen, and culture on Sabouraud's glucose agar at room temperature revealed a white, moist, yeast-like, and easily picked up colony. Microscopically, we could find segmented rectangular or oval shaped arthroconidia, which are typical findings for *G. candidum*. No blastoconidia along the hyphae were observed. Furthermore, biochemical data revealed negative urease activity, lack of carbohydrate fermentation and assimilation of glucose and galactose but not cellobiose, lactose, maltose nor sucrose. Based upon the clinical, repeated cultural, microscopic and biochemical data, we concluded that this unusual fungal infection in this patient was caused by *G. candidum*.

We treated her with 200 mg of itraconazole per day and 1% isoconazole nitrate cream for four weeks. Initially clinical response was slow, however, eventually completely healed clinically and mycologically. For prevention of recurrence, we continued this treatment for another two weeks. Since the relationship of *in vitro* study results to clinical outcome is not yet established, the antifungal susceptibility of *G. candidum* may not be relevant to our patient's response to itraconazole. In a previous study, two strains of *C. candidum* that were relatively resistant to ketoconazole but susceptible to both amphotericin B and miconazole were described[16,17,18]. In disseminated infection of immunocompromised patients, amphotericin B is a drug of choice and in case of localized infection azole antifungal agents are recommended.

It is probable that the organism was directly inoculated onto our patient's shin from a contaminated rock at that time of abrasion injury while climbing. Topical and oral steroid with which she was treated at the drug store is supposed to play a role by altering her immunity locally or systemically. Herein, we have described a case of cutaneous infection by *G. candidum* on left shin after an abrasion injury in a woman.

REFERENCES

1. Chang W, Buerger L. Disseminated geotrichosis. Arch Int Med 1964; 113: 356-360
2. Dodge CW. Fungous diseases of men and animals. Mycology 1935; 196: 215-217
3. Schnoor FG. The occurrence of monilia in normal stools. Am J Trop Med 1939; 19: 163-169
4. Swartz JH, Jankelson IR. Incidence of fungi in the stools of non-specific ulcerative colitis. Am J Dig Dis 1941; 8: 211-214
5. Felsenfeld O. Yeast-like fungi in the intestinal tract of chronically institutionalized patients. Am J Med Sci 1944; 207: 60-63
6. Buslau M, Ingrid M, Lolzmann H. Fungal flora of human faeces in psoriasis and atopic dermatitis. Fungus 1990; 33: 90-94
7. Zinsser, Hans. Microbiology. 12th ed. New York: ACC, 1960: 849
8. Anaissie E, Bodey GP, Kantarjian J. New specimen of fungal infections in patients with cancer. Rev Infect Kis 1989; 11: 369-378
9. Kassamali H, Anaissie E, Ro J. Disseminated geotrichum infection. J Clin Microbiol 1987; 25: 1782-1783

10. Ghamande AR, Landis FB, Snider GL. Bronchial geotrichosis with funemia complicating bronchial carcinoma. Chest 1971; 59: 98-101
11. Sheehy TW, Honeycutt BK, Spency JT. Geotrichum septicemia. JAMA 1976; 235: 1035-1037
12. Listemann H, Schonrock P, Kuse R, Meigel W. Geotrichosis of oral mucosa. Mycoses 1996; 39: 289-291
13. Jagirdar J, Geller S, Bottone E. *Geotichum candidum* as a tissue invasive human pathogen. Hum Patho 1981; 12: 668-671
14. Goldman S, Lipscomb PR, Ulrich JA. Geotrichum tumefaction of the hand. J Bone Joint Surg Am 1969; 587-590
15. Daniel B Hardy. Traumatic joint infection due to *Geotrichum candidum*. Clin Infec Dis 1995; 20: 468-469
16. Rex JH, Pfaller MA, Rianaldi MG, Polak A, Galgiani JN. Antifungal susceptibility test. Clin Microbiol Rev 1993; 6: 367-381
17. Rex JH, Vangkal M. In vivo activity of antifungal agents against yeast species. Chemotherapy 1983; 29: 104-110
18. Galgiani J. Susceptibility testing of fungi: current status of the standardization process. Antimicrob Agents Chemother 1993; 37: 2517-2521

=국문초록=

*Geotrichum candidum*에 의한 표재성 진균증 1예

중앙대학교 의과대학 피부과학교실

최한규 · 서성준 · 홍창권 · 노병인

*Geotrichum candidum*은 세계적으로 분포하는 효모균으로 토양과 분변 등에서 발견되고 드물게 면역이 감소된 환자에서 폐감염, 아구창, 설사 등을 일으키는 것으로 알려져 있다. 분절포자 (arthroconidia)를 형성하는 것을 특징으로 하며, 형태학적으로 *Coccidioides immitis, Trichosporon beigelii, Blastoschizomyces capitatus*와 매우 유사하여 감별을 요한다.

환자는 20세 여자로 내원 7개월 전 등산 중 바위에 의하여 찰과상을 받은 일주일 후 발생한 좌측 전경골부의 삼출을 동반한 소양성 인설성 홍반을 주소로 내원 하였다. 병변부에서 시행한 KOH 도말 검사상 균사가 반복적으로 관찰되었고 인설과 생검조직을 각각 Sabouroud 포도당 한천배지에 배양한 결과 집락은 비교적 빨리 자라며, 중앙부는 분말형을 보이고 가장자리는 젖빛유리 모양을 나타내었다. 배양한 균집락을 lactophenol cotton blue로 염색후 광학현미경 관찰상 진성 균사와 난형 또는 사방형의 분절포자가 관찰되었으나 분절포자에서 발아하는 분아포자 (blastospore)는 관찰되지 않았다. 균주는 37℃ 배양에서 실온보다 느리게 집락을 형성하였으며, Vitek YBC검사상 urease 음성, 탄수화물 동화검사는 glucose와 galactose에 양성을 보였다. 조직생검에서 각질층에 균사와 포자가 관찰되었고 진피층의 혈관주위에 호중구 침윤과 핵진이 관찰되었으며, 혈관벽내의 섬유소양 괴사가 관찰되었다. 이상의 임상과 조직소견, 균의 형태학적, 생화학적 검사로 *Geotrichum candidum*에 의한 표재성 진균증으로 동정하였다.

치료로 itraconazole 일일 200 mg 경구 투여와 isoconazole nitrate 1% cream 국소 도포를 병합하여 치료 하였다. 병변은 치료에 느리게 반응하여, 2주후 균은 음전되었으며 4주후 약간의 색소 침착을 남기고 소실되었으며 현재 재발 없이 추적 관찰 중이다. **[Kor J Med Mycol 4(1): 69-74]**

색인단어: *Geotrichum candidum*, 피부감염 (skin infection)