Kor J Med Mycol 5(1), 2000

■ Invited Article ■

# Penicilliosis in AIDS

**Preya Kullavanijaya and Rataporn Ungpakorn**

*Institute of Dermatology, Bangkok, Thailand.*

**=Abstract=**

Nowaday, the increasing incidence of immunocompromised conditions, especially HIV infections have brough about more opportunistic infections including bacterial, virus and fungus. Some of them rarely occurred previously while some were the problem in endemic areas. *Penicillium marneffei* is a thermally dimorphic fungus that is thought to be endemic to southeast Asia and southern China[1,2]. It is capable of causing life-threatening disseminated illness, involving the skin, bone marrow, liver, lymph nodes, bones and lungs in immunocompromised[3] and immunocompetent persons[2,4]. Despite the prevalence in the southeast Asia among AIDS patients, there have been only few reports in dermatology literature. **[Kor J Med Mycol 5(1): 1-6]**

**Key Words:** *Penicilliosis, Penicillium marneffei*, HIV, AIDS

## HISTORY

*Penicillium marneffei* was first isolated in 1956 and identified in 1959 from a bamboo rat (*Rhizomys sinensis*) found in the highlands of central Vietnam[5]. The first accidental human infection was reported in 1959 by Segretain.[6] However, the first natural infection in human appeared in 1973 in a patient who underwent splenectomy for Hodgkin's disease[7]. Subsequently, there have been numerous reports of disseminated infection, mostly in immunocompromised persons. The majority of the reported infections have occurred in patients from southeast Asia or southern China. Recently, there have been reports of *Penicillium marneffei* endemic among AIDS patients from northern Thailand[8]. Unpublished data revealed that there may be as many as 1,000 cases diagnosed and treated in the last 6 years. Among cases reported from the U.K., France, Italy, the Netherlands, U.S.A. and Australia, had history of traveling to the endemic area.

## EPIDEMIOLOGY AND PATHOGENESIS

*Penicillium marneffei* appears to be endemic to southeast Asia, southern China, and Hong Kong with sporadic cases found in the south of Asia continent. The ecological niche and the mode of transmission is still a controversy. The organism had been isolated from the internal organs (lungs, liver, spleen, and mesenteric lymph nodes) of two bamboo rat species (*Rhizomys sinensis* and *R. pruinosus*) and recently, in *R. sumatrensis* and *Cannomys badius* (bay bamboo rat) indicating that bamboo rats may be a reservoir for *P. marneffei*[5,10]. It is skeptical that man may become infected by eating infected rats, by inhaling or accidentally ingesting fungi that have been dispersed to the environment. *P. marneffei* has been recovered from the soil of bamboo rat burrows[5] while in some studies showed no significant findings[10]. Bamboo rats and humans may acquire the infection from a common source, such as con-

Corresponding author: Preya Kullavanijaya, Institute of Dermatology, 420/7 Rajvithi Rd., Phyathai, Bangkok 10400, Thailand

taminated sugar cane or bamboos which bamboo rats feed on. However, *P. marneffei* has not been isolated from these sources in the field[10]. At present, there is no evidence to the direct mode of transmission between man and bamboo rats. However, evidence of seasonal variation of penicilliosis in northern Thailand with an increase in incidence during the rainy season suggested possible airborne transmission through inhalation during favourable condition for growth of the fungus in optimum environmental reservoir. Air sample culture from the endemic area had not shown significant results. It is speculated that perhaps a few conidia may be sufficient to cause the disease in susceptible persons[10].

*P. marneffei* is the only dimorphic *Penicillium spp.* The pathogenic potential may be due to its thermal dimorphism and the ability to proliferate within macrophages, therefore, effectively shielding the organisms from the host's cellular immune response[4]. Experimental infection showed it to be highly pathogenic for hamsters, mice and rats with dissemination to the reticuloendothelial system similar to *Histoplasma capsulatum*[6].

## CLINICAL SPECTRUM

The first report of possible local infection in human was established in 1959[6]. Early cases had been reported in patients with underlying diseases or immunosuppressive therapies. Clinical manifestations were similar among AIDS and non-AIDS patients[8,11,12]. The onset of infection may be acute, but more often patients experience several weeks to months of intermittent fever, headache, malaise, and weight loss. Fever was the most frequent sign of disseminated infection present in 95% of the patients with marked weight loss and anemia in more than 75% of the cases[8]. Lymphadenopathy, hepatomegaly and pulmonary abnormalities (cough, dyspnea, pleural diffusion, infiltrates on chest roentgenogram) were also common manifestations. Less common presentations included leukopenia, thrombocytopenia, splenomegaly, bone involvement, pericarditis or pericardial effusion, and gastrointestinal symptoms. However, in the AIDS group the clinical presentations were more acute and intense with a higher incidence of septicemia and an increase frequency of oropharyngeal and mucous membrane involvement[12]. Absence of osteoarticular lesions were also noted. In endemic areas, the presence of fever with unexplained increase in alkaline phosphatase enzyme level was not an uncommon presentation for penicilliosis in AIDS patients. Common clinical manifestations are listed in Table 1.

Cutaneous manifestations occurred frequently and may be the initial presenting sign in HIV patients. Abscesses were common in non-HIV patients while cutaneous presentations were more diversified among HIV patients[1,2,4]. Papules, pustules, nodules, vesicles, acneiform, maculopapular eruption and mucocutaneous lesions had been reported. Skin lesions appeared mainly on the upper half of the body, 70% being on the face, scalp, upper extremities and trunk. Umbilicated papules (molluscum contagiosum-like) with or without central necrosis (Fig. 1) were seen in almost 90% of AIDS patients[8,14]. These lesions when present were characteristic but could also be seen in a few other opportunistic fungal infections, namely histoplasmosis and cryptococcosis. The presence of the skin lesions usually suggested dissemination at the time of diagnosis.

**Table 1.** Common clinical manifestations of *P. marneffei* infection

| |
|---|
| Anemia |
| Weight loss |
| Skin lesions |
| Lymphadenopathy |
| Hepatomegaly |
| Splenomegaly |
| Jaundice |
| Genital ulcers |

**Fig. 1.** Molluscum contagiosum-like papules in disseminated penicilliosis.

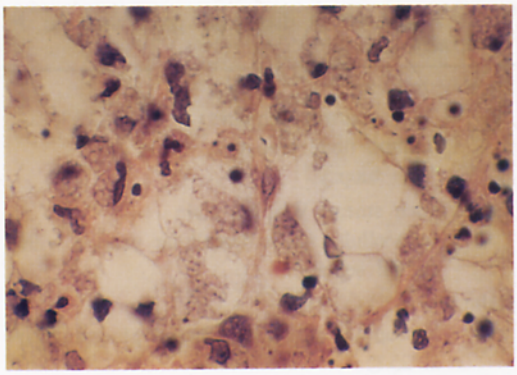

**Fig. 2.** A direct touch smear from tissue specimen stained with Wright's stain showing intracellular and extracellular basophilic, yeast-like organisms with clear central septation.

There had been more than 20 reported cases of disseminated penicilliosis in children from vertical transmission[15]. All infected children were symptomatic AIDS with the appearance of similar manifestations as seen in adults by the age of 2 years although the presentation of papular lesions resembling insect bite reaction was less common. Severe anemia, thrombocytopenia and osteomyelitis seemed to be more common in children than in symptomatic adults but whether they were of any importance as diagnostic clues had to be further evaluated.

## DIAGNOSIS

Penicilliosis is a treatable disease but delay in treatment may be fatal with almost a 100% mortality rate in both AIDS and non-AIDS patients[8,12]. Recently, there have been more than 1,000 cases diagnosed and treated among AIDS patients in northern Thailand just in the past 6 years (1991-1996, unpu-blished data). Clinical manifestations may mimic other opportunistic infections, therefore, clinical suspicion and early diagnosis are essential for prompt treatment and prognosis.

A quick and convenient diagnostic procedure is by performing a direct touch smear and Wright's staining from tissue specimens. Intracellular and extracellular basophilic, spherical yeast-like organisms (3-8 μm) with clear central septation is characteristic (Fig 2)[16]. Tissue histological examination may be helpful. The most reliable procedure for isolation of *P. marneffei* with a 100% sensitivity is to culture from bone marrow aspirates or lymph node biopsies. At 25℃ in Sabouraud's glucose agar, the mycelial saprophytic phase is characterized by the colony with a flat-down, bluish-gray-green center and white periphery. The reverse colony develops a brick-red color with diffusion of the pigments into the agar in as early as 24-48 hours. At 37℃, *in vivo* and *in vitro* (blood agar), the morphology of the yeast-like parasitic form is characterized by round, oval or elongated yeasts with planate or central septation. Rarely, short filaments may be visible. Laboratory diagnostic procedures are summarized in Table 2.

Immunohistochemical assays using a monoclonal antibody (EBA-1) directed against an external wall epitope shared by *P. marneffei* and *Aspergillus* species may be an alternative method of tissue diagnosis[16]. Other monoclonal antibodies are being developed for early diagnosis.

## MANAGEMENT

The first successful treatment of focal penicilliosis with 20 million units of oral nystatin

**Table 2.** Laboratory diagnostic procedures for *P. marneffei* infection

| |
|---|
| Specimens: |
| • Bone marrow aspirates |
| • Lymph node biopsy |
| • Skin biopsy |
| Direct touch smear: Wright's stain |
| • Intracellular and extracellular yeastes with central septation |
| Culture: |
| • Saprophytic form: Sabouraud glucose agar at 25℃ |
| • Parasitic form: Brain heart infusion agar at 37℃ |
| Histopathology: |
| • Granulomatous abscess with demonstration of *P. marneffei organisms* |
| Serologycal diagnosis: pending |

(13 times the usual daily dose) for 30 days was reported in 1959[6]. Since then there had been sporadic reports of systemic treatment of systemic penicilliosis[18~20]. Only recently there had been *in vivo* and *in vitro* susceptibility studies and treatment reports with various systemic antifungals. Most of the cases were prevalent among AIDS population in the endemic area. Table 3 shows the list of medical treatment for penicilliosis.

Amphotericin B (AMB) remains the drug of choice for many forms of deep and systemic fungal infection by inhibiting fungal ergosterol cell wall synthesis. An initial test dose of 1 mg AMB in dextrose solution (0.5 mg in children less than 30 kgs) should be given over 1~2 hours with general observation. If the test dose is well tolerated, progression to larger doses may be given. In adults with normal renal function the usual dose of 0.3~1.0 mg/kg may be given in 4~6 hours. Most patients with systemic fungal infection are treated with 1~2 g of AMB over 6~8 weeks, but this will differ from case to case. AMB is indicated for severe cases of penicilliosis[19]. Renal tubular damage is the most serious toxic effect of AMB and should be used with pre-

**Table 3.** Medical treatment for *P. marneffei* infection

| |
|---|
| Amphotericin B |
| Itraconazole |
| Ketoconazole |
| Fluconazole |
| Flucytosine |
| Alone or in combination |

caution when administering with other nephrotoxic and antineoplastic drugs.

Itraconazole is used as an initial treatment for mild to moderately severe penicilliosis given at 400 mg for 8~12 weeks[18,19,20]. Negative blood culture conversion within 24~90 days (mean 57 days) were seen in 75% with 62.5% relapse after 4 months cessation of therapy. However, 36.4% responded to fluconazole 400 mg in 2 divided doses for 8 weeks.

It is entirely the judgement of the physicians as to the choice of drugs to use depending on the clinical severity. AMB 0.3~0.6 mg/kg daily was given as a standard regimen for seriously-ill patients for 6~8 weeks for a total accumulation dose of 40 mg/kg[19]. Seventy-eight percent of the patients treated responded favourably after 2 weeks. Relapses occurred in 17.6% within 6 months after cessation of therapy. Twenty-two percent showed no response[19].

An open-label nonrandomized study was conducted to evaluate the efficacy and safety of treatment with AMB 0.6 mg/kg/d intravenously for 2 weeks followed by a 400 mg/d oral itraconazole for another 10 weeks[22]. Of the 74 HIV with disseminated penicilliosis patients, 97.3% (72 of 74) responded to treatment. Fungemia was cleared by the end of the 2nd week with disappearance of fever and skin lesions by the end of the 4th week. No patients required any adjustment in the drugs because of the occurrence of laboratory abnormalities or adverse events. However, 57% of the patients had relapses with the median time of 24 weeks after completion of initial treatment and none of the patients who re-

ceived 200 mg/d itraconazole for secondary prophylaxis had relapses[23] It is recommended, therefore, that secondary prophylaxis with itraconazole be given for life in penicilliosis patients who have responded to initial treatment. The role of ketoconazole as a prophylactic drug is still under trial.

## CONCLUSION

Penicilliosis, previously a rare disease has now emerged as one of the most common systemic opportunistic infection among AIDS patients in southeast Asia. Physicians should be aware in the presence of characteristic cutaneous lesions with systemic involvement in AIDS patients who lived in or visited areas in which this fungus is endemic regardless the time since exposure. Direct smear or touch smear with Wright's stain of the cutaneous lesions or lymph node specimens are quick and convenient diagnostic procedures. Management with systemic antifungals (amphotericin B, itraconazole, fluconazole or ketoconazole) must be promptly initiated according to clinical severity awaiting confirmation by characteristic culture morphology identification. Present epidemiological data suggest that disseminated penicilliosis should be included as an AIDS-defining condition like other opportunistic systemic mycoses, such as histoplasmosis, coccidioidomycosis and cryptococcosis[8,21]. Penicilliosis is a fatal disease unless prompt diagnosis and early treatment with systemic antifungal is initiated.

## REFERENCES


1. Jayanetra P, .Nitiyanant P, Ajello L, et al. *Penicilliosis marneffei* in Thailand: report of five human cases. Am J Trop Med Hyg 1984; 33: 637-644
2. Deng Z, Ribas JL, Gibson DW, Connor DH. Infections caused by *Penicillium marneffei* in China and southeast Asia: Review of eighteen published cases and report of four more cases. Rev Infect Dis 1988; 10: 640-652
3. Supparatpinyo K, Chiewchanvit S, Hirunsri P, et al. *Penicillium marneffei* infection in patients infected with human immunodeficiency virus. Clin Infect Dis 1992; 14: 871-874
4. Deng Z, Connor DH. Progressive disseminated penicilliosis caused by *Penicillium marneffei*: report of eight cases and differentiation of the causative organism from *Histoplasma capsulatum*. Am J Clin Pathol 1985; 84: 323-327
5. Deng Z, Yun M, Ajello L. Human penicilliosis marneffei and its relation to the bamboo rat (*Rhizomys pruinosus*). J Med Vet Mycol 1986; 24: 383-389
6. Segretain G. *Penicillium marneffei* N. Sp., agent d'une mycose du systeme reticuloendothelial. Mycopathol Mycol Appl 1959; 11: 327-353
7. Disalvo AF, Fickling AM, Ajello L. Infection caused by *Penicillium marneffei*: description of first natural infection in man. Am J Clin Pathol 1973; 60: 259-263
8. Supparatpinyo K, Kwamwan C, Baosoung V, Disseminated *Penicillium marneffei* infection in southeast Asia. Lancet 1994; 344: 110-113
9. Chariyalertsak S et al., Seasonal variation of disseminated *Penicillium marneffei* infection in northern Thailand. J Inf Dis 1996; 173: 1490-3
10. Chariyalertsak S, Vanitanakom P, Nelson KE et al.*Rhizomys sumatrensis* and *Cannomys badius*, new natural animal hosts of *Penicillium marneffei*. J Med Vet Mycol 1996
11. Li JS, Pan LQ, Wu SS, Su SX, Su SB, Shan LY. Disseminated penicilliosis marneffei in China. Report of three cases. Chin Med J 1991; 104: 247-51
12. Drouhet. Penicilliosis due to *Penicillium marneffei*: A new emerging systemic mycosis in AIDS patients traveling or living in southeast Asia. J Mycol Med 1993; 4: 195-224
13. Wortman *P. Infection* with *Penicillium marneffei*. Int J Dermatol 1996; 35; 393-99
14. Chiewchanvit S, Mahanupab P, Hirunsri P, Vanittanakom N. Cutaneous manifestations of disseminated *Penicllium marneffei* mycosis in five

HIV-infected patients. Mycoses 1991; 34: 245-249

15. Sirisanthana V, Sirisanthana T, *Penicillium marneffei* infection in children infected with human immunodeficiency virus. Pedriatr Infect Dis 1993; 12: 1021-25
16. Supparatpinyo K, Sirisanthana T. Infection diagnosed on examination of a peripheral blood smear of a patient with human immunodeficiency virus infection. Clin Inf Dis 1994; 18: 246-7
17. Sekhon AS, Li JSK, Garg AK. *Penicilliosis marneffei*: serological and exoantigen studies. Mycopathologia 1982; 77: 51-7
18. Sekhon AS, Padhye AA, Garg AK, Hamir Z. In vitro susceptibility of mycelial and yeast forms of *Penicillium marneffei* to amphotericn B, fluconazole, 5-fluorocytosine and itraconazole In: Fungal dimorphism. 4th Symposium on topics in Mycology. University of Cambridge, UK, September 1-4, 1992; Abstract. p. 41, p. 248
19. Supparatpinyo K, Nelson KE, Merz WG. Response to antifungal therapy by HIV-infection and *in vitro* susceptibilities of isolates from clinical specimens. Antimicrob. Agent Chemother. 1993; 37: 2407-2411
20. Supparatpinyo K, Hirunsri P, Uthammachai C. An efficacy study of itraconazole in the treatment of *Penicillium marneffei* infection. J Med Assoc Thai 1992; 75: 688-691
21. Sathapatayavongs B, Damrongkitchaiporn S, Saengditha P, Kiatboonsri S, Jayanetra P. Disseminated penicilliosis associated with HIV infection (Letter). J Infect 1989; 19: 84-85
22. Sirisanthana T, Supparatpinyo K, Perriens J, Nelson KE. Amphotericin B and itraconazole for treatment of disseminated *Penicillium marneffei* infection in human immunodeficiency virus-infected patients. Clin Infect Dis 1998; 26: 1107-1110
23. Supparatpinyo K, Perriens J, Nelson KE, Sirisanthana T. A controlled trial of itraconazole to prevent relapse of *Penicillium marneffei* infection in patients infected with the human immunodeficiency virus. N Eng J Med 1998; 339: 1739-1743