IMAGES IN MYCOLOGY

J Mycol Infect 2020; 25(1): 26-27
pISSN:1226-4709, eISSN:2465-8278
http://dx.doi.org/10.17966/JMI.2020.25.1.26

JMI

Clinical and Histological Findings of Kerion Celsi

Jeongsoo Lee, Nuri Na and Joonsoo Park†

Department of Dermatology, School of Medicine, Catholic University of Daegu, Daegu, Korea

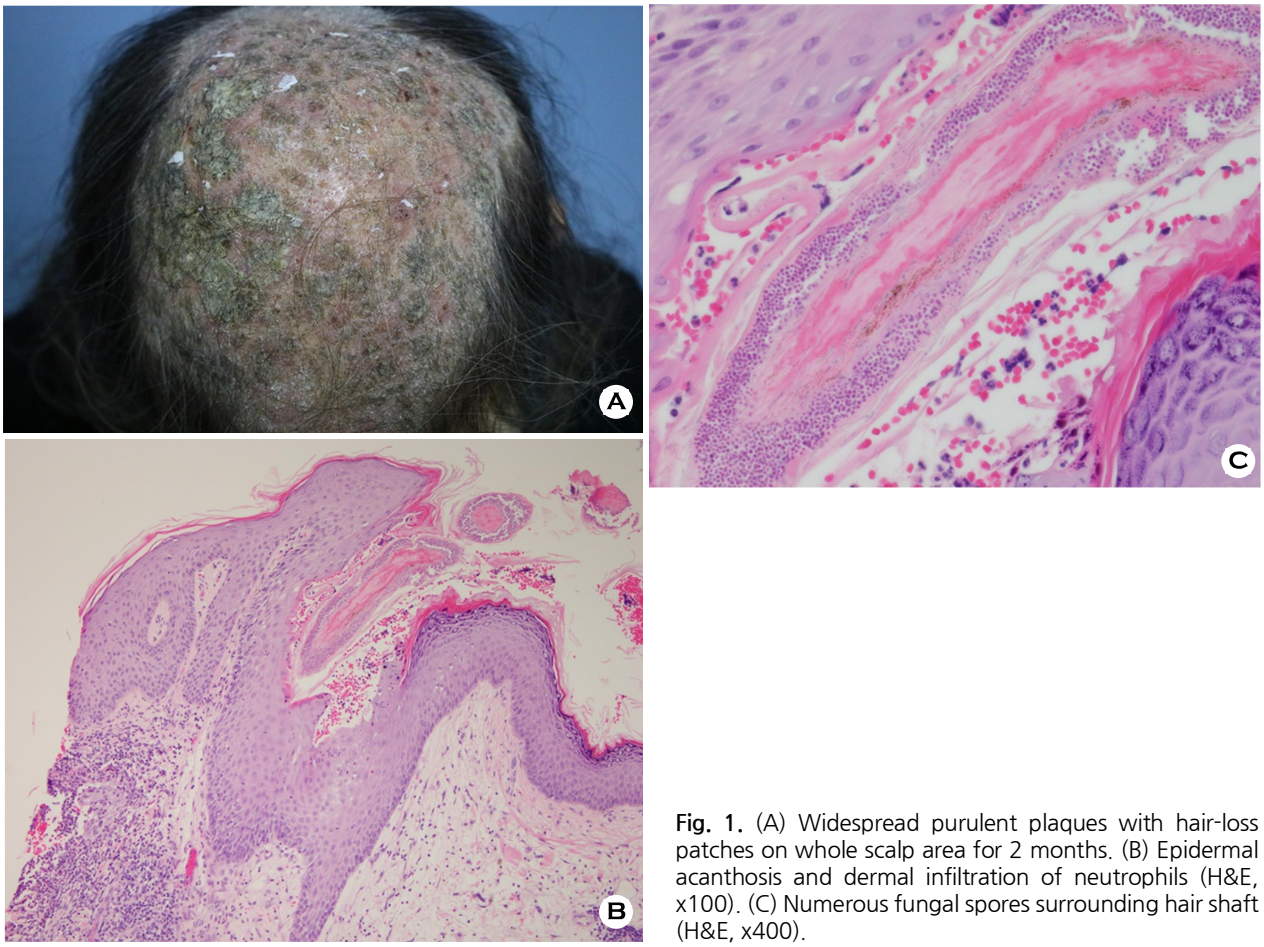

Fig. 1. (A) Widespread purulent plaques with hair-loss patches on whole scalp area for 2 months. (B) Epidermal acanthosis and dermal infiltration of neutrophils (H&E, x100). (C) Numerous fungal spores surrounding hair shaft (H&E, x400).

Tinea capitis is a scalp infection caused by dermatophytes, primarily *Trichophyton* and *Microsporum* spp.[1] Kerion celsi is a severe, boggy inflammatory form of tinea capitis. Deep, tender, and boggy plaques with pus are known clinical fea-

Received: February 17, 2020 Revised: March 10, 2020 Accepted: March 12, 2020
†Corresponding: Joonsoo Park, Department of Dermatology, School of Medicine, Catholic University of Daegu, 33 Duryugongwon-ro 17-gil, Nam-gu, Daegu, 42472, Korea.
Phone: +82-10-6802-1023, Fax: +82-53-650-4891, e-mail: magincia@cu.ac.kr
Copyright@2020 by The Korean Society for Medical Mycology. All right reserved.
This is an open-access article distributed under the terms of the Creative Commons Attribution Non-Commercial License (http://creativecommons.org/licenses/by-nc/3.0/), which permits unrestricted non-commercial use, distribution, and reproduction in any medium, provided the original work is properly cited. http://www.ksmm.org

Copyright@2020 by The Korean Society for Medical Mycology

tures of kerion celsi[2]. The patient may develop single or multiple round-shaped patches of hair loss with scarring in the areas of inflammation and suppuration (Fig. 1A).

Kerion celsi is commonly confused with bacterial abscess because of purulent drainage. It must be clinically differentiated from chronic staphylococcal folliculitis, pediculosis capitis, psoriasis, seborrheic dermatitis, and various inflammatory follicular conditions[2].

Histologically well-established lesions of kerion celsi show foci of parakeratosis with epidermal acanthosis and spongiosis. In the dermal and perifollicular area, severe inflammatory tissue reactions can be observed, such as neutrophil infiltration (Fig. 1B). Numerous fungal spores surrounding the hair shaft and follicle represent a distinct specific histological feature in kerion celsi (Fig. 1C).

Fungal culture is the gold standard method to confirm the fungal infection. However, patients with kerion celsi show a high rate of false-negative results with conventional culture methods, chiefly because the samples contain inflammatory cells without fungal cells[1]. Histological analysis is a successful alternative method in culture-negative patients for identifying fungus without special stains, such as periodic acid-Schiff and Grocott's methenamine silver.

Key Words: Kerion celsi, Tinea capitis

CONFLICT OF INTEREST

In relation to this article, we declare that there is no conflict of interest.

ORCID

Jeongsoo Lee: 0000-0001-6688-584X
Nuri Na: 0000-0001-8988-9632
Joonsoo Park: 0000-0003-1354-2311

PATIENT CONSENT STATEMENT

The patient provided written informed consent for the publication and the use of his or her images.

REFERENCES

1. John AM, Schwartz RA, Janniger CK. The kerion: an angry tinea capitis. Int J Dermatol. 2018;57:3-9
2. James WD, Berger TG, Elston DM. Andrews' diseases of the skin. 12th ed. Philadelphia: Elsevier, 2015:286-294