CASE REPORT
J Mycol Infect 2019; 24(1): 28-31
pISSN:1226-4709, eISSN:2465-8278
http://dx.doi.org/10.17966/JMI.2019.24.1.28

JMI

Disseminated Cryptococcosis Incorrectly Managed: a Case Report

Adil Maleb[1†], Aziza Hami[2], Yassine Ben Lahlou[3], Somiya Lamrabat[1], Safaa Rifai[1], Nawal Rahmani[1], Mohammed Bensalah[1], Mohammed Frikh[3], Abdelhay Lemnouer[3] and Mostafa Elouennass[3]

[1]Laboratory of Microbiology, Mohammed VI University Hospital / Faculty of Medicine and Pharmacy (University Mohammed the first), Oujda, Morocco
[2]Department of Medical Analysis Laboratory, Jerada Provincial Hospital Center, Jerada, Morocco
[3]Department of Bacteriology, Mohammed V Military Teaching Hospital / Faculty of Medicine and Pharmacy (University Mohammed V), Rabat, Morocco

Disseminated cryptococcosis is a rare fungal infection, which mainly occurs in immunocompromised patients, and the diagnosis is difficult. Therefore, it is less likely to be considered in immunocompetent patients. Here, we present a case of fatal cryptococcal infection of the pleural fluid and ascites in a patient seronegative for HIV. The patient was a 45-year old man who was followed for Crohn's disease and treated with steroids and an immunosuppressant (azathioprine). The culture of pleural and ascites fluids showed the presence of yeasts colonies identified as *Cryptococcus neoformans*. Bacteriological examination of the blood culture or cerebrospinal fluid (CSF) was not prescribed. The HIV serology was negative. At the fourth day of treatment, the patient died because of the deterioration of neurological and hepatocellular functions. The main diagnostic problems that led to this fatal outcome were non-suspicion of an at-risk patient, lack of microbiological analysis of the blood or CSF, and inadequate antifungal therapy.

Key Words: Ascites, *Cryptococcus neoformans*, Pleura

INTRODUCTION

Disseminated cryptococcosis is a rare fungal infection caused by a capsulated yeast of the *Cryptococcus* genus, which mainly occurs in immunocompromised patients, and is fatal[1]. Thus, it is easily considered, and the diagnosis is relatively easy in these patients. However, in immunocompetent patients, the diagnosis is more difficult. Therefore, it is less likely to be considered, which can lead to delays in therapy initiation, directly influencing the prognosis[2]. We present a case of fatal cryptococcal infection of the pleural fluid and ascites in a patient seronegative for HIV, followed for Crohn's disease. The objective of this case study is to demonstrate the main pitfalls of clinical and microbiological diagnosis that darken the prognosis of this infection.

CASE REPORT

A 45-year old man was followed for Crohn's disease, with

Received: November 28, 2018 Revised: January 3, 2019 Accepted: February 14, 2019
†Corresponding: Adil Maleb, Laboratory of Microbiology, Mohammed VI University Hospital, Faculty of Medicine and Pharmacy, University Mohammed the first, P.O. Box N° 4806, Oujda, Morocco.
Phone: +212-671-1414-71, Fax: +212536533800, e-mail: maleb.adil@gmail.com
Copyright@2019 by The Korean Society for Medical Mycology. All right reserved.
This is an open-access article distributed under the terms of the Creative Commons Attribution Non-Commercial License (http://creativecommons.org/licenses/by-nc/3.0/), which permits unrestricted non-commercial use, distribution, and reproduction in any medium, provided the original work is properly cited. http://www.ksmm.org

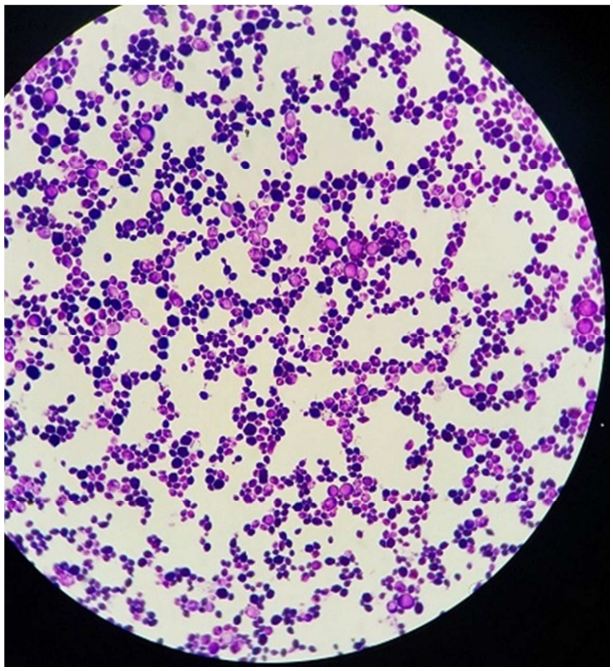

Fig. 1. Microscopic examination after Gram staining showing budding yeasts (1,000X).

the complications of splenic thrombosis and duodeno-jejunal stenosis. The patient was treated with steroids and then with an immunosuppressant (azathioprine). The patient was hospitalized for shock and diagnosed with hypovolemic shock state on diarrhea, with the abundance of ascites. The clinical examination revealed a conscious patient of 55 kg, feverish (38℃), having an arterial tension of 75/35 mm Hg, heart rate of 112/min, and respiratory rate of 25 breaths/min. The abdominal examination showed a distended abdomen with collateral venous circulation. The patient had dehydration folds and cold extremities with oliguria, but no meningeal or cutaneous signs.

Biological examinations on day 1 revealed CRP levels of 161 mg/L, leukocytes at 5,400 elements/mm^3 with 95% of neutrophils and 2% of lymphocytes, and hemoglobin at 9.2 g/dL. On day 2, the ascites examination revealed 243 leucocytes/mm^3, predominantly lymphocytes (93%). Direct examination after Gram staining of ascites fluid revealed the presence of budding yeasts. On day 4, the culture of ascites fluid after two days of incubation on Sabouraud's media showed the presence of yeasts colonies (Fig. 1), identified using BD Phoenix100 yeast ID panel (Becton Dickinson Diagnostics, USA) as *Cryptococcus neoformans* at 99.99% confidence. Immunohistochemical stains, such as Grocott-Gomori's methenamine silver stain, periodic acid-Schiff stain, or mucicarmine stain, were not used. Fever associated with diffuse interstitial lung disease and bilateral pleural effusion on computed tomography indicated a cytobacteriological examination of the pleural fluid. On day 5, the cytology of the pleural fluid revealed leukocytes at 2,420 elements/mm^3 with lymphocyte predominance (65%). On day 7, the pleural fluid was cultured on chocolate agar media in the presence of CO_2 and anaerobic atmosphere. The culture was positive, allowing for the isolation of *Cryptococcus neoformans*. Sabouraud's media supplemented with actidione was used for this culture as well for the liquid of ascites and the pleural fluid. It remained sterile after 5 days of incubation for both liquids. Lumbar puncture was contraindicated because of the bleeding risk (prothrombin time at 29%). Bacteriological examination of the blood culture or cerebrospinal fluid (CSF) was not prescribed for the patient, and the HIV serology was negative. On day 4, fluconazole was immediately administered intravenously at the dose of 800 mg/day. At the fourth day of treatment (day 8), the patient died because of the deterioration of neurological and hepatocellular functions. No autopsy was performed to clarify the cause of death. The deceased patient's dependents gave consent to our use of the anonymized patient data.

DISCUSSION

Cryptococcosis is a serious infection caused by the encapsulated yeast *Cryptococcus neoformans*. It is a ubiquitous fungus isolated from the soil and pigeon droppings[3]. The direct relationship between pigeon droppings and *Cryptococcus* infection in the present case has not been established. Indeed, the multiplicity of possible sources, especially in an urban environment, makes the accurate determination of the source nearly impossible[4]. The portal of entry of this fungus is pulmonary, and the dissemination of the infection is via the blood[4-7], which is likely the case in our patient. The prevalence of exposure to *Cryptococcus neoformans* is high worldwide because 80% of subjects have anti-*C. neoformans* antibodies. However, the disease is relatively rare[8]. The most common manifestation of this fungal infection is the involvement of the central nervous system in the form of sub-acute or chronic meningitis or cerebral cryptococcomas in rarer cases[7]. However, cryptococcosis is a severe opportunistic infection, which could affect several organs[9]. Ascites of cryptococcal origin is rare. Only 62 cases have been described in the literature[10,11]. Pulmonary involvement usually consists of granulomatous and infiltrated reactions, similar to that in the present case[12]. Cryptococcal pleural effusions are rare[13]. Cryptococcosis mainly develops

in subjects with a deficiency in the cell-mediated immunity[9]. Therefore, patients with AIDS are at a higher risk of infection, but other conditions might predispose the patients to cryptococcosis, such as immunosuppression, corticosteroids, diabetes, cirrhosis, chronic leukemia and lymphoma[7,10,14,15]. As for our propositus, in the cases described in Crohn's disease, immunosuppressants and corticosteroids are thought to be the contributing factors to the infection and not Crohn's disease itself[15].

The diagnosis of cryptococcosis is based on the demonstration and direct examination of a specific encapsulated yeast of genus *Cryptococcus*. The culture on Sabouraud's medium without actidione is essential for the identification of the species[16,17]. As is the case in our patient, the diagnosis based on the detection of *Cryptococcus* on the culture of ascites fluid is delayed (average, 6 days). Therefore, 50% of cases are diagnosed post mortem[17]. Extra meningeal localizations of *C. neoformans* are rarely isolated, and systematic search must be encouraged for the spread of this yeast, especially at the meninges, even in the absence of neurological signs (systematic prescription of a cytobacteriological examination of the CSF in front of any form extrameningeal cryptococcosis)[18]. The blood cultures are of great interest in the diagnosis of disseminated cryptococcosis because they are positive in 30% cases[11]. The diagnosis would have been made earlier if our patient had been prescribed blood cultures in adapted culture media.

Disseminated cryptococcosis is an emergency situation that requires aggressive antifungal treatment[19]. The treatment conventionally uses amphotericin B (0.7 mg/kg/day) with or without 5-fluorocytosine (100 mg/kg/day) for 15 days. The relay is fluconazole 400 mg/day for 6~10 weeks and 200 mg/day for maintenance[17,20]. The treatment provided to our patient was insufficient (fluconazole alone). Despite well-managed medical treatment, the treatment failure rate for disseminated cryptococcal disease is 20%[8,21].

CONCLUSION

Disseminated cryptococcosis is a rare and serious fungal infection, which can be fatal because of the vital organs it affects, delayed diagnosis, and possibility of therapeutic failure. To improve its prognosis, the triad "clinical suspicion in subjects at-risk, early and correct diagnosis, early and well-guided antifungal treatment" must be followed.

CONFLICT OF INTEREST

In relation to this article, we declare that there is no conflict of interest.

ORCID

Adil Maleb: 0000-0002-1491-3914
Aziza Hami: 0000-0002-5939-197X
Yassine Ben Lahlou: ORCID not available
Somiya Lamrabat: 0000-0002-5701-6658
Safaa Rifai: ORCID not available
Nawal Rahmani: ORCID not available
Mohammed Bensalah: ORCID not available
Mohammed Frikh: 0000-0002-4451-5888
Abdelhay Lemnouer: 0000-0001-7982-2936
Mostafa Elouennass: 0000-0003-2944-6148

REFERENCES

1. Singh N, Husain S, De Vera M, Gayowski T, Cacciarelli TV. *Cryptococcus neoformans* infection in patients with cirrhosis, including liver transplant candidates. Medicine (Baltimore) 2004;83:188-192
2. El Ouazzani H, Achachi L, Belkhiri S, El Ftouh M, El Fassy Fihry MT. Cryptococcose disséminée chez un sujet apparemment immunocompétent. Rev Mal Respir 2009;26:788-793
3. Ward C. Prejudice against women: Who, when, and why? Sex Roles 1981;7:163-171
4. Charra B, Hachimi A, Nejmi H, Sodqi M, Benslama A, Motaouakkil S. Cryptococcose neuroméningée chez un sujet immunocompétent. Med Mal Infect 2005;35:549-551
5. Yoo SS, Tran M, Anhalt G, Barrett T, Vonderheid EC. Disseminated cellulitic cryptococcosis in the setting of prednisone monotherapy for pemphigus vulgaris. J Dermatol 2003;30:405-410
6. Revest M, Decaux O, Frouget T, Cazalets C, Albert JD, Chevrier S, et al. Infections à cryptocoque chez des patients non VIH. À propos de quatre cas et revue de la littérature. Rev Med Interne 2006;27:203-208
7. Albert-Braun S, Venema F, Bausch J, Hunfeld KP, Schäfer V. *Cryptococcus neoformans* peritonitis in a patient with alcoholic cirrhosis: Case report and review of the literature. Infection 2005;33:282-288
8. Aubry P. Mycoses profondes. Med Trop 2014;1-17

Copyright@2019 by The Korean Society for Medical Mycology

9. Minta DK, Traoré AM, Coulibaly I, Diallo K, Soukho-Kaya A, Dolo A, et al. Cryptococcose extra-neuroméningée au cours du sida à Bamako, Mali (à propos de 2observations). J Mycol Med 2014;24:e65-e71
10. Prieux-Klotz C, Larréché S, Delaune D, Sinayoko L, Corberand D, Ficko C. Cryptococcose disséminée révélée par une infection du liquide d'ascite. Vol. 46, Med Mal Infect 2016;46:456-457
11. El-Kersh K, Rawasia WF, Chaddha U, Guardiola J. Rarity revisited: Cryptococcal peritonitis. BMJ Case Rep 2013
12. Huston SM, Mody CH. Cryptococcosis: An emerging respiratory mycosis. Clin Chest Med 2009;30:253-264
13. Kamiya H, Ishikawa R, Moriya A, Arai A, Morimoto K, Ando T, et al. Disseminated cryptococcosis complicated with bilateral pleural effusion and ascites during corticosteroid therapy for organizing pneumonia with myelodysplastic syndrome. Intern Med 2008;47:1981-1986
14. Diamond RD, Bennett JE. Disseminated cryptococcosis in man: Decreased lymphocyte transformation in response to *Cryptococcus neoformans*. J Infect Dis 1973;127:694-697
15. Osawa R, Singh N. Colitis as a manifestation of infliximab-associated disseminated cryptococcosis. Int J Infect Dis 2010;14:e436-440
16. Ehui E, Eholie SP, Kakou A, Gbery I, Diomande IM, Adou-Bryn KD, et al. Cryptococcose disséminée révélée par une atteinte cutanée au cours du SIDA (French). Disseminated cryptococcosis reveal by cutaneous manifestations course AIDS. J Mycol Med 2010;10:97-109
17. Jarvis JN, Harrison TS. Pulmonary cryptococcosis. Semin Respir Crit Care Med 2008;29:141-150
18. Carter EA, Henderson DW, McBride J, Sage MR. Case report: Complete lung collapse - An unusual presentation of cryptococcosis. Clin Radiol 1992;46:292-294
19. Ammouri W, Harmouche H, Afifi Y, Tazi Mezalek Z, Adnaoui M, Aouni M, et al. A case of disseminated cryptococcosis complicating treatment of pemphigus vulgaris with prednisone and azathioprime. Pan Afr Med J 2011;10:35
20. Brouwer AE, Rajanuwong A, Chierakul W, Griffin GE, Larsen RA, White NJ, et al. Combination antifungal therapies for HIV-associated cryptococcal meningitis: A randomised trial. Lancet 2004;363:1764-1767
21. Elavsky CM, Mislan C, Elavsky S. When talking less is more: Exploring outcomes of Twitter usage in the large-lecture hall. Learn Media Technol 2011;36:215-233