ORIGINAL ARTICLE

J Mycol Infect 2019; 24(1): 19-27
pISSN:1226-4709, eISSN:2465-8278
http://dx.doi.org/10.17966/JMI.2019.24.1.19

JMI

Treatment Outcomes of Combination Therapy with 1,064-nm Neodymium-doped Yttrium Aluminum Garnet Laser and Efinaconazole 10% Solution for Big Toenail Onychomycosis: a Retrospective Study

Dong Hye Suh[1,*], Hyung Jin Park[2,*], Sang Jun Lee[1], Hyunjoo Kim[1], Ki-Heon Jeong[2], Mu-Hyoung Lee[2] and Min Kyung Shin[2†]

[1]Arumdaun Nara Dermatologic Clinic, Seoul, Korea
[2]Department of Dermatology, School of Medicine, Kyung Hee University, Seoul, Korea

Background: Laser therapy can be used as an alternative treatment for onychomycosis; however, there are some limitations to its efficacy as a single agent.

Objective: To evaluate the effectiveness of combination therapy with 1,064-nm neodymium-doped yttrium aluminum garnet (Nd:YAG) laser and topical efinaconazole in onychomycosis treatment and identify factors influencing the therapeutic outcomes of combination treatment.

Methods: Big toenails with onychomycosis were treated by 1,064-nm Nd:YAG laser at 4-week intervals with daily application of topical efinaconazole. Therapeutic response was assessed through onychomycosis severity index (OSI) and percentage of nail infected (PNI), and its association with a variety of factors that may affect treatment outcome was evaluated.

Results: One hundred big toenails were included in the study and significant clinical improvements were observed after treatment (OSI improvement score = 76.68 ± 28.83, PNI improvement score = 72.37 ± 30.37). There was no difference in treatment response according to the number of laser treatments, onychomycosis clinical type, or initial severity. However, patient age was negatively correlated with clinical improvement (p = 0.019). Also, female patients had better therapeutic responses than male patients.

Conclusion: Combined treatment with Nd:YAG laser and topical efinaconazole has a significant therapeutic effect on onychomycosis. A randomized controlled trial is warranted in the future.

Key Words: Combination treatment, Laser, Onychomycosis

Received: November 16, 2018 **Revised:** December 2, 2018 **Accepted:** January 31, 2019

*These authors contributed equally.
†**Corresponding:** Min Kyung Shin, Department of Dermatology, School of Medicine, Kyung Hee University, #23, Kyungheedae-ro, Dongdaemun-gu, Seoul 02447, Korea.
Phone: +82-2-958-8300, **Fax:** +82-2-969-6538, **e-mail:** haddal@hanmail.net

Copyright@2019 by The Korean Society for Medical Mycology. All right reserved.
This is an open-access article distributed under the terms of the Creative Commons Attribution Non-Commercial License (http://creativecommons.org/licenses/by-nc/3.0/), which permits unrestricted non-commercial use, distribution, and reproduction in any medium, provided the original work is properly cited. http://www.ksmm.org

INTRODUCTION

Onychomycosis is a common nail disorder caused by a fungal infection. It is known that 2~13% of the general population is affected by onychomycosis, and the prevalence is higher in the elderly, reaching 14~28%. Although there are various treatment options for onychomycosis, oral antifungal agents such as terbinafine, itraconazole, or fluconazole are the treatments of choice. Unfortunately, these agents are contraindicated in some patients, including those with severe hepatic or renal diseases, pregnant or lactating females, and in those with hypersensitivities to these drugs. In addition, drug interactions are often a concern[1]. Topical antifungal agents and recently introduced laser devices are alternative therapeutic modalities for treating onychomycosis.

Various laser devices, including the neodymium-doped yttrium aluminum garnet (Nd:YAG) laser, have been developed for the treatment of onychomycosis. Although there are many reports that lasers are effective for treating nail fungal infection, other studies yielded disappointing results[2-6]. Further, the mycological cure rate appears relatively low[7]. In this context, the US Food and Drug Administration currently indicates these devices for "temporary increase in clear nails", and the devices are not considered curative, or able to eradicate pathogenic fungi. A recently published review article concluded that there was limited evidence that laser therapies eradicated pathogenic fungi in patients with onychomycosis[8]. Topical agents such as amorolfine, ciclopirox, and tioconazole have been used for onychomycosis treatment, but they are less-frequently recommended, and their therapeutic effects are smaller than systemic antifungals. Topical agents are recommended for superficial white onychomycosis (SWO) or distal and lateral subungual onychomycosis (DLSO) with nail involvement less than 50% or 80%[1-9].

Because both of the above treatments have some limitations as single modalities we evaluated the possibility of a combined treatment. Although there is exists no published head-to-head comparative study, topical efinaconazole is recommended as a first-line topical treatment[1] based on its superior mycological cure rates, as determined by meta-analysis. Therefore, we examined the therapeutic effects of a combination treatment consisting of 1,064-nm Nd:YAG laser (which shows a high clinical clearance rate) and topical efinaconazole solution (with a better mycological cure rate).

There are two previous studies of treatments that combined lasers and topical antifungals[10,11], but the number of laser treatments was restricted and factors associated with therapeutic responses were not analyzed. In this study we observed patients' therapeutic responses following combined treatment and analyzed the factors that potentially affected treatment efficacy.

MATERIALS AND METHODS

This study was approved by the hospital's Institutional Review Board (KHUHMDIRB 2018-10-064) and conducted according to principles of the Declaration of Helsinki. A retrospective chart review was conducted wherein data were collected for patients with onychomycosis who were treated using a combination therapy consisting of a 1,064-nm Nd:YAG laser and topical efinaconazole, between July 2017 and September 2018. We also searched for any recorded adverse events that occurred during or after treatment.

1. Patients

Patients with clinical features of onychomycosis on their big toenails, confirmed by mycological evaluation were enrolled. Mycological diagnosis of onychomycosis was based on microscopic examination after treatment with 20% potassium hydroxide (KOH). In cases of ambiguous results upon microscopic examination, a fungal culture on Sabouraud's dextrose agar with incubation at room temperature (25~27℃) for up to 4-weeks was performed. Patients taking oral antifungal medications within 6-months of the study and those using other topical antifungal agents, other than the topical solution of 10% efinaconazole, within 1-year of the study were excluded. We excluded patients with permanent discoloration of the nail plate and those with concomitant nail diseases, such as nail psoriasis.

2. Treatment protocol

Before treatment, photographs were taken in a standardized format using a digital camera (Canon EOS-40D; Canon Corp., Tokyo, Japan). If the target toenail was thicker than 2 mm, it was mechanically debrided using a nail grinder before the laser treatment. All patients were treated using a 1,064-nm Nd:YAG laser (Pinpointe™ Footlaser™; Pinpointe USA Inc., Chico, CA, USA) at the following settings: pulse energy, 200 mJ; pulse width, 0.1 ms; spot size, 1.5 mm; frequency; 30 Hz. The laser beam was moved in a spiral fashion to cover the entire nail plate. This procedure was repeated twice with a 2-minute pause between treatments. Laser treatments were scheduled at 4-week intervals (±2 weeks). Throughout this time, all subjects were educated to self-apply a topical solution with efinaconazole 10% to their infected big toenails once daily. If

Copyright@2019 by The Korean Society for Medical Mycology

Table 1. Patients' demographics and therapeutic responses of enrolled big toenails

Characteristics		
Patients (nails)	86 (100)	
Age (years)	51.62 ± 12.88 (11~80)	
Clinical type	DLSO†	72
	SWO‡	14
	TDO§	14
	PSO‖	0
Treatment number	8.38 ± 4.07 (3~16)	
Initial OSI¶	13.63 ± 7.98	
Final OSI	3.60 ± 5.58	
OIS**	76.68 ± 28.83	
Initial PNI††	49.35 ± 30.11	
Final PNI	14.65 ± 20.89	
PIS‡‡	72.37 ± 30.37	
Favorable response rate***	68%	
Clinical cure rate****	64%	

*Data shown as mean±standard deviation, †Distal and lateral subungual onychomycosis, ‡Superficial white onychomycosis, §Total dystrophic onychomycosis, ‖Proximal subungual onychomycosis, ¶Onychomycosis severity index, **OSI improvement score, ††Percentage nail involvement, ‡‡PNI improvement score, ***Defined as proportion of toenails with greater than 75% decrease in OSI, ****Defined as proportion of toenails with final OSI less than 5 and final PNI less than 10

100% clinical clearance was observed, treatment was paused and a final follow-up evaluation was scheduled 4-weeks later.

3. Outcome assessment

Clinical improvement was evaluated using the onychomycosis severity index (OSI)[12] and percentage of nail infected (PNI). For OSI, the degree of involvement was scored as follows: 0, 0% invasion of the entire nail surface from onychomycosis; 1, invasion ratio 1 to 10%; 2, invasion ratio 11 to 25%; 3, invasion ratio 26 to 50%; 4, invasion ratio 51 to 75%; and 5, invasion ratio 76 to 100%. In addition, the nail from the edge to the proximal nail fold was divided into four sections and invasion was scored as follows: 1, 1/4 or less; 2, 1/4 to 1/2; 3, 1/2 to 3/4; 4, 3/4 or more; 5, invasion had proceeded to the nail lunula or nail matrix. To obtain the final OSI value, these two scores were multiplied and 10 points were added if we observed dermatophytoma or subungual hyperkeratosis of 2 mm or greater. OSI was evaluated by three dermatologists including the therapist, and the mean value of the three evaluations was adopted. The OSI improvement score (OIS) was defined as the difference between initial OSI and final OSI divided by initial OSI. Favorable response rate was defined as the percentage of toenails where OSI decreased by more than 75% compared to the initial value. PNI was defined as the ratio of the big toenail area showing clinical symptoms of onychomycosis, and the PNI improvement score (PIS) was calculated in the same way as OIS. The clinical cure rate was estimated as the proportion of toenails in which final OSI was less than 5, and final PNI was less than 10.

4. Statistical analysis

All statistical analyses were computed using SPSS software version 20.0 (SPSS Inc., Chicago, IL, USA) Continuous variables are presented as means ± standard deviations. We used a paired *t*-test to evaluate improvement in OSI and PNI pre- to post-treatment. Pearson's correlation and regression analyses were performed to study the relationship between OIS or PIS and other variables. Patients were divided into two severity groups based on the nail variables proposed by Park et al.[1] and Student's *t*-test, analysis of covariance, and Pearson's chi-square test were used to analyze differences in treatment response. A *p*-value less than 0.05 was considered to reflect statistical significance.

RESULTS

A total of 100 infected big toenails from 86 patients were included in this study (Table 1). There were 27 patients with underlying disease (Table 2). Three patients were immunocompromized due to medication for ulcerative colitis or were in a kidney transplanted state because of chronic renal failure, or a liver transplanted state after hepatectomy because of hepatocellular carcinoma. Table 1 shows the patients' demographic data and therapeutic responses of enrolled big toenails.

The mean age of the included patients was 51.62 ± 12.88 years, and the average number of treatments was 8.38 ± 4.07. Both OSI and PNI significantly decreased after treatment ($p < 0.001$ for both). OIS was 76.68 ± 28.83 and PIS was 72.37 ± 30.37. The favorable response rate was 68% and the clinical cure rate was 64% (Table 1). Fig. 1 shows representative cases with favorable improvement after treatment and Fig. 2 shows representative cases with no significant changes after treatment.

Table 2. Enrolled patients' past medical histories

Immunocompromized patients (n = 3)		
Ulcerative colitis (n = 1)		
Kidney transplanted state because of chronic renal failure (n = 1)		
Liver transplanted state after hepatectomy because of hepatocellular carcinoma (n = 1)		
Immunocompetent patients (n = 24)		
Hypertension (n = 6*)	Heart failure (n = 1*)	Chronic hepatitis B carriers (n = 3*)
Hyperlipidemia (n = 1)	Stroke (n = 1*)	Fatty liver (n = 2)
Diabetes mellitus (n = 4*)	Breast cancer (n = 1)	Gastritis (n = 5*)
Hypothyroidism (n = 1)	Rheumatic arthritis (n = 1)	Benign prostate hyperplasia (n = 1)
Meniere's disease (n =1)		

*Count redundancy

Table 3. Correlation analysis between onychomycosis severity index improvement score or percentage of nail involvement improvement score and other variables

Correlation with OIS	Coefficient of correlation*	Partial correlation coefficient†	Adjusted coefficient of determination§
Age	**-0.268 (p = 0.007)**	-0.196 (p = 0.056)	–
Number of treatments	0.106 (p = 0.294)	0.029 (p = 0.776)	–
Clinical type	**-0.207 (p = 0.039)**	-0.068 (p = 0.511)	–
Initial OSI	-0.185 (p = 0.065)	-0.078 (p = 0.450)	–
Correlation with PIS	**Coefficient of correlation***	**Partial correlation coefficient†**	**Adjusted coefficient of determination§**
Age	**-0.310 (p = 0.002)**	**-0.238 (p = 0.019)**	**0.087 (p = 0.002)**
Number of treatments	0.169 (p = 0.093)	-0.090 (p = 0.382)	–
Clinical type	**-0.216 (p = 0.031)**	0.086 (p = 0.405)	–
Initial PSI	-0.112 (p = 0.267)	0.005 (p = 0.960)	–

*Pearson's correlation analysis, †Partial correlation analysis, controlling for other variables, §Multiple regression analysis

We considered age, the number of treatments, clinical type, and initial severity as factors that might be related to treatment response, and analyzed the relationship between these variables and OIS or PIS (Table 3). During Pearson's correlation analysis, age and clinical type showed a weak negative correlation, but no significant relationship was confirmed in the partial correlation analysis controlling for other variables. For PIS, age showed a weak negative correlation with PIS during the partial correlation analysis, and the regression equation was as follows: [PIS = 110.270 - (0.734 × age), p = 0.002, adjusted coefficient of determination = 0.087]. Clinical type was associated with PIS during Pearson's correlation analysis, but not during partial correlation analysis.

Next, we divided the patients into two groups according to the presence or absence of nail variables that reflect the severity of onychomycosis. Toenails with a SWO type or DLS type with less than 50% of area involvement were assigned to the mild onychomycosis group, and toenails showing DLSO type with an area involvement greater than 50%, TDO type, or toenails with spikes, fungal balls, dermatophytoma, or sub-

Copyright@2019 by The Korean Society for Medical Mycology

Fig. 1. Example of big toenails with favorable therapeutic responses to combination treatment (A, B) Baseline and final clinical photographs of right big toenail exhibiting a favorable therapeutic response after three sessions of combination treatment (C, D) Baseline and final clinical photographs of right big toenail exhibiting a favorable therapeutic response after four sessions of combination treatment (E, F) Baseline and final clinical photographs of left big toenail exhibiting a favorable therapeutic response after six sessions of combination treatment (G, H) Baseline and final clinical photographs of right big toenail exhibiting a favorable therapeutic response after 16 sessions of combination treatment

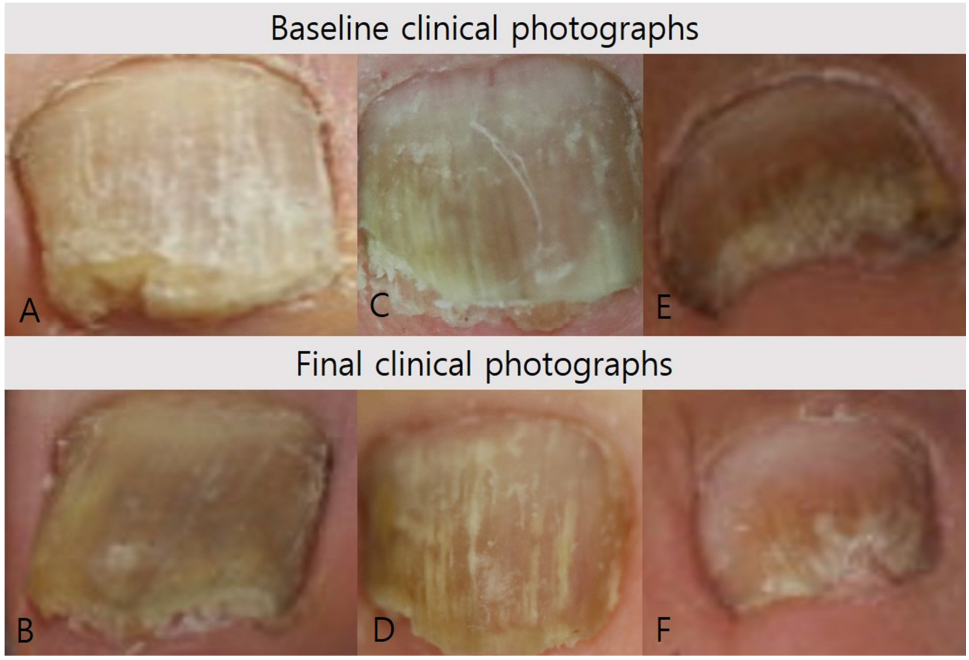

Fig. 2. Example of big toenails with poor therapeutic responses to combination treatment (A, B) Baseline and final clinical photographs of right big toenail exhibiting a poor therapeutic response after five sessions of combination treatment (C, D) Baseline and final clinical photographs of left big toenail exhibiting a poor therapeutic response after 10 sessions of combination treatment (E, F) Baseline and final clinical photographs of right big toenail exhibiting a poor therapeutic response after 13 sessions of combination treatment

ungual hyperkeratosis thicker than 2 mm were classified as the moderate to severe onychomycosis group. We analyzed the difference in treatment response between the two groups (Table 4).

There was no difference in the number of treatments between the two groups, but mean age was higher in the moderate to severe onychomycosis group (p = 0.001). Because age is likely to affect treatment response (Table 3), we performed an analysis of covariance (ANCOVA), controlling for age. ANCOVA showed no between-group difference in OIS or PIS. However, both favorable response rate (p = 0.018) and clinical cure rate (p < 0.001) were higher in the mild onychomycosis group.

Finally, we studied whether the treatment response differed by sex (Table 5). Mean age (p = 0.549), number of treatments (p = 0.210), initial OSI (p = 0.439), and PIS (p = 0.905) did not

Table 4. Demographics and therapeutic outcomes according to degree of onychomycosis

	Mild onychomycosis* (n = 58)	Moderate to severe onychomycosis† (n = 42)	p value
Age	48.16 ± 11.87	56.33 ± 12.83	**p = 0.001‡**
Number of treatments	8.56 ± 4.25	8.05 ± 3.86	p = 0.897§
OSI (initial → final)	9.37 ± 5.31 → 1.60 ± 2.37	19.60 ± 7.21 → 6.38 ± 7.33	
OIS	81.95 ± 27.04	69.36 ± 30.22	p = 0.159§
PNI (initial → final)	34.12 ± 19.71 → 7.02 ± 9.11	70.36 ± 29.66 → 25.12 ± 27.33	
PIS	77.45 ± 28.70	65.50 ± 31.91	p = 0.294§
Favorable response rate	75.86%	57.15%	**p = 0.018‖**
Clinical cure rate	81.03%	40.48%	**p < 0.001‖**

*Toenails without nail variables reflecting severe onychomycosis (SWO type or DLSO type with involved area less than 50%)
†Toenails with nail variables reflecting severe onychomycosis [DLSO type with involved nail more than 50%, TDO type, or toenails with spike, fungal ball, dermatophytoma, subungual hyperkeratosis greater than 2 mm in thickness]
‡Student's t-test, §Analysis of covariance controlling for age, ‖ Pearson's chi-square test

Table 5. Demographics and therapeutic outcomes according to sex

	Male toenail (n = 34)	Female toenail (n = 66)	p value
Age	52.71 ± 9.70	51.06 ± 14.30	p = 0.549†
Number of treatments	8.50 ± 4.19	8.31 ± 4.04	p = 0.210†
OSI (initial → final)	12.76 ± 7.31 → 4.59 ± 5.93	14.08 ± 8.32 → 3.09 ± 5.36	
OIS	67.19 ± 31.61	81.56 ± 26.22	**p = 0.017†**
PNI (initial → final)	49.85 ± 30.76 → 20.29 ± 24.71	49.09 ± 30.01 → 11.74 ± 18.16	
PIS	62.16 ± 31.59	77.63 ± 28.56	**p = 0.015†**
Favorable response rate	47.06%	78.79%	**p = 0.001‡**
Clinical cure rate	50.00%	71.21%	**p = 0.036‡**

*Toenails without nail variables reflecting severe onychomycosis (SWO type or DLSO type with involved area less than 50%)
†Student's t-test, ‡Pearson's chi-square test

Copyright@2019 by The Korean Society for Medical Mycology

differ between male and female patients, and the treatment response in females was favorable for all aspects of OIS (p = 0.017), PIS (p = 0.015), favorable response rate (p = 0.001), and clinical cure rate (p = 0.036). No patients discontinued treatment because of side effects, and no sustained side effects other than a temporary heating sensation were recorded.

DISCUSSION

Laser therapies for onychomycosis have recently been in the spotlight as alternative treatment options for patients who cannot be treated with oral antifungal agents or are reluctant to undergo such treatments[1]. Most published studies of laser therapy for onychomycosis used 1,064-nm Nd:YAG lasers. Although many studies have reported the efficacy of 1,064-nm Nd:YAG for treating nail fungal infections, some studies showed conflicting results[2-6]. The therapeutic mechanism of laser therapy for onychomycosis has not yet been elucidated; however, there are several hypotheses, including local hyperthermia-induced fungal apoptosis and an indirect antifungal effect, selective photo-thermolysis targeting melanin in fungal cell walls, keratin denaturation altering the nail bed environment, and promotion of nail growth due to thermal effects[2,3,13,14]. Another problem with this therapy is that the mycological cure rate is lower than the clinical cure rate[7].

Topical antifungal agents are an alternative treatment option in patients with contraindications for systemic antifungals, but their therapeutic effects are often insufficient. The role of monotherapy with topical antifungals is limited by the hard keratin and compact structure of the dorsal nail plate that acts as a barrier to topical drug diffusion; further, the hydrophilic nature of the nail plate precludes absorption of these drugs[9]. In this regard, we investigated the efficacy of a combination treatment consisting of lasers with topical efinaconazole to improve treatment results.

There are two previous reports of combined treatments with topical antifungal agents and lasers for onychomycosis. Bonhert et al.[10] conducted a 48-week clinical study with daily self-application of topical efinaconazole and 6 Nd:YAG laser treatments every 4 weeks. They reported an approximately 70% rate of clinical improvement, as evaluated by a scoring system at week 48. Park et al.[11] reported that the lesion-free area increased from 40.76% to 74.39% at week 16 (which is about 48.33% in terms of PIS used in this study) after 4 sessions of Nd:YAG laser treatment with daily topical amorolfine nail lacquer application.

We found that combination therapy, with an average 8.4 sessions of 1,064-nm Nd:YAG laser treatment and daily application of topical efinaconazole for 9 months, resulted in a greater than 70% clinical improvement rate as evaluated by OSI and PNI. The favorable response and clinical cure rates were approximately 60 to 70%. Although the study design and treatment protocol were different, our results are generally consistent with those of the previous studies of combination treatment. In comparison with the treatment efficacies reported in pre-existing studies we are able to at least partially determine whether the combination therapy has a superior effect over monotherapy (laser or topical medication).

For topical efinaconazole, Pollak et al.[15] reported that at week 48, 39.1% of participants achieved treatment success, defined as at least a 50% improvement in affected toenails from baseline. The median PNI decreased from 50% to 40%. Elewski et al.[16] reported that treatment success (defined as percent affected target toenail $\leq$ 10%) for efinaconazole ranged from 17.9% to 44.8% at week 48. For laser treatment, Kim et al.[2] showed that at weeks 12, 25.3% of patients, and at week 24, 31.6% of patients showed marked improvement, defined as greater than 75% increase in normal appearing nail length. Yang et al.[17] reported that the clinical clearance rate was 29.03% at week 12 and 64.52% at week 24. Therefore, it can be inferred that the combination treatment used in this trial produces superior therapeutic results than monotherapy of either laser or topical antifungals.

We also reviewed patients' ages, sex, number of treatments, onychomycosis clinical type, and initial severity as candidate factors that could affect the clinical outcomes. We found that age and sex had some impact on the outcomes. This is consistent with a report by Gupta and Paquet[3], showing that patients younger than 60 years and female patients had better outcomes and that initial severity did not affect therapeutic outcomes. We hypothesized that increased nail thickness or nail surface changes, such as onychorrhexis resulting from the natural process of aging, decreases the laser beam penetration and increase scattering[18]. However, since the adjusted coefficient of determination in our study was low at 0.087, the effect of age was not strong. In contrast, sex-related differences in nail plate character such as thickness appear to have affected treatment response. It is also possible that female patients had higher compliance with the topical treatment than male patients. Further studies are required to identify other factors that may influence therapeutic outcomes. There was no significant difference in OIS and PIS between the mild onychomycosis group and moderate to severe onychomycosis group, as determined by nail variables that reflected severity. This result suggests that the above combination treatment might be more effective than topical antifungal treatments, even for severe cases of onychomycosis.

A strength of our study is that we obtained long-term, real-world data for up to 16 laser treatments. In previous studies of combination therapy, even though the follow-up period was up to 52 weeks, only 4~6 laser treatments were performed. In the absence of clinical improvement, we continued laser therapy, so the number of treatments in this study was higher than in previous reports. Nevertheless, there was no direct correlation between the number of treatments and clinical improvement. It can be hypothesized that if only a certain number of laser treatments are given, the number of sessions does not have a decisive influence on therapeutic outcomes. However, further research is needed to verify this hypothesis. In addition, we cannot exclude the possibility that improved clinical outcomes, according to the number of treatments, are masked by the present study design which was based on clinical data. Notably, treatments are likely to be discontinued, when clinical improvement is observed. Because the growth rate of the big toenail is faster than those of other nails, and the involved area was easier to determine, the results of this study are likely to be more consistent than those of other studies that included all nails. In addition, the effectiveness of our treatment was verified using multiple scoring systems.

Several study limitations should be noted and considered. A follow-up mycological study was not performed and, as a consequence, we could not evaluate the mycological cure rate. In addition, differences in outcomes according to mycological species were not determined. Further research is needed, including a prospective randomized controlled study to overcome these limitations.

In conclusion, we show that 1,064-nm Nd:YAG laser treatment combined with topical efinaconazole solution application significantly improved onychomycosis symptoms and possessed a good safety profile. Observed treatment effects appeared to be independent of initial severity. However, the treatment effect may be somewhat reduced as patient age increases and better therapeutic effects were observed in female patients.

CONFLICT OF INTEREST

In relation to this article, we declare that there is no conflict of interest.

ORCID

Dong Hye Suh: 0000-0002-7133-3895
Hyung Jin Park: 0000-0002-5952-9158
Sang Jun Lee: 0000-0002-2820-7340
Hyunjoo Kim: 0000-0002-6854-013X
Ki-Heon Jeong: 0000-0001-6908-0932
Mu-Hyoung Lee: 0000-0002-0902-6843
Min Kyung Shin: 0000-0001-9834-7931

REFERENCES

1. Park J, Nam JH, Lee JH, Park JS, Mun JH, Lee YW, et al. Korean guideline for the diagnosis and treatment of onychomycosis: purpose and process of algorithm guideline development. J Mycol Infect 2018;23:33-44
2. Kim TI, Shin MK, Jeong KH, Suh DH, Lee SJ, Oh IH, et al. A randomised comparative study of 1,064 nm Neodymium-doped yttrium aluminum garnet (Nd:YAG) laser and topical antifungal treatment of onychomycosis. Mycoses 2016;59:803-810
3. Gupta AK, Paquet M. A retrospective chart review of the clinical efficacy of Nd:YAG 1,064-nm laser for toenail onychomycosis. J Dermatolog Treat 2015;26:376-378
4. Wanitphakdeedecha R, Thanomkitti K, Bunyaratavej S, Manuskiatti W. Efficacy and safety of 1,064-nm Nd:YAG laser in treatment of onychomycosis. J Dermatolog Treat 2016;27:75-79
5. Kim MS, Jung JY, Cho EB, Park EJ, Kim KH, Kim KJ. The effectiveness of 1,064-nm long-pulsed Nd:YAG laser in the treatment of severe onychomycosis. J Cosmet Laser Ther 2016;18:317-322
6. Karsai S, Jäger M, Oesterhelt A, Weiss C, Schneider SW, Jünger M, et al. Treating onychomycosis with the short-pulsed 1,064-nm-Nd:YAG laser: results of a prospective randomized controlled trial. J Eur Acad Dermatol Venereol 2017;31:175-180
7. Gupta AK, Versteeg SG. A critical review of improvement rates for laser therapy used to treat toenail onychomycosis. J Eur Acad Dermatol Venereol 2017;31:1111-1118
8. Gupta AK, Foley KA, Daigle D. Clinical trials of lasers for toenail onychomycosis: The implications of new regulatory guidance. J Dermatolog Treat 2017;28:264-270
9. Ameen M, Lear JT, Madan V, Mohd Mustapa MF, Richardson M. British Association of Dermatologists' guidelines for the management of onychomycosis 2014. Br J Dermatol 2014;171:937-958
10. Bonhert K, Dorizas A, Sadick NS. Efficacy of combination therapy with efinaconazole 10% solution and 1,064 nm Nd:YAG laser for treatment of toenail onychomycosis. J Cosmet Laser Ther 2018;27:1-5
11. Park KY, Suh JH, Kim BJ, Kim MN, Hong CK. Randomized

Copyright@2019 by The Korean Society for Medical Mycology

clinical trial to evaluate the efficacy and safety of combination therapy with short-pulsed 1,064-nm neodymium-doped yttrium aluminium garnet laser and amorolfine nail lacquer for onychomycosis. Ann Dermatol 2017;29:699-705
12. Carney C, Tosti A, Daniel R, Scher R, Rich P, DeCoster J, et al. A new classification system for grading the severity of onychomycosis: Onychomycosis Severity Index. Arch Dermatol 2011;147:1277-1282
13. Kimura U, Takeuchi K, Kinoshita A, Takamori K, Hiruma M, Suga Y. Treating onychomycoses of the toenail: clinical efficacy of the sub-millisecond 1,064 nm Nd:YAG laser using a 5 mm spot diameter. J Drugs Dermatol 2012;11:496-504
14. Shin MK, Kim TI, Kim WS, Park HK, Kim KS. Changes in nail keratin observed by Raman spectroscopy after Nd:YAG laser treatment. Microsc Res Tech 2017;80:338-343
15. Pollak RA, Ilie C. Long-term follow-up of onychomycosis patients treated with efinaconazole. J Drugs Dermatol 2017;16:1269-1273
16. Elewski BE, Rich P, Pollak R, Pariser DM, Watanabe S, Senda H, et al. Efinaconazole 10% solution in the treatment of toenail onychomycosis: Two phase III multicenter, randomized, double-blind studies. J Am Acad Dermatol 2013;68:600-608
17. Xu Y, Miao X, Zhou B, Luo D. Combined oral terbinafine and long-pulsed 1,064-nm Nd:YAG laser treatment is more effective for onychomycosis than either treatment alone. Dermatol Surg 2014;40:1201-1207
18. El-Domyati M, Abdel-Wahab H, Abdel-Azim E. Nail changes and disorders in elderly Egyptians. J Cosmet Dermatol 2014;13:269-276