CASE LETTER
J Mycol Infect 2026; 31(1): 48-50
pISSN:3058-423X, eISSN:3058-4302
https://dx.doi.org/10.17966/JMI.2026.31.1.48

JMI

Primary Cutaneous Cryptococcosis Mimicking Basal Cell Carcinoma

Jeongwu Seong[1,2], Yeona Kim[1,3], Jungsoo Lee[1,3], Kihyuk Shin[1,3], Hoon-Soo Kim[1,2], Byungsoo Kim[1,2], Moon-Bum Kim[1,2] and Hyun-Chang Ko[1,3†]

[1]Department of Dermatology, School of Medicine, Pusan National University, Busan, Korea
[2]Department of Dermatology, Pusan National University Hospital, Busan, Korea
[3]Department of Dermatology, Pusan National University Yangsan Hospital, Yangsan, Korea

Cryptococcosis is a systemic fungal infection caused by *Cryptococcus* species, with inhalation as the primary route of entry. It can disseminate hematogenously to several organs, including the central nervous system and skin. Cutaneous lesions are usually secondary, occurring in 10-20% of disseminated cases[1]. Primary cutaneous cryptococcosis (PCC), resulting from direct inoculation is rare and typically occurs in immunocompromised hosts, although a few cases have been reported in otherwise healthy individuals[2,3].

An 84-year-old woman presented with an ulcer in the right inner canthal area (Fig. 1A, B), which was associated with mild pain, tenderness, and pruritus but no systemic symptoms. The lesion had been present for 4 months, and no prior treatment had been administered. The patient had no history of diabetes mellitus, malignancy, chronic kidney disease, or HIV infection and had not taken immunosuppressive medications. She also reported no exposure to pigeons/avian excreta, other animals, or recent travel. Histopathology showed dermal inflammatory infiltration with numerous round yeast spores (Fig. 2A, B), and special stains highlighted encapsulated yeast (Fig. 2C-E). Tissue culture yielded creamy mucoid colonies (Fig. 2F), and lactophenol cotton blue staining demonstrated yeast cells with a capsule-like halo (Fig. 2G). 18S rRNA gene sequencing confirmed *Cryptococcus neoformans*. Serum cryptococcal antigen and HIV tests were negative. Computed tomography of the brain, chest, and abdomen along with cerebrospinal fluid analysis, showed no evidence of systemic involvement.

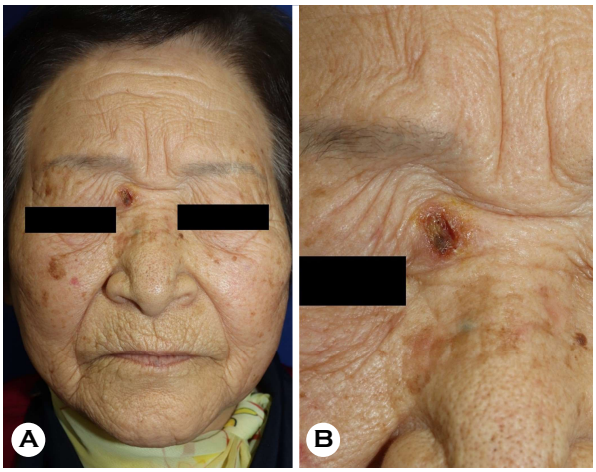

Fig. 1. An 84-year-old woman presented with an ulcerative lesion on the right inner canthal area. (A) Clinical overview, (B) Close-up view

The diagnosis of PCC was established according to the Noble and Fajardo criteria (absence of systemic infection, identification of *C. neoformans* from the skin lesion, and no extracutaneous involvement within the preceding 4 weeks). The patient was treated with oral fluconazole (6 mg/kg once

Received: February 17, 2026 Revised: February 25, 2026 Accepted: February 26, 2026
†Corresponding: Hyun-Chang Ko, Department of Dermatology, Pusan National University Yangsan Hospital, 20 Geumo-ro, Mulgeum-eup, Yangsan-si, Gyeongsangnam-do, 50612, Korea.
Phone: +82-55-360-1436, Fax: +82-55-360-1035, e-mail: hcko@pusan.ac.kr
Copyright@2026 by The Korean Society for Medical Mycology. All right reserved.
This is an open-access article distributed under the terms of the Creative Commons Attribution Non-Commercial License (http://creativecommons.org/licenses/by-nc/3.0/), which permits unrestricted non-commercial use, distribution, and reproduction in any medium, provided the original work is properly cited. http://www.ksmm.org

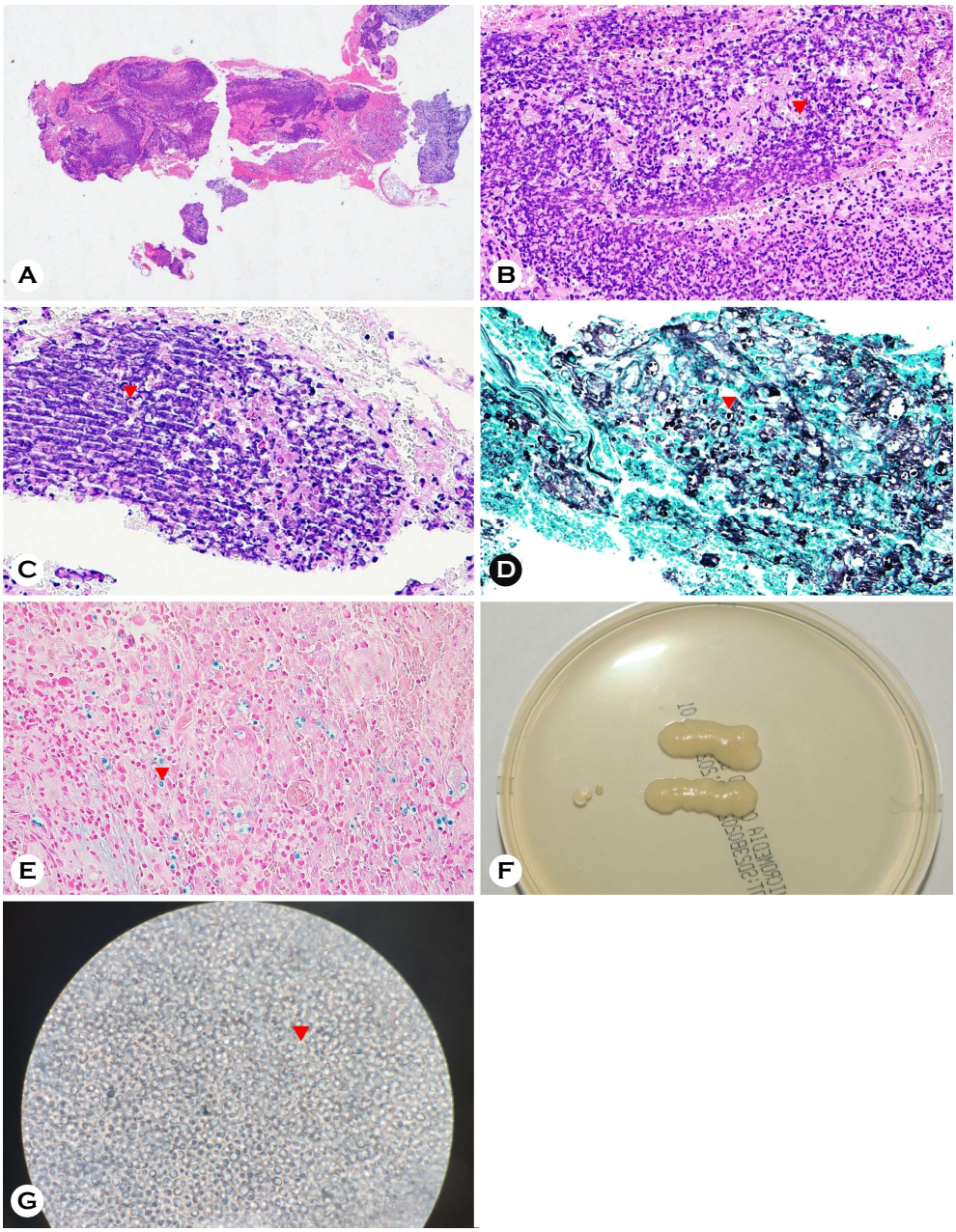

Fig. 2. (A) Low-power view showing dermal inflammatory infiltration (H&E, ×40). (B) Higher-power view demonstrating granulomatous inflammatory infiltration with numerous round yeast spores in the dermis (H&E, ×200. (C-E) Special stains highlighting yeast spores and capsular material (D-PAS, methenamine silver, and alcian blue, respectively; ×400). (F) Creamy mucoid colonies on Sabouraud dextrose agar on day 7. (G) Round-to-oval yeast cells with a capsule-like halo on lactophenol cotton blue staining. Arrowheads indicate representative yeast spores in panels B-E and a capsule-like halo in panel G.

daily). After 1 month, the lesion showed marked improvement, leaving only mild scar-like changes.

PCC shows polymorphic, nonspecific cutaneous manifestations, including nodules, ulcers, and cellulitis- or whitlow-like lesions, and may mimic other dermatologic conditions, including basal cell carcinoma (BCC)[2,4]. However, cutaneous cryptococcosis mimicking BCC has been reported mainly in immunocompromised hosts, suggesting that host immune

status may influence the clinical morphology of cutaneous cryptococcosis. Our case is notable for a similar presentation occurred in an immunocompetent patient. Although some case-based reviews have suggested favorable outcomes with itraconazole, our patient responded well to oral fluconazole, supporting its use in selected cases[2].

Although PCC has been frequently described in immunocompromised hosts, it is increasingly recognized that the disease can also occur in immunocompetent individuals[3]. In previously reported Korean cases, PCC was often associated with comorbidities, corticosteroid exposure, or local predisposing factors such as trauma[5], whereas our patient had no identifiable risk factors. While the precise route of infection remains unclear, inoculation through minor unrecognized skin breaks cannot be ruled out[2].

This case is clinically meaningful because PCC presented as a solitary ulcerative facial lesion mimicking BCC in an immunocompetent elderly patient. Therefore, when a chronic ulcerative lesion develops on the face and follows an atypical course, PCC should be included in the differential diagnosis, and definitive diagnosis may require histopathological examination with adjunctive mycological studies.

Key Words: *Cryptococcus neoformans*, Immunocompetent, Primary cutaneous cryptococcosis, Ulcer

ACKNOWLEDGEMENT

This study was supported by a 2026 research grant from Pusan National University Yangsan Hospital.

CONFLICT OF INTEREST

In relation to this article, we declare that there is no conflict of interest.

ORCID

Jeongwu Seong: 0000-0002-2904-271X
Yeona Kim: 0000-0001-9237-1113
Jungsoo Lee: 0000-0002-7519-8192
Kihyuk Shin: 0000-0001-8955-9828
Hoon-soo Kim: 0000-0002-7649-1446
Byungsoo Kim: 0000-0003-0054-8570
Moon-Bum Kim: 0000-0003-4837-0214
Hyun-Chang Ko: 0000-0002-3459-5474

PATIENT CONSENT STATEMENT

The patient provided written informed consent for the publication and the use of her images.

REFERENCES

1. Noble RC, Fajardo LF. Primary cutaneous cryptococcosis: Review and morphologic study. Am J Clin Pathol 1972; 57:13-22
2. Neuville S, Dromer F, Morin O, Dupont B, Ronin O, Lortholary O. Primary cutaneous cryptococcosis: A distinct clinical entity. Clin Infect Dis 2003;36:337-347
3. Gaviria Morales E, Guidi M, Peterka T, Rabufetti A, Blum R, Mainetti C. Primary cutaneous cryptococcosis due to *Cryptococcus neoformans* in an immunocompetent host treated with itraconazole and drainage: Case report and review of the literature. Case Rep Dermatol 2021;13:89-97
4. Silva Souza CD, Takada MH, Ambiel MV, Nakai VT. Primary cutaneous cryptococcosis: The importance of early diagnosis. An Bras Dermatol 2021;96:482-484
5. Kim TW, Park SM, Moon JH, Song M, Kim HS, Kim BS, et al. Primary cutaneous cryptococcosis in a patient with pulmonary tuberculosis. Korean J Med Mycol 2013;18: 111-116

 Copyright@2026 by The Korean Society for Medical Mycology