CASE REPORT
J Mycol Infect 2025; 30(4): 144-148
pISSN:3058-423X, eISSN:3058-4302
https://dx.doi.org/10.17966/JMI.2025.30.4.144

JMI

Primary Cutaneous Aspergillosis Mimicking Tinea Corporis: A Case Report

Presstisa Gifta Axelia[1,2], Trisiswati Indranarum[1,2†], Linda Astari[1,2] and Evy Ervianti[1,2]

[1]Department of Dermatology Venereology and Aesthetic, Dr. Soetomo General Academic Hospital, Surabaya, Indonesia
[2]Department of Dermatology Venereology and Aesthetic, Faculty of Medicine, Universitas Airlangga, Surabaya, Indonesia

Primary cutaneous aspergillosis (PCA) is a rare form of *Aspergillus* infection that usually affects immunocompromised people. However, it also occurs in healthy individuals, where it is often mistaken for common dermatophyte infections. We describe a case of a 27-year-old woman, with a normal immune system, who developed persistent, itchy, red to darkened patches on both lower legs for over two years. Initial examination and KOH microscopy suggested tinea corporis. Despite using oral antifungal medications and topical urea cream, the lesions only improved slightly. A fungal culture later identified *Aspergillus niger* as the cause. She was treated with 200 mg of oral itraconazole daily and topical urea cream, resulting in significant improvement after eight weeks. PCA in patients with healthy immune systems is rare and often results from minor, unnoticed trauma introducing fungus. Although *A. fumigatus* and *A. flavus* are more common causes, *A. niger* is an uncommon culprit. This case highlights the diagnostic difficulties of PCA given its resemblance to a dermatophyte infection. Fungal culture is an important diagnostic step, if available. Healthcare providers should think about PCA in unusual or long-lasting skin conditions that do not respond to treatment, even in healthy individuals, to ensure quick diagnosis and proper antifungal therapy management.

Key Words: Aspergillosis, *Aspergillus niger*, Immunocompetent, Itraconazole, Tinea corporis

INTRODUCTION

Primary cutaneous aspergillosis (PCA) is a rare condition, mainly affecting immunocompromised people, such as those with neutropenia, malignancies, or on immunosuppressive therapy. It usually develops when *Aspergillus* spp. is directly introduced into damaged skin, including areas with trauma, burns, surgical wounds, or occlusive dressings. However, recent reports have documented PCA in immunocompetent patients, where diagnosis is often delayed because of its nonspecific symptoms and resemblance to more common superficial fungal infections like tinea corporis. Oğuz et al. noted that out of 168 PCA cases reported across 114 articles from 1967 to 2017, the number of cases in immunocompetent patients was rather low[1,2].

Among *Aspergillus* species, *A. fumigatus* and *A. flavus* are the most common pathogens involved in PCA, while *A. niger* is rarer. Since PCA is rare in immunocompetent individuals and often resembles dermatophytosis, clinicians tend to rely heavily on clinical features and KOH microscopy, which may not always provide a definitive diagnosis. Cultures and, when available, histopathological examinations are crucial

Received: July 17, 2025 Revised: August 21, 2025 Accepted: October 19, 2025
†Corresponding: Trisiswati Indranarum, Department of Dermatology Venereology and Aesthetic, Dr. Soetomo General Academic Hospital, Jalan Prof. Dr. Moestopo No. 6-8, Surabaya, 60286, Indonesia.
Phone: +62-817-047-7165, e-mail: tris.indranarum@gmail.com
Copyright@2025 by The Korean Society for Medical Mycology. All right reserved.
This is an open-access article distributed under the terms of the Creative Commons Attribution Non-Commercial License (http://creativecommons.org/licenses/by-nc/3.0/), which permits unrestricted non-commercial use, distribution, and reproduction in any medium, provided the original work is properly cited. http://www.ksmm.org

Fig. 1. At the initial visit, the clinical presentation includes multiple erythematous to hyperpigmented patches on both cruris, with well-defined borders and fine white scales. The lesions have an active, elevated edge and central clearing, resembling tinea corporis.

Fig. 2. Direct microscopic examination of skin scrapings using KOH prep at 40× magnification shows thin septate hyphae, indicating superficial fungal infection.

for confirmation. This case report describes an unusual instance of *A. niger*-caused PCA in an immunocompetent woman, initially mistaken for tinea corporis. The report emphasizes the diagnostic challenges and the need to consider other fungal infections in atypical and persistent dermatoses[2].

CASE REPORT

A 27-year-old woman visited the dermatology outpatient department at Dr. Soetomo General Hospital with recurrent, itchy red patches on both lower limbs, lasting about two years. The lesions started on the right leg and gradually extended to the left. She described the rash as initially small, red patches she frequently scratched, causing excoriation and enlargement. Over time, the patches increased in number and size. Despite the chronicity, she denied systemic symptoms such as fever, malaise, cough, weight loss, or respiratory issues.

She previously saw a general practitioner a year ago and was empirically treated with oral ciprofloxacin and cetirizine without improvement. Later, a dermatologist prescribed oral antihistamines (mebhydroline 3 × 50 mg), oral corticosteroids (Dexamethasone 3 × 0.5 mg), oral griseofulvin (1 × 125 mg), and topical steroid cream, but the lesions persisted with minimal response over several months. Due to the refractory nature of the condition, she was referred to the tertiary care dermatology polyclinic for further assessment management.

The patient denied any prior trauma to the affected area, recent or past exposure to irritant chemicals, or use of over-the-counter topical medications. She has no significant medical history, including diabetes mellitus, hypertension, malignancy, or autoimmune conditions, and she also denies taking immunosuppressive drugs. Her social history indicates she previously worked as a pharmacist and is now unemployed. Residing in a rural area near agricultural fields, she may have been exposed to fungal spores in the general environment. There is no family history of similar skin issues or other chronic dermatologic conditions.

Dermatologic examination showed multiple patches on both cruris, mainly on the front and lateral sides of the right and left lower legs (Fig. 1). The lesions were erythematous to hyperpigmented, with clearly defined borders, covered with fine scales, and had slightly raised active edges. There were no pustules, ulceration, or signs of secondary bacterial infection noted.

Initial examination of skin scrapings with 20% potassium hydroxide (KOH) revealed thin septate hyphae, initially indicating tinea corporis (Fig. 2). To confirm the diagnosis, a fungal culture was conducted. The patient was prescribed oral griseofulvin 250 mg twice daily and urea 10% cream twice daily. She was also advised to refrain from manipulating the lesions and to return to the polyclinic for evaluation in two weeks.

At the 14-day follow-up, the patient reported slight improvement in the lesions, with some fading of erythema and a change to hyperpigmented patches. However, pruritus and scales persisted, especially with heat and sweating. Dermatological findings remained largely unchanged, showing persistent annular patches with scales. KOH exam revealed thin, septate hyphae. The fungal culture produced colonies that first appeared white, then turned black, with a white

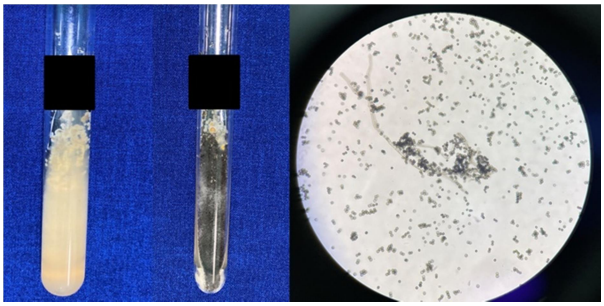

Fig. 3. Fungal culture on Sabouraud dextrose agar reveals *A. niger* colonies that initially appear white and turn black, with a white periphery. The colonies have a cottony to granular texture and a pale reverse surface. Microscopic analysis confirmed thin septate hyphae and spherical black conidia, which are characteristic of *A. niger* morphology.

periphery and a cottony to granular texture, and a pale reverse surface. The culture was grown on Sabouraud dextrose agar and incubated for 14 days. Microscopic analysis at 40× magnification showed thin, septate hyphae with globose black conidia, consistent with *Aspergillus niger* (Fig. 3). PCR testing was not available at the hospital. A punch skin biopsy was not performed.

A final diagnosis of PCA was established based on clinical appearance and culture results. The patient started on oral itraconazole 200 mg daily and continued topical 10% urea cream. She was advised to strictly avoid using any topical corticosteroids or unprescribed medications.

Follow-up at week 4 showed partial lesion resolution, with decreased erythema, patches, scales, and itching. KOH examination was negative for fungi at this point (Fig. 4). By week 8, there was notable clinical improvement, including the resolution of active edges, fewer patches and scales, hyperpigmentation, and no new lesions. The patient tolerated itraconazole well, without adverse effects. She continued to be monitored clinically, with no evidence of systemic spread or recurrence observed up to seven months later.

Fig. 4. Serial clinical follow-up of the lesions shows progress. (A) Week 4: Partial reduction in erythema, patches, and scales; (B & C) Week 8: Significant improvement with the active edges resolving, fewer patches and scales, residual post-inflammatory hyperpigmentation, and no new lesions after oral itraconazole therapy

DISCUSSION

PCA is a rare but clinically significant skin infection caused by direct inoculation of *Aspergillus* spp. into damaged skin. It primarily affects immunocompromised individuals; however, increasing evidence indicates that immunocompetent people are also at risk, especially in settings with high exposure and minor skin barrier disruptions. This case emphasizes a common yet often overlooked clinical scenario: PCA in an immunocompetent patient with chronic lesions that mimic superficial dermatophytosis. Healthcare providers should consider other fungal infections, particularly when the presentation is atypical or the condition persists despite treatment dermatoses.

Diagnosing cutaneous aspergillosis can be challenging because the lesions often resemble *tinea corporis*, with KOH tests revealing septate hyphae. However, these lesions typically do not respond to standard antifungal treatments. This reveals a key diagnostic limitation: although KOH microscopy is sensitive for detecting fungal elements, it cannot specify the fungal species. Fungal cultures are needed to identify the causative organism and determine appropriate treatment, but they take several days for growth and species identification. This delay complicates treatment, especially with non-

Copyright@2025 by The Korean Society for Medical Mycology

dermatophyte molds like *Aspergillus*. This diagnostic difficulty highlights the need to consider other mycoses, particularly in cases of chronic, treatment-resistant lesions, even in immunocompetent individuals.

The pathogen identified here, *A. niger*, is an uncommon but increasingly recognized cause of skin infections. Usually dismissed as a contaminant unless clinical signs strongly indicate infection, its consistent morphology and lack of other causes suggest it was truly pathogenic in this case. This report adds to the limited evidence of *A. niger* causing PCA in immune-competent individuals, emphasizing the growing number of cutaneous aspergillosis cases[3]. When evaluating differential diagnoses based on fungal results, *Aspergillus* species are primary considerations. While *A. niger* was identified through its characteristic black colonies and globose conidia, other species such as *A. fumigatus* and *A. flavus* are also relevant. *A. fumigatus* generally forms grey-black colonies, and *A. flavus* produces yellow-green colonies—both distinguishable from the black pigmentation observed here here[4,5].

Clinically, PCA can present in various forms; the primary lesion may evolve from a macule or papule to a nodule or granulated tissue. It can also originate from superficial, spreading macerated or ulcerative lesions, influenced by host factors and fungal virulence. In this case, the erythematous patches with fine scales and active borders resembled dermatophyte infections. Although dermoscopy is a useful tool in evaluating superficial fungal infections, its diagnostic specificity for PCA is limited because there are few established criteria[6].

Fungal culture remains the gold standard for identifying species. While it is often underused in resource-limited or busy clinical settings, it is essential for atypical, chronic, or treatment-resistant lesions. Once PCA is confirmed, prompt treatment is critical. Treatment options include systemic therapies such as polyenes like amphotericin B and its liposomal form, azole antifungals like voriconazole, posaconazole, and itraconazole, as well as echinocandins such as caspofungin and micafungin[5]. Surgical debridement is also advised as an additional antifungal treatment for severe cases to improve success rates. In this instance, a culture confirmed the presence of *A. niger*, allowing for the initiation of suitable systemic antifungal therapy. The patient responded positively to oral itraconazole, a triazole antifungal known to be effective against *Aspergillus* spp[4,7-8], highlighting the importance of species-specific therapy in managing fungal skin infections. The patient received oral itraconazole 200 mg/day for 8 weeks with favorable clinical outcome and KOH evaluation. Other case reports also showed good efficacy of oral itraconazole 200 mg/day for 12-13 weeks[9]. A first-line treatment of PCA has not been established, with the duration of treatment varying depending on the disease severity and immunity status[9].

This case contributes significantly to the clinical literature by illustrating that PCA—especially caused by *A. niger*—can mimic tinea corporis and persist despite standard antifungal treatments. The implications are substantial: clinicians should perform fungal culture in cases of atypical or recalcitrant superficial dermatoses, even in the absence of classical risk factors. Moreover, increased awareness of PCA's diverse presentations in immunocompetent individuals may lead to earlier intervention, reduce morbidity, and prevent progression to systemic disease[1].

In a broader sense, this report promotes a more detailed diagnostic approach to unusual or chronic dermatologic infections. It questions the idea that being immunocompetent automatically means protection from invasive or atypical mycoses and highlights the ecological fact that fungal pathogens—widespread in soil, air, and organic material—can take any chance to invade. This emphasizes the importance of dermatologists staying alert in diagnosis and using culture tests to confirm when the clinical situation diverges from the norm.

CONCLUSION

This case highlights the vital need to consider PCA as a possibility, even in immunocompetent patients exhibiting unusual or persistent, treatment-resistant skin conditions. Its resemblance to common superficial fungal infections like *tinea corporis* complicates diagnosis and treatment. Reporting a rare case of PCA caused by *A. niger* in an immunocompetent individual, this document enhances the limited knowledge on atypical cases and emphasizes the importance of fungal culture for accurate diagnosis. It underscores the need for clinicians to expand their differential diagnosis and provides valuable insights for earlier detection and proper management of PCA, aiming to reduce morbidity and improve outcomes.

ACKNOWLEDGEMENT

The authors thank the staff of the Mycology Division in the Department of Dermatology, Venereology, and Aesthetic at the Faculty of Medicine, Universitas Airlangga / Dr. Soetomo General Academic Hospital, for their assistance and guidance in patient treatment and the preparation of the manuscript.

CONFLICT OF INTEREST

In relation to this article, we declare that there is no conflict of interest.

ORCID

Presstisa Gifta Axelia: 0009-0003-8632-999X
Trisiswati Indranarum: 0009-0007-7485-0138
Linda Astari: 0009-0002-6921-8983
Evy Ervianti: 0000-0002-2443-014X

PATIENT CONSENT STATEMENT

The patient provided written informed consent for the publication and the use of her images.

REFERENCES

1. Avkan-Oğuz V, Çelik M, Satoglu IS, Ergon MC, Açan AE. Primary cutaneous aspergillosis in immunocompetent adults: three cases and a review of the literature. Cureus 2020;12:e6600
2. Tahir C, Garbati M, Nggada HA, Yawe EH, Abubakar AM. Primary cutaneous aspergillosis in an immunocompetent patient. J Surg Tech Case Rep 2011;3:94-96
3. Merad Y, Derrar H, Belmokhtar Z, Belkacemi M. *Aspergillus* genus and its various human superficial and cutaneous features. Pathogens 2021;10:1-17
4. Sheilaadji MU, Agusni I, Astari L, Anggraeni S, Widia Y, Ervianti E. Cutaneous aspergilosis caused by *Aspergillus flavus*: A case report. Berk Ilmu Kesehat Kulit dan Kelamin 2021;33:72-77
5. Zhang R, Zhang Y, Xu W, Han X, Zhao J. Primary cutaneous aspergillosis due to *Aspergillus fumigatus* in an immunocompetent patient with diabetes mellitus after tattooing: A case report and review of literature. Infect Drug Resist 2023;16:791-797
6. Tatara AM, Mikos AG, Kontoyiannis DP. Factors affecting patient outcome in primary cutaneous aspergillosis. Medicine (Baltimore) 2016;95:e3747
7. Nacea DI, Enescu DM, Tatar R, Orzan OA, Diaconu LS. New challenges in the diagnosis and treatment of primary cutaneous aspergillosis in extensive pediatric burns. J Fungi 2025;11:281
8. Park KD. Diagnosis and treatment of cutaneous aspergillosis. J Mycol Infect 2021;26:83-86
9. Nakashima K, Yamada N, Yoshida Y, Yamamoto O. Primary cutaneous aspergillosis. Acta Derm Venereol 2010;90:519-520

 Copyright@2025 by The Korean Society for Medical Mycology