LETTER TO THE EDITOR

J Mycol Infect 2018; 23(3): 79-81
pISSN:1226-4709, eISSN:2465-8278
http://dx.doi.org/10.17966/JMI.2018.23.3.79

JMI

Cutaneous Infection Due to *Mycobacterium chelonae*

Jun Suk Hong[1], Dong Won Lee[1], Moo Kyu Suh[1†], Gyoung Yim Ha[2], Jong Im Lee[3] and Soyoun Shin[4]

[1]Department of Dermatology, College of Medicine, Dongguk University, Gyeongju, Korea
[2]Department of Laboratory Medicine, College of Medicine, Dongguk University, Gyeongju, Korea
[3]Department of Pathology, College of Medicine, Dongguk University, Dongguk University, Gyeongju, Korea
[4]Korean Institute of Tuberculosis, Cheongju-si, Chungcheongbuk-do, Korea

Mycobacterium chelonae is an atypical rapidly growing Runyan Class IV *Mycobacterium*. It is widely distributed in soil and water, and causes skin infections after skin trauma or surgery[1-3]. Atypical mycobacteriosis can be difficult to diagnose because bacilli may not be obvious in tissue biopsies. Because pathogens differ in antimicrobial susceptibility, clinical suspicion of atypical mycobacterial infection should be confirmed through antimicrobial susceptibility testing and bac-

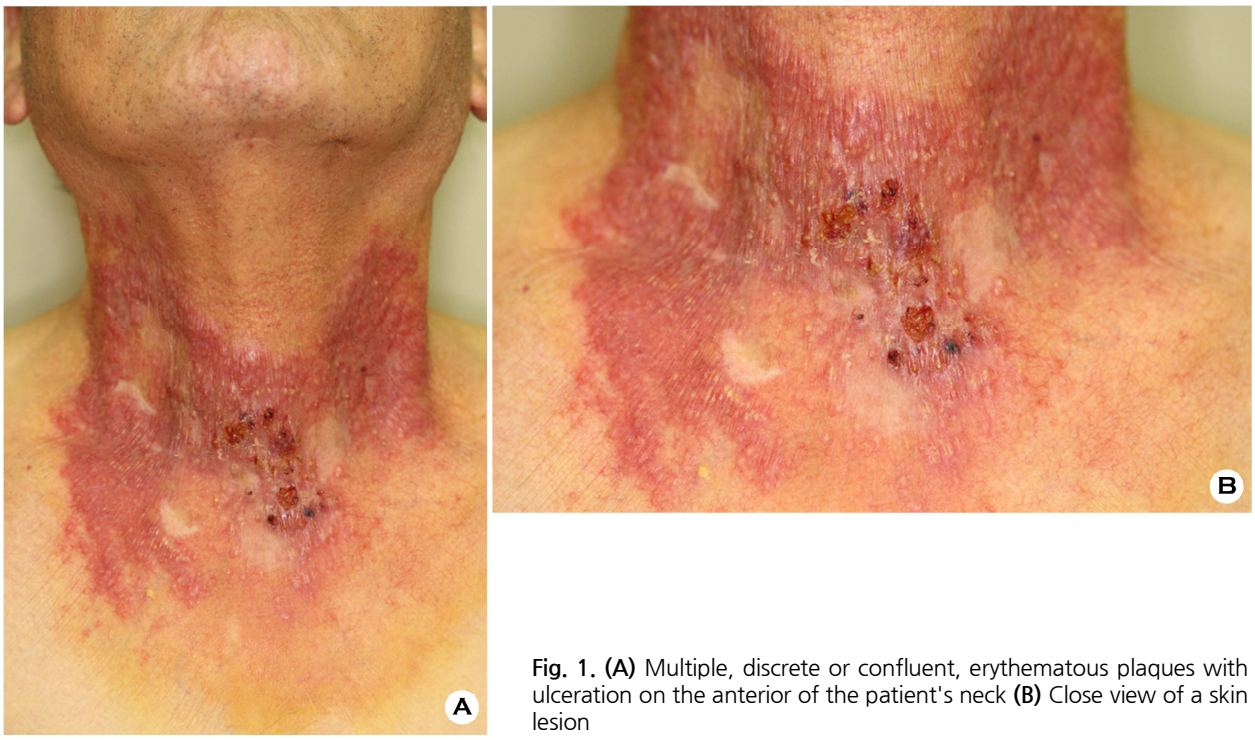

Fig. 1. (A) Multiple, discrete or confluent, erythematous plaques with ulceration on the anterior of the patient's neck **(B)** Close view of a skin lesion

Received: July 24, 2018 Revised: July 27, 2018 Accepted: August 30, 2018
†Corresponding: Moo Kyu Suh, Department of Dermatology, College of Medicine, Dongguk University, 87 Dongdae-ro, Gyeongju, Kyungbuk, 38067, Korea.
Phone: +82-10-3805-9223, Fax: +82-54-770-8378, e-mail: smg@dongguk.ac.kr
Copyright@2018 by The Korean Society for Medical Mycology. All right reserved.
This is an open-access article distributed under the terms of the Creative Commons Attribution Non-Commercial License (http://creativecommons.org/licenses/by-nc/3.0/), which permits unrestricted non-commercial use, distribution, and reproduction in any medium, provided the original work is properly cited. http://www.ksmm.org

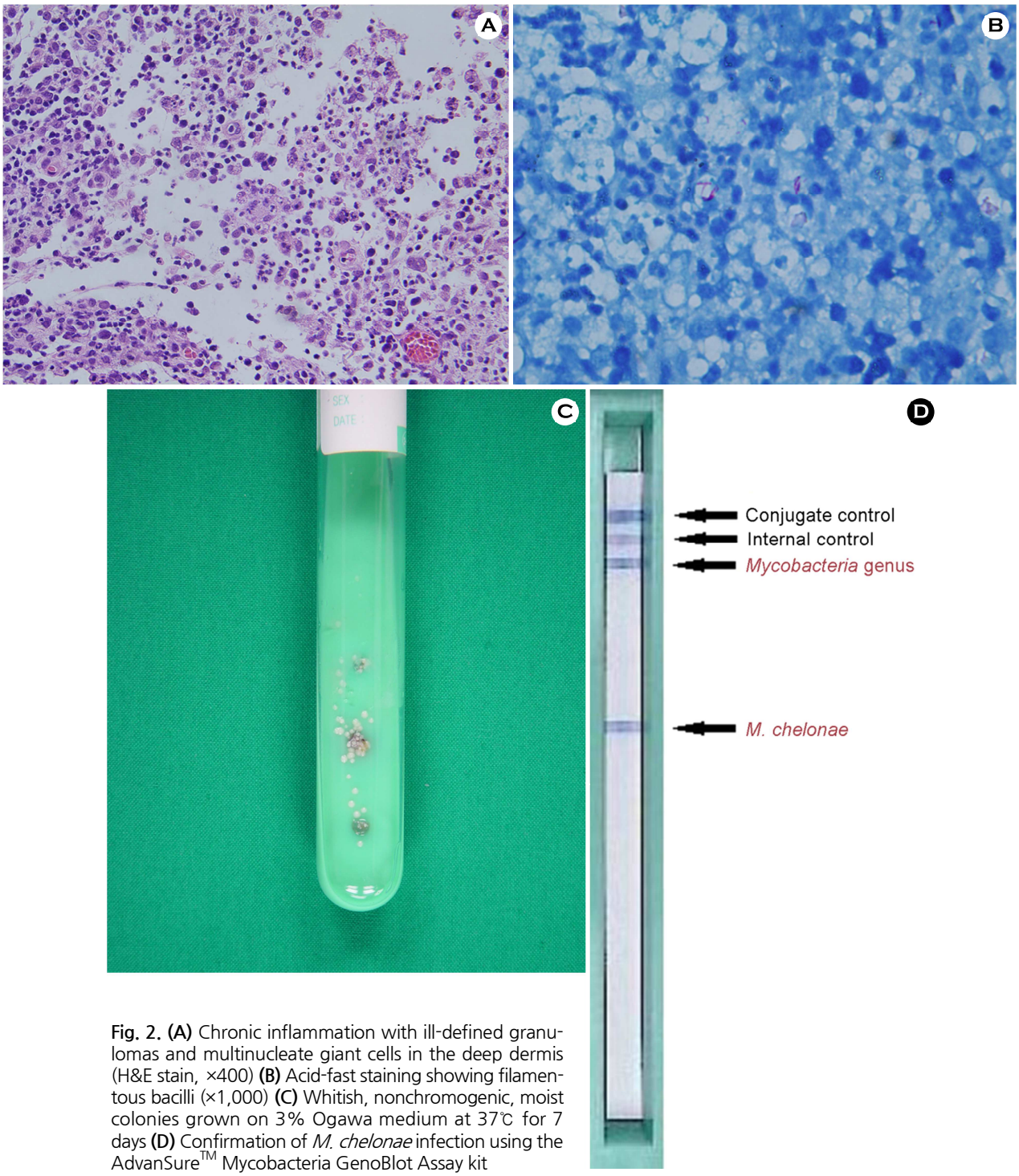

Fig. 2. (A) Chronic inflammation with ill-defined granulomas and multinucleate giant cells in the deep dermis (H&E stain, ×400) **(B)** Acid-fast staining showing filamentous bacilli (×1,000) **(C)** Whitish, nonchromogenic, moist colonies grown on 3% Ogawa medium at 37℃ for 7 days **(D)** Confirmation of *M. chelonae* infection using the AdvanSure™ Mycobacteria GenoBlot Assay kit

terial cultures[2,4]. Nine cases of *M. chelonae* infection have been reported in Korean dermatological literature previously, including cases of subcutaneous abscess after epidermal cyst incision and drainage, infection after injection of wrinkle fillers, acupuncture site infection, and infection after autologous fat transplantation. Only two of these cases did not have a trauma

Copyright@2018 by The Korean Society for Medical Mycology

history[5].

A 79-year-old man presented with multiple discrete or confluent pruritic, erythematous plaques with ulceration on the anterior neck that were of 3-weeks duration (Fig. 1A, B). He had a history of medication use for diabetes mellitus and no history of trauma-related skin lesions. There were no abnormal findings other than the cutaneous lesions. Histological evaluation indicated chronic inflammation with ill-defined granulomas and multinucleate giant cells in the deep dermis (Fig. 2A). Filamentous bacilli were observed on acid-fast staining (Fig. 2B), and 7-day cultures of skin biopsy specimens on 3% Ogawa medium yielded whitish, nonchromogenic, moist colonies (Fig. 2C). The microorganism was identified as *M. chelonae* by using the AdvanSure™ Mycobacteria GenoBlot Assay kit (LG Life Sciences, Seoul, Korea (Fig. 2D). Antimicrobial susceptibility testing showed sensitivity to amikacin, clarithromycin, and trimethoprim/sulfamethoxazole. The skin lesions completely resolved following the administration of 500 mg oral clarithromycin twice a day for 6 months. The cause of skin lesions in this 79-year-old man was diagnosed to be an *M. chelonae* infection based on clinical and pathological findings, positive skin culture, and genetic analysis. This rare case of *M. chelonae* infection is significant because of the absence of a history of skin trauma.

Key Words: Cutaneous infection, *Mycobacterium chelonae*

CONFLICTS OF INTEREST

In relation to this article, I declare that there is no conflict of interest.

REFERENCES

1. Kenneth ES, Oxman MN. Tuberculosis and infections with atypical mycobacteria, In: Wolff K, Goldsmith LA, Katz SI, Gilchrest BA, Paller AS, Leffel DJ, Dallas NA, editors. Fitzpatrick's dermatology in general medicine. 8th ed. New York: McGraw-Hill, 2012;2225-2241
2. Han XY, De I, Jacobson KL. Rapidly growing mycobacteria: clinical and microbiologic studies of 115 cases. Am J Clin Pathol 2007;128:612-621
3. Gonzales-Santiago TM, Drage LA. Nontuberculous mycobacteria: skin and soft tissue infections. Dermatol Clin 2015;33:563-577
4. Chung WK, Park GH, Chang SE, Lee MW, Choi JH, Moon KC, et al. A case of *Mycobacterium chelonae* infection with foreign body granuloma after injection of filter. Korean J Dermatol 2008;46:1521-1525
5. Ahn HH, Park SD, Kim KM, Park CJ, Kim HU, Kim JP, et al. Infectious skin diseases, In: Textbook of dermatology. 6th ed. Seoul: Medbook, 2014;409-412