CASE REPORT
J Mycol Infect 2024; 29(2): 78-82
pISSN:1226-4709, eISSN:2465-8278
https://dx.doi.org/10.17966/JMI.2024.29.2.78

JMI

Unusual Presentation of Chromoblastomycosis Masquerading as Cutaneous Abscess on the Back: A Case Report

Hoon Choi, Jun Ho Kwak, In Ho Bae, Bong Seok Shin, Min Sung Kim and Chan-Ho Na†

Department of Dermatology, Chosun University College of Medicine, Gwangju, Korea

Chromoblastomycosis, a chronic cutaneous mycosis caused by pigmented fungi, is typically associated with trauma in the exposed parts of the body. We report a 68-year-old male farmer diagnosed with chromoblastomycosis clinically mimicking a cutaneous abscess on the back, an unusual location. Histopathological and mycological examination identified *Fonsecaea pedrosoi*. Treatment with itraconazole and cryotherapy showed improvement after 4 months. High suspicion index and biopsy are imperative for early diagnosis of chromoblastomycosis. This case adds to the limited cases reported in Korea, emphasizing the importance of considering chromoblastomycosis in diverse clinical presentations.

Key Words: Chromoblastomycosis, *Fonsecaea pedrosoi*, Fungus

INTRODUCTION

Chromoblastomycosis is a chronic and progressive granulomatous cutaneous mycosis caused by pigmented fungi. Fungal inoculation typically occurs at the site of traumatic skin injury with lesions manifesting weeks to months after trauma. The infection commonly occurs in the exposed parts of the body, such as the lower and upper limbs[1-3]. Clinical presentation includes the development of nodules and verrucous plaques that eventually undergo ulceration[4]. Chromoblastomycosis is most prevalent in tropical and subtropical regions, but only a few cases have been reported in Korea[5,6]. We report a 68-year-old man with chromoblastomycosis, notable for its occurrence in an unusual area, such as the back, with skin lesions resembling a cutaneous abscess.

CASE REPORTS

A 68-year-old male farmer presented with two asymptomatic erythematous nodules on the left part of the upper back that had been present for 7 months (Fig. 1). His past medical history was unremarkable and there was no history of trauma. He was earlier diagnosed as a case of cutaneous abscess at another clinic and underwent incision and drainage with empirical antibiotic therapy. However, the lesions continued to persist. Consequently, a punch biopsy was performed to rule out infectious disease. Histopathological examination revealed hyperkeratosis, parakeratosis, marked acanthosis, pseudoepitheliomatous epidermal hyperplasia, and intraepidermal microabscesses in the epidermis. A lichenoid granulomatous inflammatory pattern was observed in the dermis with the presence of neutrophilic microabscesses in the granulomatous area (Fig. 2A). Additionally, there

Received: March 4, 2024 Revised: March 28, 2024 Accepted: April 8, 2024
†Corresponding: Chan-Ho Na, Department of Dermatology, Chosun University Hospital, Pilmundaero 365, Dong-gu, Gwangju 61453, Korea.
Phone: +82-62-220-3130, Fax: +82-62-222-3215, e-mail: chna@chosun.ac.kr
Copyright@2024 by The Korean Society for Medical Mycology. All right reserved.
This is an open-access article distributed under the terms of the Creative Commons Attribution Non-Commercial License (http://creativecommons.org/licenses/by-nc/3.0/), which permits unrestricted non-commercial use, distribution, and reproduction in any medium, provided the original work is properly cited. http://www.ksmm.org

Fig. 1. Two erythematous bean to coin-sized abscesses on the left upper back

were prominent, golden-brown thick-walled, ovoid spores, resembling "copper pennies" (Fig. 2B). The presence of fungi was confirmed by Grocott's methenamine silver (GMS) and Periodic acid-Schiff (PAS) staining (Fig. 2 C and D). Two weeks later, colonies were observed on Sabouraud's dextrose agar (SDA) at room temperature. The colonies were dark green, and the reverse view was black. Microscopic examination of colonies cultured in SDA and stained with lactophenol-cotton blue revealed erect, septate, and sympodial conidiophores. The distal ends of the conidiophores were slightly swollen to form single-celled conidia, that became branched (Fig. 3 A and B). *Fonsecaea pedrosoi* was identified based on the typical histomorphological characteristics and fungal culture. Following the diagnosis of chromoblastomycosis due to *F. pedrosoi*, the patient was prescribed itraconazole 200 mg daily, topical isoconazole, and cryotherapy with liquid nitrogen. After 4 months of treatment, the lesions showed improvement.

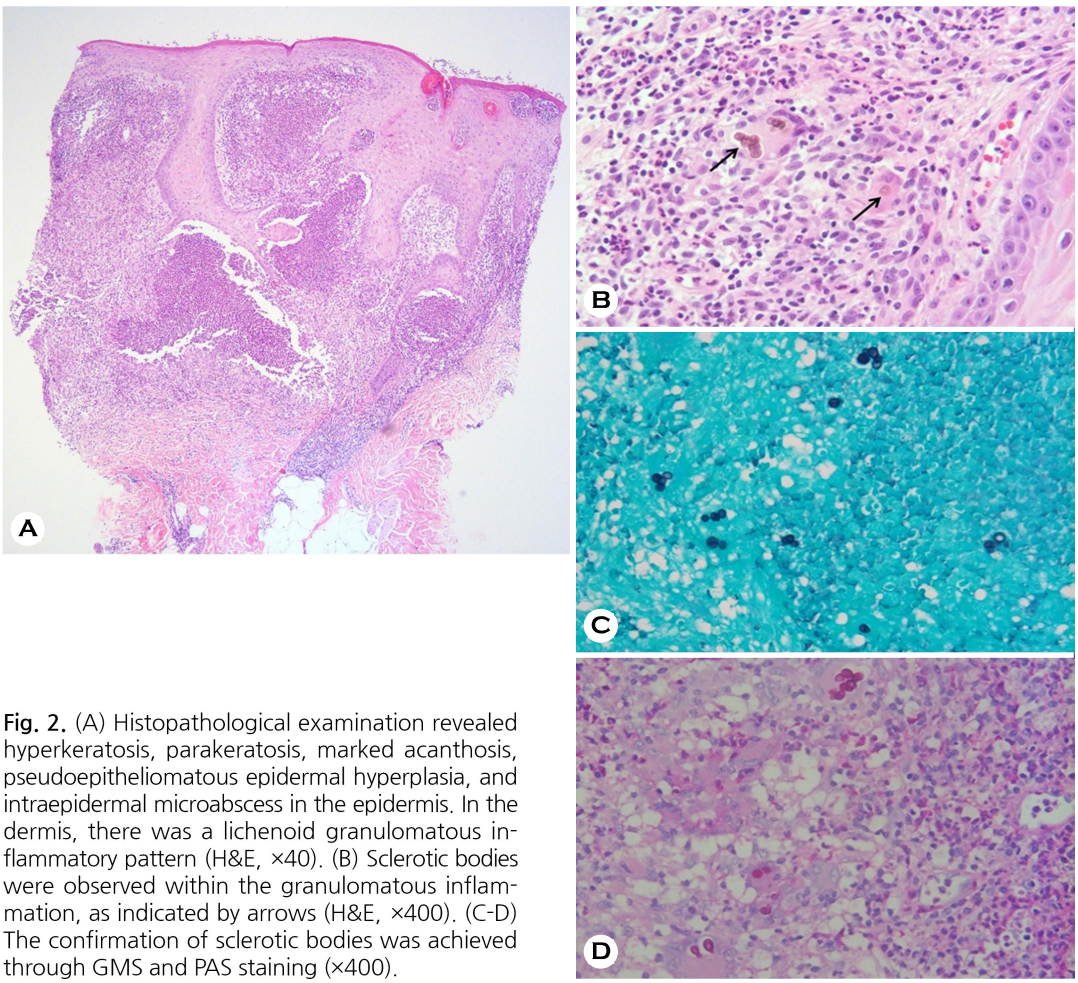

Fig. 2. (A) Histopathological examination revealed hyperkeratosis, parakeratosis, marked acanthosis, pseudoepitheliomatous epidermal hyperplasia, and intraepidermal microabscess in the epidermis. In the dermis, there was a lichenoid granulomatous inflammatory pattern (H&E, ×40). (B) Sclerotic bodies were observed within the granulomatous inflammation, as indicated by arrows (H&E, ×400). (C-D) The confirmation of sclerotic bodies was achieved through GMS and PAS staining (×400).

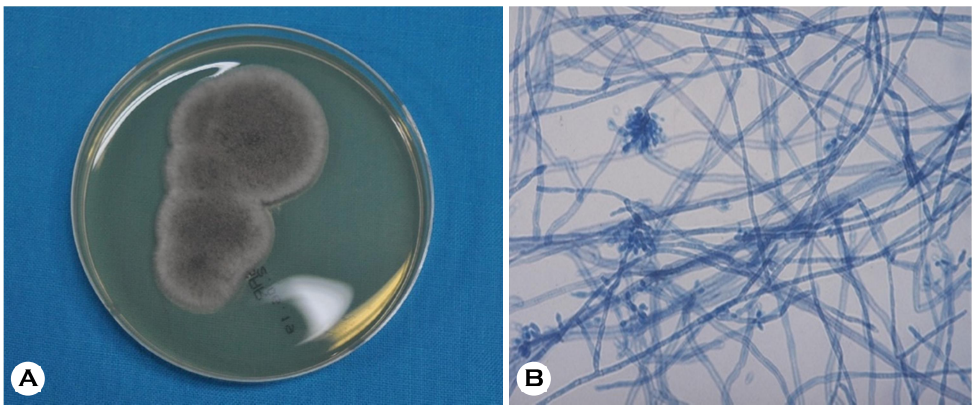

Fig. 3. (A) *F. pedrosoi* cultured in Sabouraud's dextrose agar (B) Erect, conidial and symbiotic conidium, with the conidium tip slightly swollen to form single-celled conidia that become branched

Table 1. Previously published cases of chromoblastomycosis in Korea

Case No.	Reference	Sex	Age	Location	Lesion	Causative fungi	Diagnostics for identification of causative species	Treatment
1	Suh et al. (1996)[15]	M	58	Wrist	Plaque	*Fonsecaea pedrosoi*	Fungal culture, microscopy	ILI APB
2	Kim et al. (1997)[16]	M	68	Hand	Verrucous plaque	*Fonsecaea pedrosoi*	Fungal culture, microscopy	Oral ICZ
3	Kim et al. (2000)[17]	F	65	Arm	Annular erythematous plaque	*Fonsecaea pedrosoi*	Fungal culture, microscopy	Topical APB
4	Kang et al. (2002)[18]	F	56	Hands	Erythematous ulceration	*Fonsecaea pedrosoi*	Fungal culture, microscopy	Oral ICZ, surgical excision
5	Lee et al. (2003)[19]	M	54	Leg	Plaque	*Fonsecaea pedrosoi*	Fungal culture, microscopy	Oral terbinafine
6	Jun et al. (2004)[8]	F	52	Abdomen	Erythematous verrucous plaque	*Rhinocladiella aquaspersa*	Fungal culture, microscopy	Oral ICZ, surgical excision
7	Park et al. (2005)[14]	F	37	Breast	Verrucous plaques and nodules	*Phialophora verrucosa*	Fungal culture, microscopy	IV APB, oral 5-flucytosine
8	Son et al. (2010)[7]	M	43	Leg	Verrucous plaque	*Phialophora richardsiae*	Fungal culture, microscopy, molecular analysis	Oral ICZ, terbinafine
9	Kim et al. (2014)[20]	F	61	Forearm	Erythematous plaque	*Fonsecaea monophora*	Fungal culture, microscopy, molecular analysis	Local heat therapy, topical terbinafine
10	Lee et al. (2017)[13]	M	65	Forearm	Erythematous plaque	*Fonsecaea monophora*	Molecular analysis	Oral ICZ
Present case	Choi et al. (2024)	M	68	Back	Erythematous nodules	*Fonsecaea pedrosoi*	Fungal culture, microscopy	Cryotherapy, oral ICZ, topical isoconazole

APB, amphotericin B; ICZ, itraconazole; ILI, intralesional injection; IV, intravenous

Copyright@2024 by The Korean Society for Medical Mycology

DISCUSSION

Chromoblastomycosis is a chronic cutaneous and subcutaneous fungal infection primarily caused by melanized fungi. These fungi are characterized by their brown pigmentation due to the production of melanin. The fungi often reside in the soil, wood, and plants. Chromoblastomycosis occurs worldwide, but is more prevalent in tropical and temperate regions, predominantly affecting individuals with occupational exposure to the fungi in the environment[6]. At least 41 species of fungi have been reported to cause chromoblastomycosis[5]. In Korea, a few types such as *F. monophora*, *F. pedrosoi*, *Phialophora richardsiae*, *Phialophora verrucosa*, and *Rhinocladiella aquaspersa*, have been reported, and the number of cases reported in the literature is small compared to other countries[5-8].

Chromoblastomycosis is indeed considered an occupational disease, particularly prevalent among agricultural workers[1]. The infection is attributed to the invasion of the skin by the fungus at the site of trauma, leading to the development of skin lesions. These lesions typically occur in the exposed areas that are unprotected by clothing. The arms, and especially the lower extremities are the most commonly involved sites in cases of chromoblastomycosis[1-3]. However, not all patients may recall a specific history of trauma at the site of the lesion[7]. This may be attributed to a prolonged latency period[9].

The lesions can manifest in various forms, including nodular, tumorous, verrucous, cicatricial, and plaque lesions[4]. The diverse nature of these skin lesions may pose a diagnostic challenge. Thus, histological and mycologic examinations are imperative to identify the fungal infection. The typical histological characteristics of chromoblastomycosis are pseudoepitheliomatous epidermal hyperplasia, intraepidermal microabscesses, and mixed granuloma. Dark brown, ovoid, or spherical spores resembling "copper pennies" indicate melanized fungi as the causative pathogen. This appearance can be easily visualized by Hematoxylin and Eosin staining. Additionally, special stains such as GMS and PAS can help support the diagnosis by highlighting the fungal elements[10]. These histopathological features are crucial for distinguishing chromoblastomycosis from other skin conditions.

Initial identification of putative species in chromoblastomycosis is often performed using mycological and morphological methods. The species of *Fonsecaea* display erect, septate, and sympodial conidiophores that are extensively branched at their apices. *Phialophora verrucosa* has a monomorphic morphology characterized by flask-shaped phialides. *Rhinocladiella aquaspersa* features erect, brown, septate conidiophores, bearing conidia at their terminal parts[11]. These traditional methods of examining morphological characteristics are time-consuming. However, the advances in diagnostic technology have enabled rapid identification of the fungal species. Molecular techniques, such as gene sequencing analysis are used for the definitive identification of fungal species[12,13]. A limitation of this study is that molecular analysis for identifying the causative fungus was not performed. The morphological characteristics observed in this case were consistent with *Fonsecaea* species. Although *F. monophora* and *F. pedrosoi* are morphologically very similar, *F. pedrosoi* was identified as the causative agent in this case based on the fact that *F. pedrosoi* generally has slightly shorter conidial chains and slightly longer denticles than *F. monophora*[12].

To the best of our knowledge, 10 cases of chromoblastomycosis have been reported in Korea (Table 1). In these cases, the lesions predominantly manifested in the exposed parts of the body, exhibiting diverse clinical presentations. Our patient presented with a nodule resembling a cutaneous abscess, obscuring the diagnosis. Notably, only two previous cases with lesions in the non-exposed areas (abdomen and breast) have been reported in Korea[8,14]. This case represents the first instance of chromoblastomycosis caused by *F. pedrosoi* in non-exposed areas. Despite the denial of any history of trauma, the possibility of chromoblastomycosis was considered, especially given his occupation as a farmer.

In conclusion, we suggest that the possibility of chromoblastomycosis should be considered in individuals presenting with skin lesions, especially those with an occupational background as farmers. Early recognition and diagnosis are pivotal for effective management, and conducting a biopsy, as exemplified in this case, is a crucial step for accurate diagnosis. The authors report this rare and interesting case along with a review of pertinent literature.

ACKNOWLEDGEMENT

The authors declare that there are no acknowledgments.

CONFLICT OF INTEREST

In relation to this article, we declare that there is no conflict of interest.

ORCID

Hoon Choi: 0000-0001-8514-3550

Jun Ho Kwak: 0000-0002-1341-7986
In Ho Bae: 0000-0002-9166-4050
Bong Seok Shin: 0000-0001-9618-1763
Min Sung Kim: 0000-0002-8102-6653
Chan-Ho Na: 0000-0001-5259-5382

PATIENT CONSENT STATEMENT

The patient provided written informed consent for the publication and the use of his images.

REFERENCES

1. Verma S, Thakur BK, Raphael V, Thappa DM. Epidemiology of subcutaneous mycoses in northeast India: A retrospective study. Indian J Dermatol 2018;63:496-501
2. Minotto R, Bernardi CD, Mallmann LF, Edelweiss MI, Scroferneker ML. Chromoblastomycosis: a review of 100 cases in the state of Rio Grande do Sul, Brazil. J Am Acad Dermatol 2001;44:585-592
3. Correia RT, Valente N, Criado PR, Martins JE. Chromoblastomycosis: study of 27 cases and review of medical literature. An Bras Dermatol 2010;85:448-454
4. Queiroz-Telles F, Esterre P, Perez-Blanco M, Vitale RG, Salgado CG, Bonifaz A. Chromoblastomycosis: an overview of clinical manifestations, diagnosis and treatment. Medical Mycology 2009;47:3-15
5. Passero LFD, Cavallone IN, Belda W Jr. Reviewing the Etiologic Agents, Microbe-Host Relationship, Immune Response, Diagnosis, and Treatment in Chromoblastomycosis. J Immunol Res 2021;2021:9742832
6. Queiroz-Telles F. Chromoblastomycosis: a neglected tropical disease. Rev Inst Med Trop Sao Paulo 2015;7(Suppl 19):46-50
7. Son YM, Kang HK, Na SY, Lee HY, Baek JO, Lee JR, et al. Chromoblastomycosis caused by *Phialophora richardsiae*. Ann Dermatol 2010;22:362-366
8. Jun JB, Park JY, Kim DW, Suh SB. Chromoblastomycosis Caused by *Rhinocladiella aquaspersa*. Korean J Med Mycol 2004;9:117-122
9. Brandt ME, Warnock DW. Epidemiology, clinical manifestations, and therapy of infections caused by dematiaceous fungi. J Chemother 2003;15(Suppl 2):36-47
10. Elder D, Elenitsas R, Murphy GF, Rosenbach M, Rubin AI, Seykora JT, et al. Fungal diseases. In: Hinshaw MA, Longley B.J, editors. Lever's dermatopathology: histopathology of the skin. 12th ed. Singapore: Wolters Kluwer, 2022: 729
11. Queiroz-Telles F, de Hoog S, Santos DW, Salgado CG, Vicente VA, Bonifaz A, et al. Chromoblastomycosis. Clin Microbiol Rev 2017;30:233-276
12. De Hoog GS, Attili-Angelis D, Vicente VA, Van Den Ende AH, Queiroz-Telles F. Molecular ecology and pathogenic potential of *Fonsecaea* species. Med Mycol 2004;42: 405-416
13. Lee WJ, Eun DH, Park JH, Jang YH, Lee SJ, KIM DW, et al. A case of *Fonsecaea monophora* infection. Korean J Med Mycol 2017;22:141-143
14. Park SG, Oh SH, Suh SB, Lee KH, Chung KY. A case of chromoblastomycosis with an unusual clinical manifestation caused by *Phialophora verrucosa* on an unexposed area: treatment with a combination of amphotericin B and 5-flucytosine. Br J Dermatol 2005;152:560-564
15. Suh MK, Sung YO, Yoon KS, Ha GY, Kim JR. A case of chromoblastomycosis caused by *Fonsecaea pedrosoi*. Korea J Dermatol 1996;34:832-836
16. Kim HU, Son GY, Ihm CW. A case of chromoblastomycosis showing a good response to itraconazole. Ann Dermatol 1997;9:51-54
17. Kim SW, Oh SH, Choi SK, Lee YH, Yoon JH, Bang YJ, et al. Chromoblastomycosis treated with occlusive dressing of amphotericin B cream. Korean J Med Mycol 2000;5:144-149
18. Kang NG, Suh MK, Park SG, Song KY, Kim TH. A case of chromomycosis showing ulcerative lesions on dorsa of hands. Korea J Dermatol 2002;40:174-176
19. Lee CW, Sim SJ, Song KH, Kim KH. A case of chromoblastomycosis treated with terbinafine. Korean J Med Mycol 2003;8:26-29
20. Kim BS, Choi JH, Sohng SH, Shin DH, Choi JS, Suh MK. Chromoblastomycosis caused by *Fonsecaea monophora*. Korean J Med Mycol 2014;19:18-24

Copyright@2024 by The Korean Society for Medical Mycology