CASE LETTER
J Mycol Infect 2024; 29(1): 36-38
pISSN:1226-4709, eISSN:2465-8278
https://dx.doi.org/10.17966/JMI.2024.29.1.36

JMI

A Case of Bilateral Cutaneous Alternariosis of the Lower Legs

Chan Hui Jang, Doo Rae Cha, Jin Soo Kim, Do Won Kim and Ho Seok Suh†

Department of Dermatology, Ulsan University Hospital, University of Ulsan College of Medicine, Ulsan, Korea

An 80-year-old woman presented with a 6-month history of bilateral painful erythematous exudative patches with pustules on her lower legs. The patient is a farmer who had no relevant medical or trauma history. Under the clinical impression of chronic pruritus without primary skin lesions, topical corticosteroids were administered to the lower legs for several years; however, no improvement was observed, and new lesions gradually emerged.

Physical examination revealed painful bilateral erythematous exudative patches studded with multiple pustules and black grains on the lower limbs (Fig. 1A, B). Laboratory examinations revealed a high C-reactive protein level (2.48 mg/dL), and no other specific findings were observed. Histopathological examination revealed epidermal necrosis, abscess formation within the epidermis and dermis, and densely mixed inflammatory cell infiltration with lymphoplasmacytic cells and neutrophils in the dermis (Fig. 2A, B). Periodic acid-Schiff staining was negative. Tissue cultures for bacteria and mycobacteria were also negative. However, fungal cultures showed cotton-like gray-white colonies with a dark-brown underside, and lactophenol cotton blue staining confirmed septate hyphae and long chains of rounded conidia (Fig. 2C, D). Species were identified by matrix-assisted laser desorption /ionization time-of-flight mass spectrometry (Microflex LT, Bruker Daltonics, Bremen, Germany). The patient was diagnosed with cutaneous alternariosis caused by *Alternaria alternata* and received oral itraconazole treatment, which led to clinical improvement.

Fig. 1. (A), (B) Bilateral reddish edematous exudative patches with black grains and pustules on the lower limbs

Alternaria, a pigmented filamentous fungus, is widely distributed in nature[1]. *Alternaria* includes various species such as *A. alternata*, *A. infectoria*, *A. tenuissima*, *A. alternatum*, and *A. tenuis*[2], which can be identified using molecular biology methods[1,2]. *Alternaria* grows relatively rapidly and mature in 5 days. *Alternaria* usually does not cause infection in patients with immunocompetent status[3]. Risk factors for alternariosis include trauma, long-term use of systemic corticosteroids, Cushing's syndrome, and immunocompromised status[2,4]. *Alternaria* infection along the aerosol route was reported in patients with immunocompetent status and a history of using intranasal corticosteroid spray[5]. Similarly, Machet et al.[4] reported cutaneous alternariosis associated with topical

Received: December 22, 2023 Revised: January 30, 2024 Accepted: February 5, 2024
†Corresponding: Ho Seok Suh, Department of Dermatology, Ulsan University Hospital, University of Ulsan College of Medicine, 25, Daehakbyeongwon-ro, Dong-gu, Ulsan 44033, Korea.
Phone: +82-52-250-7090, Fax: +82-52-250-8071, e-mail: derma@uuh.ulsan.kr
Copyright@2024 by The Korean Society for Medical Mycology. All right reserved.
This is an open-access article distributed under the terms of the Creative Commons Attribution Non-Commercial License (http://creativecommons.org/licenses/by-nc/3.0/), which permits unrestricted non-commercial use, distribution, and reproduction in any medium, provided the original work is properly cited. http://www.ksmm.org

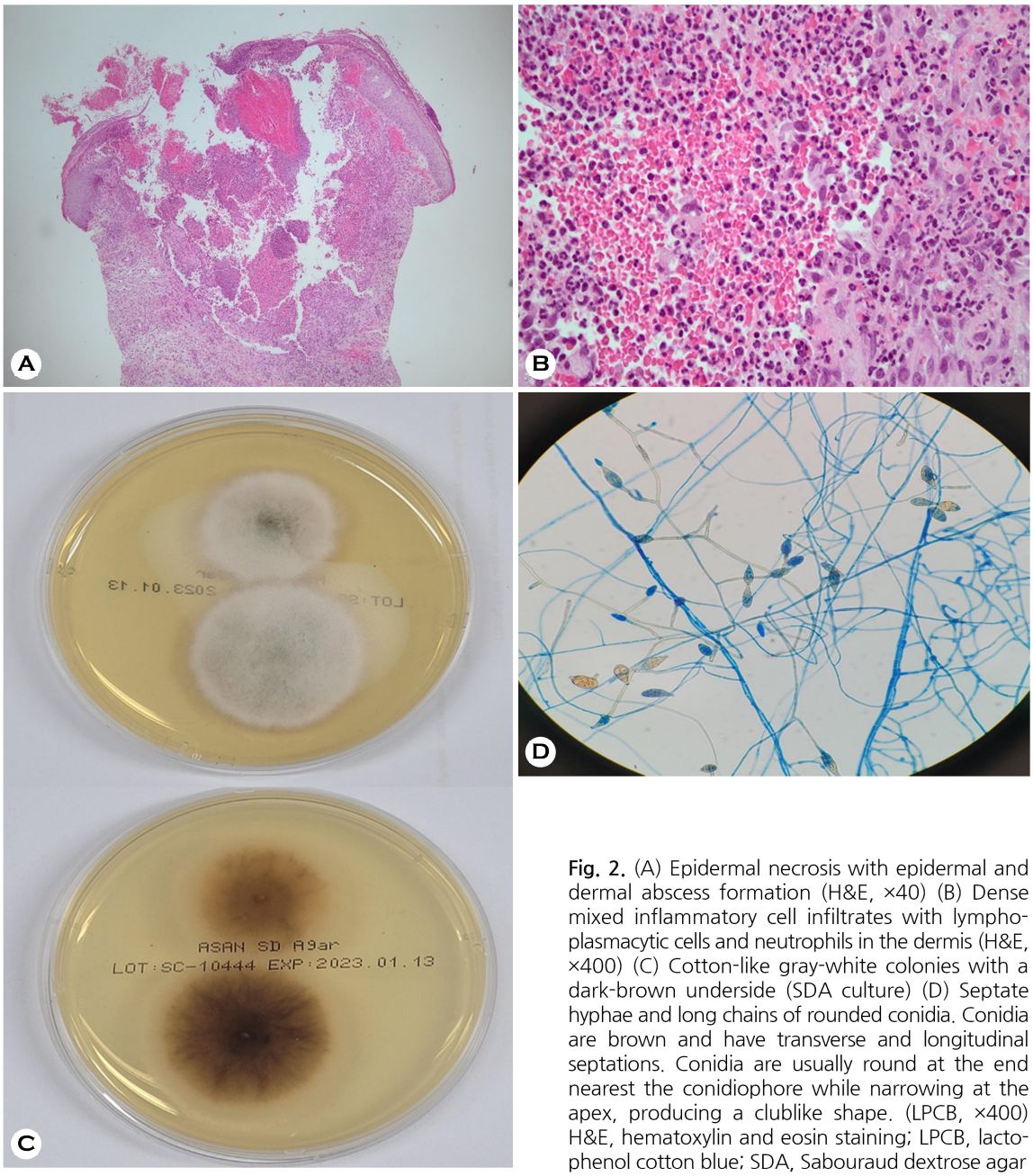

Fig. 2. (A) Epidermal necrosis with epidermal and dermal abscess formation (H&E, ×40) (B) Dense mixed inflammatory cell infiltrates with lymphoplasmacytic cells and neutrophils in the dermis (H&E, ×400) (C) Cotton-like gray-white colonies with a dark-brown underside (SDA culture) (D) Septate hyphae and long chains of rounded conidia. Conidia are brown and have transverse and longitudinal septations. Conidia are usually round at the end nearest the conidiophore while narrowing at the apex, producing a clublike shape. (LPCB, ×400) H&E, hematoxylin and eosin staining; LPCB, lactophenol cotton blue; SDA, Sabouraud dextrose agar

corticosteroids and proposed that cutaneous fragility induced by topical corticosteroids increases the possibility of percutaneous inoculation of *Alternaria* from the environment. Clinical manifestations of cutaneous alternariosis mainly occur on the lower extremities and may present as localized, painful, and erythematous scaly papules, plaques, or nodules[1]. These lesions can progress to crust, erosions, or ulcerations[3]. Alternariosis is diagnosed by histopathological and mycological analyses of a skin biopsy. Histopathological observations revealed epidermal hyperplasia with intraepidermal abscesses and a dense inflammatory cell infiltrate with fungal elements in the dermis. Mycological culture tests revealed white brown mold colonies composed of septate hyphae and chains of conidia with transverse and longitudinal septations. Cutaneous alternariosis usually has a good prognosis with appropriate treatment[2]. Treatment options include topical

or systemic antifungal agents, and surgical resection can be considered if necessary[3]. In this case, the clinical features improved after oral administration of 100 mg itraconazole twice daily for 20 weeks.

Healthy older adults with prolonged use of topical steroids may have an increased risk of fungal infections[4]. In addition, even if the patient had no history of skin disease, severe itching may have resulted in chronic irritation or trauma to the skin, which can be a risk factor for fungal infections. To our knowledge, this is the first report of bilateral cutaneous alternariosis in a patient with an immunocompetent status with no history of skin diseases or long-term steroid use. Therefore, if pruritic or eczematous lesions do not respond to appropriate treatment, a skin biopsy may be necessary to confirm the diagnosis. If symptoms change from pruritus to pain, the possibility of cutaneous infection, including bacterial or fungal infection, should be considered.

Key Words: Alternariosis, Itraconazole, Topical corticosteroids

ACKNOWLEDGEMENT

The authors declare no acknowledgments.

CONFLICT OF INTEREST

In relation to this article, we declare that there is no conflict of interest.

ORCID

Chan Hui Jang: 0009-0000-9738-3295
Doo Rae Cha: 0000-0003-2820-1448
Jin Soo Kim: 0000-0001-9595-8286
Do Won Kim: 0000-0001-6632-1374
Ho Seok Suh: 0000-0002-6781-5429

PATIENT CONSENT STATEMENT

The patient provided written informed consent for the publication and the use of her images.

REFERENCES

1. Colosi IA, Crisan M, Toc DA, Colosi HA, Georgiu C, Sabou M, et al. First reported case of a clinically nonresponsive-to-itraconazole *Alternaria alternata* isolated from a skin infection of a nonimmunocompromised patient from Romania. J Fungi (Basel) 2023;9:839
2. Jebari M, Mtibaa L, Abid R, Hannechi S, Souid H, Battikh R, et al. Unusual location of cutaneous alternariosis in an immunocompetent patient. IDCases 2021;27:e01356
3. Yasui M, Hattori M, Ikegami N, Kaga M, Ogawa Y, Hiruma M. A case of alternariosis successfully treated with local hyperthermia. Mycoses 2011;54:e623-626
4. Machet L, Jan V, Machet MC, Vaillant L, Lorette G. Cutaneous alternariosis: Role of corticosteroid-induced cutaneous fragility. Dermatology 1996;193:342-344
5. Chang GH, Wang WH. Intranasal fungal (*Alternaria*) infection related to nasal steroid spray. Am J Otolaryngol 2013;34:743-745

Copyright@2024 by The Korean Society for Medical Mycology