CASE REPORT
J Mycol Infect 2024; 29(1): 24-28
pISSN:1226-4709, eISSN:2465-8278
https://dx.doi.org/10.17966/JMI.2024.29.1.24

JMI

The First Case of Phaeohyphomycosis Caused by *Exophiala xenobiotica* in an Immunocompetent Patient in Korea

Jung Eun Seol[1], Seung Hee Jang[1], Hee Weon Yun[1], Sang Woo Ahn[1], Jeong Hwan Shin[2] and Hyojin Kim[1†]

[1]Department of Dermatology, College of Medicine, Inje University, Busan, Korea
[2]Department of Laboratory Medicine, College of Medicine, Inje University, Busan, Korea

Phaeohyphomycosis is a rare fungal infection caused by dematiaceous fungi commonly associated with immunocompromised patients. *Exophiala (E.)* species are linked to phaeohyphomycosis, and in Korea, *E. dermatitidis*, *E. jeanselmei*, and *E. salmonis* were previously isolated from affected patients. Here, we describe a unique instance of phaeohyphomycosis in an immunocompetent patient attributed to *E. xenobiotica*. A 75-year-old female presented with an asymptomatic erythematous crusted subcutaneous nodule on the dorsum of her left-hand. Her past medical history was negative for immunosuppression or trauma to the affected area. Histopathological examination revealed suppurative granulomatous infiltration, with septate hyphae and spores detected by periodic acid-Schiff staining in the dermis. A fungal culture made from a tissue sample revealed *E. xenobiotica*, with subsequent confirmation through phylogenetic analyses of the internal transcribed spacer (ITS) and large subunit regions (LSU) of ribosomal ribonucleic acid (rRNA). The patient was diagnosed with phaeohyphomycosis and underwent a 3-week course of terbinafine, followed by 7 weeks of fluconazole. These treatments significantly improved the lesion. To our knowledge, this is the first reported case of phaeohyphomycosis caused by *E. xenobiotica* in Korea.

Key Words: *Exophiala*, Invasive fungal infections, Mycoses, Phaeohyphomycosis

INTRODUCTION

Phaeohyphomycosis is a rare infectious disease caused by dematiaceous fungi. The condition commonly affects cutaneous or subcutaneous skin layers and, less commonly, visceral organs. Although these dematiaceous fungi are generally nonpathogenic to humans, they can produce opportunistic infections in immunocompromised individuals[1]. Phaeohyphomycoses are characterized by melanin, which is responsible for the spores' dark pigmentation, and conidia, which likely function as a virulence factor[2].

Most phaeohyphomycosis cases are caused by *Exophiala (E.) jeanselmei* and *Wangiella dermatitidis*, although other, less-common species have been implicated[3]. In Korea, *E. jeanselmei* is the most common causative species, followed by *E. dermatitidis*, *Dreschslera dematioidea*, *Phoma* species, and *Alternaria* species[4].

E. xenobiotica can cause phaeohyphomycosis[5]; however,

Received: January 20, 2024 Revised: January 23, 2024 Accepted: January 29, 2024
†Corresponding: Hyojin Kim, Department of Dermatology, Busan Paik Hospital, College of Medicine, Inje University, 75 Bokji-ro, Busanjin-gu, Busan, 47392, Korea.
Phone: +82-51-890-6135, Fax: +82-51-890-5845, e-mail: derma09@hanmail.net
Copyright@2024 by The Korean Society for Medical Mycology. All right reserved.
This is an open-access article distributed under the terms of the Creative Commons Attribution Non-Commercial License (http://creativecommons.org/licenses/by-nc/3.0/), which permits unrestricted non-commercial use, distribution, and reproduction in any medium, provided the original work is properly cited. http://www.ksmm.org

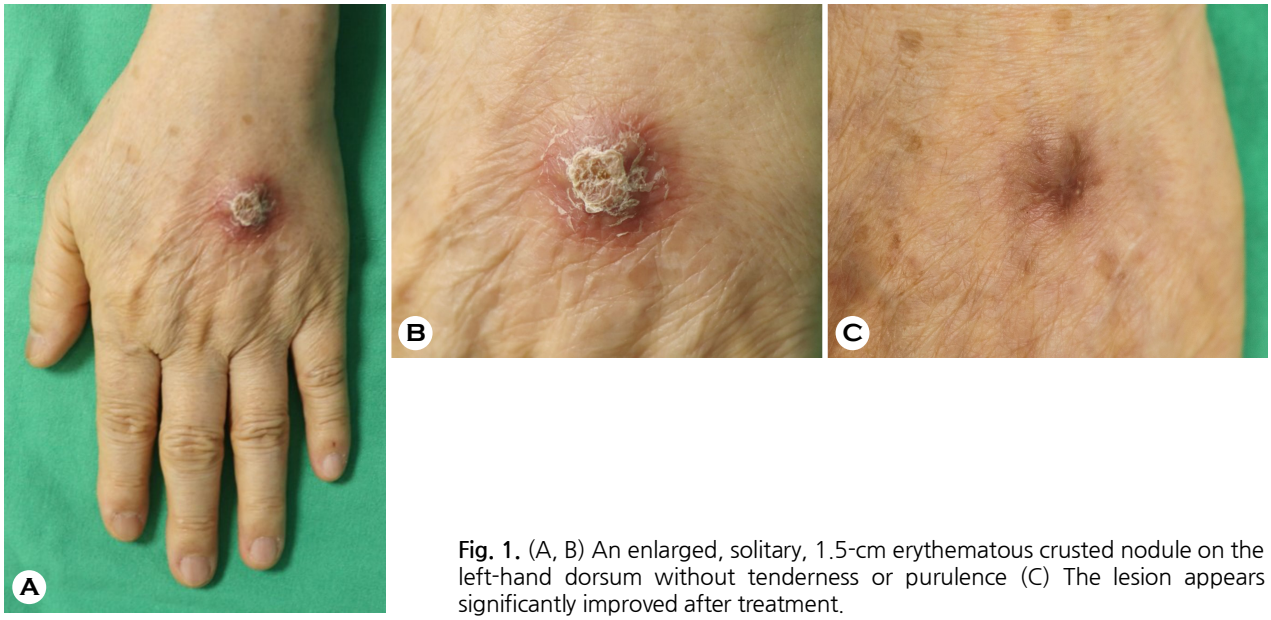

Fig. 1. (A, B) An enlarged, solitary, 1.5-cm erythematous crusted nodule on the left-hand dorsum without tenderness or purulence (C) The lesion appears significantly improved after treatment.

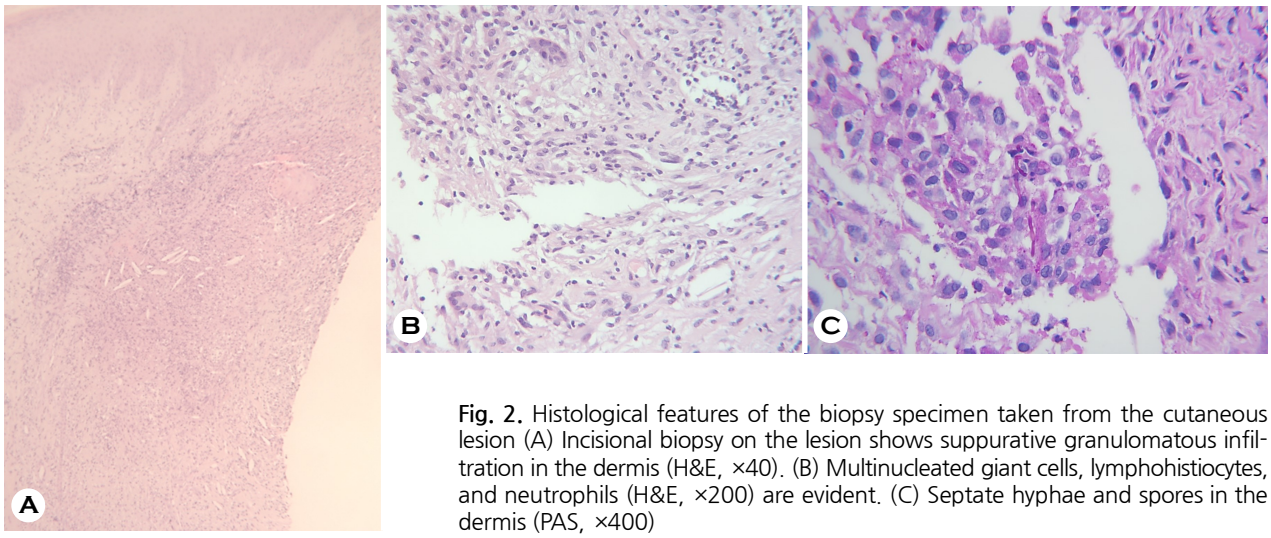

Fig. 2. Histological features of the biopsy specimen taken from the cutaneous lesion (A) Incisional biopsy on the lesion shows suppurative granulomatous infiltration in the dermis (H&E, ×40). (B) Multinucleated giant cells, lymphohistiocytes, and neutrophils (H&E, ×200) are evident. (C) Septate hyphae and spores in the dermis (PAS, ×400)

few cases have been reported, and none from Korea. This report describes the case of an immunocompetent patient with phaeohyphomycosis caused by *E. xenobiotica*.

CASE REPORT

A 75-year-old female presented with an asymptomatic, erythematous, and crusted subcutaneous nodule on her left-hand dorsum (Fig. 1A, 1B). The lesion gradually enlarged over the preceding 2 years without associated tenderness or purulence. Her past medical history was significant for hypertension, atrial fibrillation, and hyperlipidemia. Further, she showed no evidence of immunosuppression. The patient was living in an urban area, did not work, and recalled no history of trauma to the affected area.

Histopathological findings revealed suppurative granulomatous infiltration of the dermis with multinucleated giant cells with lymphohistiocytic and neutrophilic elements. Septate hyphae and spores were stained with periodic acid-Schiff

(PAS) in the dermis (Fig. 2). A fungal culture created from skin tissue on Sabouraud dextrose agar (SDA) showed microscopic olivaceous, black velvety colonies and black and septate hyphae with single-celled conidia (Fig. 3). Molecular identification through internal transcribed spacer (ITS) sequencing showed a 99% match with *E. xenobiotica*.

We diagnosed the patient with phaeohyphomycosis and began a 3-week course of terbinafine rather than itraconazole due to the potential for a drug interaction with nonvitamin K antagonist oral coagulant (NOAC). With only slight improvement with terbinafine, she continued treatment with fluconazole after tapering the NOAC. The lesion was signifi-

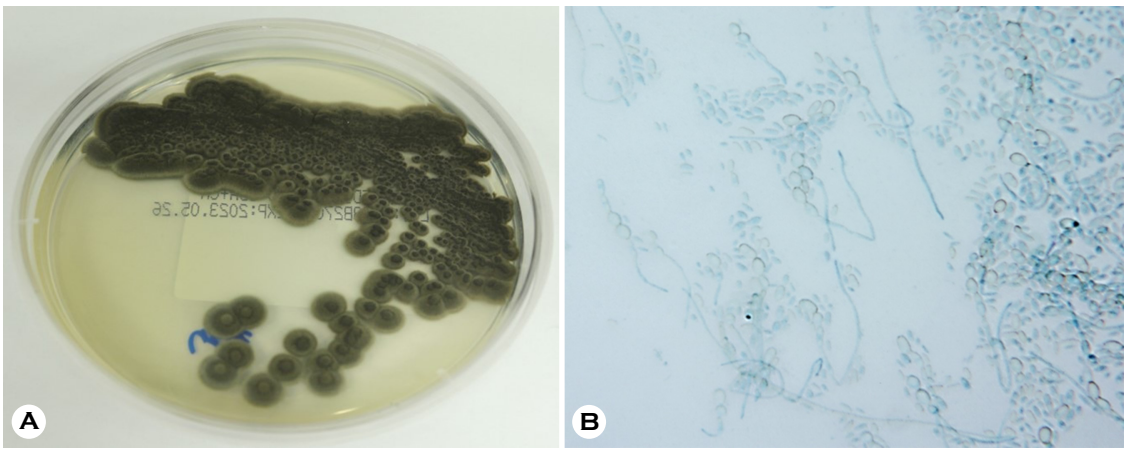

Fig. 3. (A) Fungal culture on Sabouraud dextrose agar (SDA) shows olivaceous, black-colored velvety colonies. (B) Microscopic morphology shows black, septate hyphae and single-celled conidia.

Table 1. Reported cases of phaeohyphomycosis caused by *Exophiala xenobiotica*

Case	Author (Year)	Sex/ Age	Site	Immunosuppressant (underlying disease)	Treatment
1	Aoyama et al. (2009)[14]	F/77	Hand	Prednisolone, chemotherapy (non-Hodgkin-lymphoma)	Surgical removal, itraconazole
2	Morio et al. (2012)[5]	M/53	Arm, knee	(HIV infection)	Surgical removal
3	Hasei et al. (2013)[15]	F/90	Finger, hand, forearm	Prednisolone (polyarthritis)	Surgical removal, terbinafine
4	Palmisano et al. (2015)[16]	F/65	Finger, forearm, leg	Prednisolone, tacrolimus, mycophenolate mofetil (post-renal transplant state)	Surgical removal, voriconazole, amphotericin-B, posaconazole
5	Ogawa et al. (2016)[17]	M/75	Hand, arm, leg	Prednisolone, tacrolimus (post-renal transplant state)	Itraconazole
6	Espanhol et al. (2020)[12]	M/45	Leg	Prednisolone, tacrolimus, mycophenolate mofetil (post-renal transplant state)	Surgical removal, itraconazole
7	Nomura et al. (2022)[13]	M/79	Finger	None	Surgical removal
8	Our case (2023)	F/75	Hand	None	Terbinafine, fluconzaole

Copyright@2024 by The Korean Society for Medical Mycology

cantly improved after 3 months (Fig. 1C), at which time treatment stopped. There have been no recurrences over the 10 months that have passed since stopping treatment.

DISCUSSION

Phaeohyphomycosis is a rare subcutaneous or systemic infection caused by dematiaceous fungi such as *Bipolaris*, *Phialophora*, *Alternaria*, and *Exophiala*[1]. Melanin is responsible for these species' black coloration, directly involved in phaeohyphomycoses' virulence. Melanin resists oxidation by free radicals within the hosts' phagocytic cells and binds to hydrolytic enzymes within phagocytic cells and to antifungal medications[6]. These infections occur across all climates, but are more common in the tropics. It is frequently observed in immunocompromised patients, particularly patients receiving long-term glucocorticoid therapies. Many patients also report a history of trauma to the affected area[7]. Phaeohyphomycosis typically manifests as a solitary abscess or nodule on an extremity. Histopathological examination and cultures are used to identify the fungal pathogen and differentiate it from sporotrichosis, chromoblastomycosis, and eumycetoma[8].

The *Exophiala* genus comprises 29 species, 18 of which are infectious. The most commonly isolated genera of dematiaceous fungi that cause phaeohyphomycosis are *E. jeanselmei*, *E. spinifera*, and *E. dermatitidis*[9]. Typically *E.* species are identified morphologically and physiologically. Macroscopically, they manifest as dark olivaceous-to-black colonies; microscopically, they exhibit septate hyphae and conidiophores with numerous conidia. Recent advances in molecular tools have supplemented traditional diagnostic approaches, particularly rDNA sequencing of the ITS region. This method identifies distinct morphologically indistinguishable strains, enabling clinicians to assess prognosis[10]. *E. xenobiotica* was initially classified as *E. jeanselmei*; however, newer, molecular methods revealed the novel species. *E. xenobiotica* is commonly found in habitats rich in monoaromatic hydrocarbons and alkanes, such as industrial biofilter sites[11]. Despite her denial of any work or trauma history, we suspect that a past minor trauma contributed to the infection.

E. xenobiotica is less virulent than other *E.* species and is frequently associated with cutaneous infections of mild-to-moderate severity[10]. However, there is disagreement as to the optimal treatment. A combined-modality treatment of antifungal drugs and surgery has shown promising clinical outcomes[12,13]. Additionally, itraconazole and posaconazole are more effective against *E.* species than voriconazole or amphotericin B[5].

Our case illustrates the efficacy of a combination treatment comprising terbinafine and fluconazole, but without concomitant surgery. A literature review revealed 7 cases of phaeohyphomycosis caused by *E. xenobiotica* (Table 1)[5,12,13,15-17] and we know of no other case reported from Korea. Of the published cases, 6 of 8 (75%) occurred in immunocompromised patients; however, our patient was immunocompetent. This suggests that although *E. xenobiotica* infections are commonly observed in immunocompromised patients, patients without overt immunocompromise may also be susceptible. This is the first report of phaeohyphomycosis caused by *E. xenobiotica* in an immunocompetent patient who was successfully treated with terbinafine and fluconazole. Considering the rarity of *E. xenobiotica* infections and the fact that no standard treatment exists, more reports are needed to establish treatment strategies.

ACKNOWLEDGEMENT

None.

CONFLICT OF INTEREST

In relation to this article, we declare that there is no conflict of interest.

ORCID

Jung Eun Seol: 0000-0002-3029-9635
Seung Hee Jang: 0000-0002-8343-209X
Hee Weon Yun: 0009-0009-2546-9255
Sang Woo Ahn: 0000-0003-4820-3870
Jeong Hwan Shin: 0000-0003-3960-6969
Hyojin Kim: 0000-0003-0987-4938

PATIENT CONSENT STATEMENT

The patient provided written informed consent for the publication and the use of her images.

REFERENCES

1. Ajello L. The gamut of human infections caused by dematiaceous fungi. Jpn J Med Mycol 1981;22:1-5

2. Nishikawa H, Taniguchi Y. Phaeohyphomycosis due to *Exophiala* oligosperma in an immunocompromised host. J Rheumatol 2019;46:652
3. Matsumoto T, Ajello L, Matsuda T, Szaniszlo PJ, Walsh TJ. Developments in hyalohyphomycosis and phaeohyphomycosis. J Med Vet Mycol 1994;32 Suppl 1:329-349
4. Suh MK. Phaeohyphomycosis in Korea. Nihon Ishinkin Gakkai Zasshi 2005;46:67-70
5. Morio F, Berre JY, Garcia-Hermoso D, Najafzadeh MJ, de Hoog S, Benard L, et al. Phaeohyphomycosis due to *Exophiala xenobiotica* as a cause of fungal arthritis in an HIV-infected patient. Med Mycol 2012;50:513-517
6. Jacobson ES. Pathogenic roles for fungal melanins. Clin Microbiol Rev 2000;13:708-717
7. Kim DS, Yoon YM, Kim SW. Phaeohyphomycosis due to *Exophiala dermatitidis* successfully treated with itraconazole. Korean J Med Mycol 1999;4:79-83
8. Perusquía-Oniz AM, Vázquez-González D, Bonifaz A. Opportunistic filamentous mycoses: aspergillosis, mucormycosis, phaeohyphomycosis and hyalohyphomycosis. J Dtsch Dermatol Ges 2012;10:611-621
9. Suh MK, Lee HC, Kim DM, Ha GY, Choi JS. Molecular phylogenetics of *Exophiala* species isolated from Korea. Ann Dermatol 2012;24:287-294
10. Zeng JS, Sutton DA, Fothergill AW, Rinaldi MG, Harrak MJ, de Hoog GS. Spectrum of clinically relevant *Exophiala* species in the United States. J Clin Microbiol 2007;45:3713-3720
11. De Hoog GS, Zeng JS, Harrak MJ, Sutton DA. *Exophiala xenobiotica* sp. nov., an opportunistic black yeast inhabiting environments rich in hydrocarbons. Antonie Van Leeuwenhoek 2006;90:257-268
12. Espanhol CM, Recuero JK, Pagani DM, Ribeiro AC, Vettorato G, Duquia RP, et al. Cutaneous phaeohyphomycosis caused by *Exophiala xenobiotica*: a case report. Med Mycol Case Rep 2020;27:39-41
13. Nomura T, Yamawaki Y. Finger abscess caused by a black fungus, *Exophiala xenobiotica*. Plast Reconstr Surg Glob Open 2022;10:e4565
14. Aoyama Y, Nomura M, Yamanaka S, Ogawa Y, Kitajima Y. Subcutaneous phaeohyphomycosis caused by *Exophiala xenobiotica* in a non-Hodgkin lymphoma patient. Med Mycol 2009;47:95-99
15. Hasei M, Takeda K, Anzawa K, Nishibu A, Tanabe H, Mochizuki T. Case of phaeohyphomycosis producing sporotrichoid lesions. J Dermatol 2013;40:638-640
16. Palmisano A, Morio F, Le Pape P, Degli Antoni AM, Ricci R, Zucchi A, et al. Multifocal phaeohyphomycosis caused by *Exophiala xenobiotica* in a kidney transplant recipient. Transpl Infect Dis 2015;17:297-302
17. Ogawa MM, Peternelli MP, Enokihara MM, Nishikaku AS, Gonçalves SS, Tomimori J. Spectral manifestation of melanized fungal infections in kidney transplant recipients: report of six cases. Mycopathologia 2016;181:379-385

Copyright@2024 by The Korean Society for Medical Mycology