CASE REPORT
J Mycol Infect 2024; 29(1): 19-23
pISSN:1226-4709, eISSN:2465-8278
https://dx.doi.org/10.17966/JMI.2024.29.1.19

JMI

Onychomycosis Caused by *Aspergillus* in a Patient with Leprosy: A Case Report

Andrea Hertanto, Muhammad Yulianto Listiawan†, Evy Ervianti, Afif Nurul Hidayati, Trisiswati Indranarum, Sunarso Suyoso, Linda Astari, Sylvia Anggraeni, Yuri Widia, Azalia Aprinda Bahat and Fitra Tri Kurniasari

Department of Dermatology and Venereology, Faculty of Medicine, Universitas Airlangga/Dr. Soetomo General Academic Hospital, Surabaya, Indonesia

Aspergillus spp., one of the most common nondermatophyte molds (NDMs) that cause onychomycosis, are saprophytic fungi that can act as zoonotic agents and cause various health issues, including onychomycosis, in humans. Predisposing factors for onychomycosis include nail trauma, immunosuppression, and occupation. Nails in patients with leprosy are prone to change and develop onychomycosis due to unrecognized trauma to the nail area. Here, we report the case of a 25-year-old woman with 2-month history of white patches in fingernails and toenails, which were also brittle and damaged. She was a veterinarian who had frequent, direct interaction with animals, particularly dogs and cats. She denied trauma prior to the manifestation of symptoms and was undergoing leprosy treatment, including corticosteroids for leprosy reactions. Examination with potassium hydroxide revealed hyphae, and the nail culture revealed growth of fungal colonies with the characteristics of *A. flavus*. She received four cycles of itraconazole at 400 mg/day. Two of the three afflicted nails showed complete cure, whereas one nail showed mycologic cure. *A. flavus* is frequently found in animals, including dogs and cats and might have been a source of *Aspergillus* transmission, suggesting the patient's occupation and immunosuppression as risk factors for onychomycosis. Onychomycosis due to *Aspergillus*, particularly *A. flavus*, responds well to itraconazole pulse monotherapy.

Key Words: *Aspergillus*, *Aspergillus flavus*, Itraconazole, Leprosy, Onychomycosis, Veterinarian

INTRODUCTION

Fungal nail infections, i.e., onychomycosis, can originate from yeasts, dermatophytes, and nondermatophyte molds (NDMs), in contrast to tinea unguium, which refers to fungal nail infections exclusively caused by dermatophytes[1]. NDMs account for 3~25% of all onychomycosis cases[2-4]. Conversely, *Aspergillus* spp. account for 7.7~100% of all NDM-caused onychomycosis cases and 0.5~3% of all onychomycosis cases. In the last two decades, the incidence of onychomycosis due to *Aspergillus* infection has been increasing, especially in Asia[3,4]. *Aspergillus* spp. are saprophytic fungi found in soil, decaying plants, household and hospital dust, and fruit, vegetable, and grain surfaces[4-6]. Fungi, including *Aspergillus*, are zoonotic infectious agents naturally transmitted between animals and humans and can cause various infections in humans and animals, such as dogs and cats[6,7].

The clinical manifestations of onychomycosis due to *Asper-*

Received: January 18, 2024 Revised: February 9, 2024 Accepted: February 19, 2024
†Corresponding: Muhammad Yulianto Listiawan, Department of Dermatology and Venereology, Faculty of Medicine, Universitas Airlangga/Dr. Soetomo General Academic Hospital, Surabaya, Indonesia.
Phone: +62-811323730, Fax: +62-315501709, e-mail: yuliantowawan@yahoo.com
Copyright@2024 by The Korean Society for Medical Mycology. All right reserved.
This is an open-access article distributed under the terms of the Creative Commons Attribution Non-Commercial License (http://creativecommons.org/licenses/by-nc/3.0/), which permits unrestricted non-commercial use, distribution, and reproduction in any medium, provided the original work is properly cited. http://www.ksmm.org

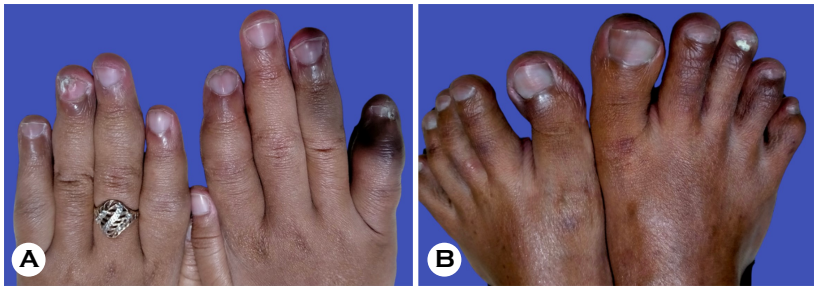

Fig. 1. Dermatologic status of the patient at the initial visit; Clinical appearance of the fingernails (A) and the toenails (B)

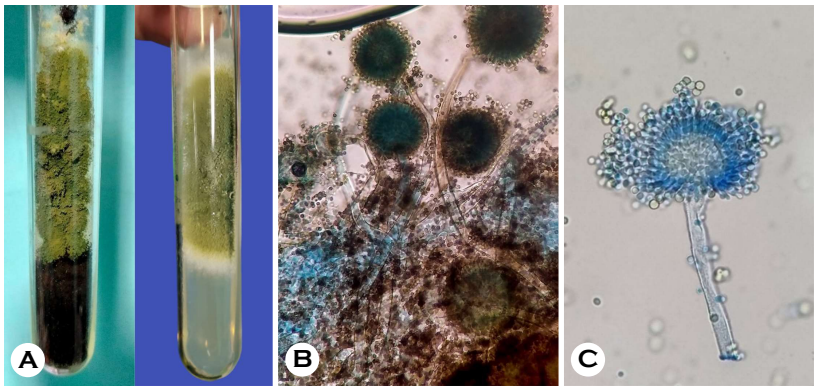

Fig. 2. Nail culture results (A) Results of the first (left) and second (right) nail cultures (B) Microscopically, the black colony exhibits the characteristic appearance of *A. niger* (potassium hydroxide preparation, ×400). (C) Microscopically, the yellow-green colonies exhibit the characteristics of *A. flavus* (potassium hydroxide preparation, ×400).

gillus spp. are nonspecific and can mimic onychomycosis caused by dermatophytes; however, distolateral subungual onychomycosis is the most common form of *Aspergillus* spp. infection of nails[3,4]. Pulse therapy with oral itraconazole and terbinafine exhibits good efficacy against onychomycosis caused by NDMs[3,8].

CASE REPORT

A 25-year-old woman was referred to our clinic with a 2-month history of white spots on fingernails and toenails. She indicated that white patches and brittle nails in the absence of pain and itching appeared on right little finger, with the same symptoms developing in left ring finger and right middle toe one week later. The patient denied trauma preceding the symptoms. For this complaint, the patient clipped her nails and did not take any medication. However, she did not observe improvement and the regrown nails were brittle with white patches.

The patient was a veterinarian who frequently interacted with dogs and cats. The patient suffered finger swelling three years ago and developed brown blotchy spots on her face accompanied by swelling of the nose, ears, and face. The patient was treated for rheumatoid arthritis (RA) with long-term systemic corticosteroids without improvement. She was referred to the leprosy division of an outpatient dermato-venereology clinic, where she was diagnosed with lepromatous leprosy with type 2 reaction. She was administered leprosy drugs and prednisone, which led to improvement. However, one month later, the patient was referred to the mycology division with white spots on nails.

The dermatologic examination revealed subungual white spots on the distal edge of the nail plate as well as nail dystrophy in the fifth finger of right hand and the fourth finger of left hand. Additionally, a white spot on the surface nail plate was observed on the third nail of right foot (Fig. 1). Potassium hydroxide (KOH) examination of the fingernails and toenails revealed hyphae. The first nail culture showed growth of two types of fungal colonies representing the *A. niger* and *A. flavus* complexes. The repeated second nail culture showed the growth of only *A. flavus* (Fig. 2).

The patient was diagnosed with distolateral subungual and superficial white onychomycosis and treated with four cycles of itraconazole at 400 mg/day for one week, with 3-week breaks between cycles. KOH examination of the toenails performed after the fourth itraconazole cycle still showed hyphae, and the *A. flavus* colonies were growing in the nail

Copyright@2024 by The Korean Society for Medical Mycology

Fig. 3. Clinical progression of the patient before and after the fourth cycle of itraconazole pulse therapy (A) Fourth fingernail of left hand, (B) Fifth fingernail of right hand, (C) Third toenail of right foot

culture, whereas the KOH examination and the culture of fingernail were negative. Clinically, the third nail of right foot and the fourth nail of left hand appeared to be returning to normal (Fig. 3A, C). The fifth nail of right hand exhibited clinical improvement but did not completely revert to normal. Itraconazole therapy was discontinued. Reevaluation two months later revealed negative findings with KOH examination and toenail culture, whereas the nail on the fifth finger of the right hand was not clinically reverting to normal (Fig. 3B).

DISCUSSION

Aspergillus spp. are typically considered as contaminants in onychomycosis, although they can also be causative organisms[3,4]. *Aspergillus* spp. as a cause is considered if the case fulfills three of the following criteria: (i) KOH examination showing fungal elements, (ii) nail biopsy showing fungal elements; (iii) culture showing NDM growth, (iv) repeated cultures showing the same NDM growth without dermatophytes; (v) culture growth of the same fungus found in 5 or more than 20 inoculums, and (vi) molecular examination showing NDMs[2-4].

In the present case, KOH examination revealed hyphae on both fingernails and toenails and two types of fungal colonies grew in the first nail culture. One of the colonies had a silky greenish-yellow surface, yellow dots, white margins, and a yellowish back. Long conidiophores with rough surfaces and biseriate phialides were observed under the microscope, indicating the presence of the *A. flavus* complex. The second colony had a black surface and cream back; microscopic examination revealed long, smooth conidiophores, indicating the *A. niger* complex[8,10]. Unfortunately, the second nail culture only showed colony growth matching the *A. flavus* complex, without dermatophyte growth. Therefore, the present case met three of the six criteria for NDMs as the causative organism (*A. flavus*), whereas the *A. niger* complex could be considered a contaminant.

Many factors are associated with the development of onychomycosis due to NDMs, including hot and humid climates, older age, use of closed shoes, hyperhidrosis, nail trauma, chronic skin disease, immunosuppression, occupational exposure, poor hygiene, barefoot walking, diabetes mellitus, use of communal locker rooms, and paronychia[1,3,4]. Onychomycosis is observed in 20~30% of patients with leprosy. Nails in patients with leprosy are prone to change and develop onychomycosis compared with the general population, mainly due to unrecognized nail trauma, which often occurs due to peripheral nerve disorder that increases the risk of NDM infection[11]. Leprosy reaction is defined as an acute or chronic inflammatory episode that is immunologically mediated in patients with leprosy, and corticosteroids are the main therapeutic option for leprosy reactions[12,13]. Leprosy-related acute arthritis often results from a leprosy reaction and clinically presents as inflammatory polyarthritis affecting the small joints of hands and feet, similar to that observed in RA. Patients with leprosy and arthritis do not require additional glucocorticoids; significant improvement is usually achieved after the start of leprosy therapy, even if the patients do not completely recover[14].

The present patient was at risk due to immunosuppression secondary to corticosteroid therapy for leprosy reactions. The patient was in an immunosuppressed state before the treatment for leprosy reaction. She was initially diagnosed with RA and received long-term corticosteroid treatment, which failed, and the diagnosis was revised to arthritis due to leprosy, with improvement of finger swelling following appropriate treatment. Although the patient denied nail trauma before the initial complaints, peripheral nerve disorders caused by leprosy infection can cause unrealized nail trauma, which can lead to onychomycosis.

Fungal skin infections are the most common infections

associated with pets. In a study by Sudipa et al., 8 of the 15 dogs free-roaming dogs in Bali included in the study had *Aspergillus* spp. on skin (53.55%), with *A. fumigatus* and *A. niger* as the two main species[6]. In a study of 20 cats, Mokhtar reported that *A. flavus*, *A. nidulans*, and *A. niger* were isolated from 20 (100%), 15 (75%), and 5 (25%) cats, respectively[7]. The present patient was a veterinarian and had frequent, direct interaction with dogs and cats, which could be a source of *Aspergillus* transmission. Additionally, the nail culture revealed the growth of *A. flavus* and *A. niger* colonies, although *A. niger* did not grow in the second nail culture. These findings are consistent with those of Mokhtar and Sudipa et al., where *A. flavus* and *A. niger* were the most commonly found *Aspergillus* spp. in dogs and cats.

In patients with onychomycosis, oral antifungals are preferred because of their superior efficacy compared to topical therapy; the limited diffusion of topical drugs to the nail leads to reduced therapeutic efficacy[9,15]. The British Association of Dermatologists recommends terbinafine and itraconazole as first-line therapeutics for onychomycosis. *In vitro* studies show that *Aspergillus* spp. exhibit the best sensitivity to itraconazole, followed by miconazole, ketoconazole, and terbinafine[16]. In many countries, itraconazole pulse therapy with 3~4 cycles is approved for the treatment of toenail onychomycosis[17]. Certain patient characteristics may require a longer course of treatment or higher dosages. These conditions include comorbidities such as immunosuppression, diabetes, a greater number of affected fingers, more severe disease manifestation, resistance, and cooccurrence of dermatophyte infection and resistance[3].

The present patient was treated with four cycles of itraconazole at 400 mg/day. The 2-month evaluation after the end of treatment revealed complete cure of the fourth fingernail in left hand and the third toenail in right foot, with mycologic cure in the fifth fingernail of right hand.

CONCLUSION

NDMs should be considered not only as contaminants but also as causative agents in patients with onychomycosis. Mycologic examination is essential to confirm the diagnosis of onychomycosis caused by NDMs. Dogs and cats, which are the most common pets, can be a source of the transmission of fungal infections, including *Aspergillus* spp. Itraconazole pulse therapy is an effective approach in onychomycosis due to *A. flavus*.

ACKNOWLEDGEMENT

We would like to thank the staff of the Mycology Division in the Dermato-Venereology Department at Dr. Soetomo General Academic Hospital Surabaya for their assistance and guidance in the treatment of the patient and the preparation of the manuscript.

CONFLICT OF INTEREST

In relation to this article, we declare that there is no conflict of interest.

ORCID

Andrea Hertanto: 0009-0008-0620-7893
Muhammad Yulianto Listiawan: 0000-0002-8724-6251
Evy Ervianti: 0000-0002-2443-014X
Afif nurul Hidayati: 0000-0003-2558-2046
Trisiswati Indranarum: 0009-0007-7485-0138
Sunarso Suyoso: 0009-0008-0404-5851
Linda Astari: 0000-0002-2939-1493
Sylvia Anggraeni: 0000-0002-5259-714X
Yuri Widia: 0000-0002-3598-5714
Azalia Aprinda Bahat: 0009-0004-6323-7838
Fitra Tri Kurniasari: 0000-0002-8213-6766

PATIENT CONSENT STATEMENT

The patient provided written informed consent for the publication and the use of her images.

REFERENCES

1. Craddock LN, Schieke SM. Superficial fungal infection. In: Kang S, Amagai M, Bruckner AL, Enk AH, Margolis DJ, McMichael AJ, et al, editors. Fitzpatrick's dermatology. 9th ed. New York: McGraw-Hill, 2019:2925-2951
2. Laroche L, Bourgeois N, Lachaud L, Rispail P. Epidemiological analysis of nail aspergillosis and non-dermatophyte moulds. Criteria for the involvement of *Aspergillus* in 102 cases of onychomycosis at Montpellier University Hospital, France (1991~2019). Mycoses 2021;64:1546-1553
3. Gupta AK, Summerbell RC, Venkataraman M, Quinlan

 Copyright@2024 by The Korean Society for Medical Mycology

EM. Nondermatophyte mould onychomycosis. J Eur Acad Dermatol Venereol 2021;35:1628-1641
4. Bongomin F, Batac CR, Richardson MD, Denning DW. A review of onychomycosis due to *Aspergillus* species. Mycopathologia 2018;183:485-493
5. Gnat S, Łagowski D, Nowakiewicz A, Dyląg M. A global view on fungal infections in humans and animals: opportunistic infections and microsporidioses. J Appl Microbiol 2021;131:2095-2113
6. Sudipa PH, Puja IK, Dharmayuda AAGO, Gunawan IWNF, Sudimartini LM, Jayanti PD, et al. Identification and prevalence of *Aspergillus* sp isolated from Bali dog's skin. J Riset Vet Ind 2023;7:47-53
7. Mokhtar A. The relationship between aspergillosis in cats and human otomycosis of pets' owners in Assiut city. Assiut Veterinary Medical Journal 2022;68:49-57
8. Frías-De-León MG, Espinosa-Hernández VM, Bonifaz A, Martínez-Herrera E. Onychomycosis due to *Aspergillus* spp. A current review. Current Fungal Infection Reports 2018;12:112-119
9. Gupta AK, Stec N. Recent advances in therapies for onychomycosis and its management. F1000 Research 2019;8:F1000 Faculty Rev-968
10. Walsh TJ, Hayden RT, Larone DH. Larone's medically important fungi: a guide to identification. 6th ed. Washington: John Wiley & Sons, 2018:297-298
11. Vettorato R, Heidrich D, Eidt LM, Pagani DM, Ribeiro AC, Dallé da Rosa P, et al. Onychomycosis caused by *Arthrinium arundinis* in leprosy patient: case report. Med Mycol Case Rep 2020;30:19-21
12. Listiyawati IT, Sawitri S, Agusni I, Prakoeswa CRS. Oral corticosteroid therapy in leprosy's new patients with type 2 reaction. Berkala Ilmu Kesehatan Kulit dan Kelamin 2015;27:48-54
13. Kar HK, Chauhan A. Leprosy reactions: pathogenesis. In: Kumar B, Kar HK, Dogra S, editors. IAL textbook of leprosy. New Delhi: Jaypee brothers medical publishers, 2017:416-437
14. Gunawan H, Wulansari Y, Achdiat PA, Hindritiani R. Leprosy-related chronic arthritis with an abundance of *Mycobacterium leprae* in the synovial fluid: a rare case. Int Med Case Rep J 2021;14:371-376
15. Pal M, Dave P, Dave K, Gutama KP, Thangavelu L, Paula CR, et al. Etiology, clinical spectrum, epidemiology, new developments in diagnosis and therapeutic management of onychomycosis: an update. Am J Microbiol Res 2023;11:19-24
16. Ameen M, Lear JT, Madan V, Mohd Mustapa MF, Richardson M. British Association of Dermatologists' guidelines for the management of onychomycosis 2014. Br J Dermatol 2014;171:937-958
17. Gupta AK, Foley KA. Systemic antifungal agents. In: Wolverton SE, Wu JJ, editors. Comprehensive dermatologic drug therapy. 4th ed. Philadelphia: Elsevier, 2021: 99-113