CASE REPORT
J Mycol Infect 2023; 28(1): 10-13
pISSN:1226-4709, eISSN:2465-8278
https://dx.doi.org/10.17966/JMI.2023.28.1.10

JMI

A Case of Oral Candidiasis Treated with Fluconazole (Diflucan®) Mouthrinse

Dong-Wha Yoo, Kyung-Deok Park, Hyeok-Jin Kwon, Jeong-Wan Seo, Jung-Ho Yoon and Ki-Ho Kim†

Department of Dermatology, College of Medicine, Dong-A University, Busan, Korea

Oral candidiasis, a common fungal infection in humans, is characterized by the overgrowth of *Candida* species in the superficial oral epithelial mucosa. The condition is associated with multiple risk factors, including impaired salivary gland function, oral mucosal damage, and long-term antibiotic or corticosteroid use. Several treatment options are available; nystatin and amphotericin B are the most widely used local medications. Recently, fluconazole has emerged as the preferred systemic treatment. We report a case of oral candidiasis in an 83-year-old male diagnosed with bullous pemphigoid in 2017 and previously administered methylprednisolone. He developed oral candidiasis a few months before presentation and was treated with 10 mL nystatin suspension three times daily; unfortunately, the disease was recalcitrant to this treatment and his symptoms showed no improvement over two months. We discontinued nystatin in favor of fluconazole syrup (Diflucan®) administered by rinsing, then swallowing, 5 mL syrup once daily. The lesion improved after one month of treatment. This case demonstrates the efficacy of fluconazole as a primary treatment for oral candidiasis. The act of rinsing the mouth with syrup exposes the oral mucosa to drug, potentially producing a better treatment response than taking the syrup orally without rinsing.

Key Words: Fluconazole syrup, Mouthrinse, Nystatin suspension, Oral candidiasis

INTRODUCTION

Candida infections are becoming more common due to the widespread use of broad-spectrum antibiotics and corticosteroids and the growing number of individuals with immunocompromise[1]. Identifying the type of *Candida* infection is essential for choosing an effective treatment. Identification of predisposing factors or underlying diseases is also important for managing infections[2,3]. Oral candidiasis a common opportunistic fungal infection of the oral cavity[2]. Here, we report a case of nystatin-recalcitrant oral candidiasis caused by long-term systemic steroid use and treated with a fluconazole mouthrinse.

CASE REPORT

An 83-year-old male presented with a three-month history of diffuse, painful, and creamy white tongue ulcerations (Fig. 1A). He was diagnosed with bullous pemphigoid in 2017 and was being treated with ongoing, low-dose steroids.

We collected a direct smear sample of the patient's oral mucosa using 10% potassium hydroxide (KOH); a fungal culture was performed on the oral lesions. The KOH smear showed numerous pseudohyphae with variably sized spores. The culture revealed smooth, creamy white colonies on Sabouraud dextrose agar plates, suggesting oral candidiasis (Fig. 2). Species identification was performed by matrix-

Received: December 26, 2022 Revised: January 11, 2023 Accepted: February 15, 2023
†Corresponding: Ki-Ho Kim, Department of Dermatology, College of Medicine, Dong-A University, 26, Daesingongwon-ro, Seo-gu, Busan 49201, Korea.
Phone: +82-10-8549-3875, Fax: +82-51-253-0787, e-mail: khkim@dau.ac.kr
Copyright@2023 by The Korean Society for Medical Mycology. All right reserved.
This is an open-access article distributed under the terms of the Creative Commons Attribution Non-Commercial License (http://creativecommons.org/licenses/by-nc/3.0/), which permits unrestricted non-commercial use, distribution, and reproduction in any medium, provided the original work is properly cited. http://www.ksmm.org

Fig. 1. (A-B) Diffuse, painful, and creamy white lesion on the tongue before (A) and after (B) gargling with nystatin suspension (1,000,000 IU/10 mL) three times daily, showing no significant improvement (C) The lesion is improved after treatment with fluconazole mouthrinse (5 mL syrup containing 10 mg/mL of fluconazole in distilled water) once daily for a month. No recurrence was noted over the six-month follow-up period.

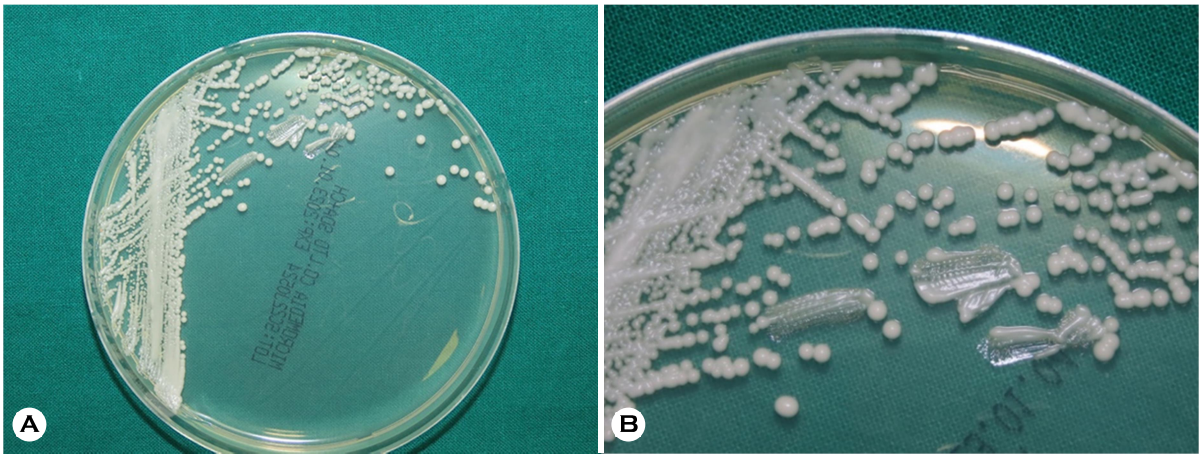

Fig. 2. (A, B) Smooth, creamy white colonies grow on Sabouraud dextrose agar at 30℃ for 48 h.

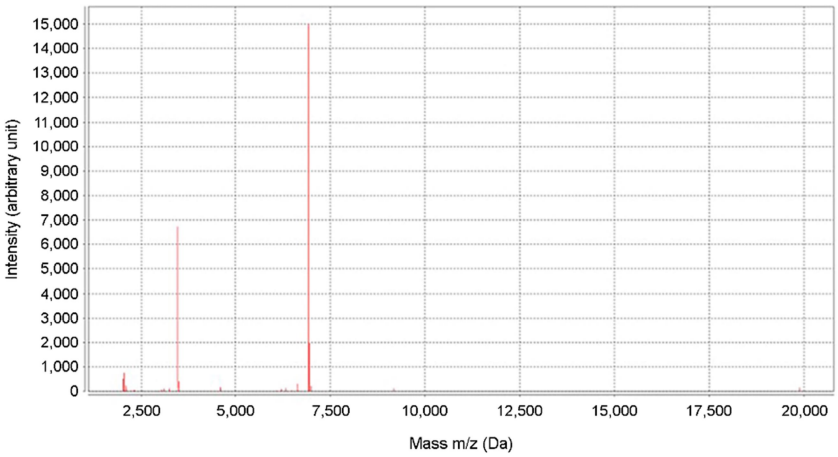

Fig. 3. Peptide mass fingerprinting of *Candida albicans* by MALDI-TOF MS.

assisted laser desorption ionization-time of flight mass spectrometry (bioMérieux Vitek, Durham, NC, USA) which indicated *Candida albicans* on the peptide mass fingerprinting (Fig. 3).

We treated the patient with 1,000,000 IU/10 mL of nystatin suspension three times daily with the instructions to hold the suspension in the mouth as long as possible, and then swallow. After two months of treatment, the patient's symptoms were unimproved (Fig. 1B). We therefore discontinued the nystatin suspension and, instead, administered fluconazole syrup (Diflucan®) prepared as 10 mg/mL of fluconazole in distilled water. The patient was instructed to rinse his mouth daily with 5 mL syrup for 3 min before swallowing to increase the duration of contact between the oral mucosa and medicated syrup. After one month of treatment, the patient's oral lesions were significantly improved. No recurrence was noted over six months of follow-up (Fig. 1C).

DISCUSSION

Oral candidiasis is caused by approximately 150 *Candida* species; *Candida albicans* being the most frequently isolated[3]. Recent increases in oral candidiasis in elderly patients[5] have been attributed to aging of the general population. With age, the risk of candidiasis increases and its consequences become more-severe; therefore, accurate and early diagnosis is essential.

Treatment selection should be guided by the identification and management of predisposing factors or other underlying diseases. Additionally, drug-related efficacy and toxicity should be considered after determining the type of *Candida* infection[2]. Clinically, treatment is generally guided by the type of oral candidiasis—such as acute pseudomembranous, acute erythematous (atopic), chronic pseudomembranous, chronic erythematous, chronic hyperplastic, median rhomboid glossitis, and angular cheilitis[4]. The pseudomembranous type (thrush) is the classic form of the disease, accounting for nearly a third of all reported cases. Our patient was also diagnosed with pseudomembranous candidiasis, characterized by creamy yellowish-white oral mucosal plaques that, when removed with a swab, will reveal an erythematous and often bleeding underlying lesion[4,6].

Several topical and systemic agents are used to treat oral candidiasis. Topical therapies—nystatin, amphotericin B, miconazole, or clotrimazole—are generally effective for treating superficial infections and are recommended as first-line treatments for uncomplicated oral candidiasis[4,6]. Nystatin (discovered in 1950 and approved by the United States Food and Drug Administration in 1954) is a membrane-active polyene macrolide with broad-spectrum anti-yeast effects. However, given its toxicity and insolubility in the gastrointestinal tract, nystatin is mainly used in topical formulations[7-10].

Systemic treatment is considered for more-severe or spreading lesions unable to be resolved by topical means alone. Fluconazole is recommended as a first-line systemic therapy and is a common antifungal agent[11]; however, other triazoles are available for fluconazole-resistent lesions. Fluconazole is a selective inhibitor of CYP-dependent C-14-α sterol demethylase, which inhibits the synthesis of ergosterol and disrupts fungal cell membrane integrity. It has >90% oral bioavailability and is mainly excreted in urine. Once administered, fluconazole easily penetrates the skin, maintaining a higher concentration in the skin than in serum[4,8]. When administered in tablet form, fluconazole is detectable in saliva for 2 h; however, rinsing with fluconazole syrup before swallowing directly exposes the oral mucosa to the drug, which is detectable 4 h later, suggesting improved efficacy. Furthermore, because pathogenic microorganisms are usually detected in the superficial mucosa, the effectiveness of fluconazole mouthrinse might be attributable to the temporarily exposure of the oral mucosa to highly concentrated medicine. Additionally, the liquid suspension formulation is better for use with patients, as dry mouth and swallowing issues are more common in the elderly[6,12].

Nystatin suspension, held in the mouth for as long as possible before swallowing, may exert direct and systemic effects, like the fluconazole mouthrinse. However, prior literature indicates that nystatin is non-superior to fluconazole[7,10]. This seems to agree with our case, who failed to benefit from two months of treatment with nystatin, but who demonstrated considerable improvement once switched to a fluconazole mouthrinse. These results provide further support for fluconazole's superior treatment effects when compared to nystatin in patients with oral candidiasis. Moreover, treatment efficacy appeared to be enhanced by the act of mouth rinsing. Given that a once-a-day mouthrinse is less burdensome that the nystatin suspension administered three times daily, treatment compliance may be enhanced. To the best of our knowledge, this is the first South Korean case to compare a nystatin suspension and fluconazole mouthrinse for treatment of oral candidiasis, with particular attention to the rinse's topical effects.

ACKNOWLEDGEMENT

The authors thank the patient for agreeing to the use of his information for this report.

Copyright@2023 by The Korean Society for Medical Mycology

CONFLICT OF INTEREST

In relation to this article, we declare that there is no conflict of interest.

ORCID

Dong-Wha Yoo: 0000-0002-1395-3981
Kyung-Deok Park: 0000-0003-1064-5307
Hyeok-Jin Kwon: 0000-0003-1966-0570
Jeong-Wan Seo: 0000-0001-9179-2864
Jung-Ho Yoon: 0000-0001-5756-1341
Ki-Ho Kim: 0000-0001-5389-5053

PATIENT CONSENT STATEMENT

The patient provided written informed consent to use and publish his images.

REFERENCES

1. Neppelenbroek KH, Seó RS, Urban VM, Silva S, Dovigo LN, Jorge JH, et al. Identification of *Candida* species in the clinical laboratory: a review of conventional, commercial, and molecular techniques. Oral Dis 2014;20:329-344
2. Garcia-Cuesta C, Sarrion-Pérez MG, Bagán JV. Current treatment of oral candidiasis: A literature review. J Clin Exp Dent 2014;6:e576-e582
3. Singh A, Verma R, Murray A, Agrawal A. Oral candidiasis: An overview. J Oral Maxillofac Pathol 2014;18(Suppl 1): S81-S85
4. Akpan A, Morgan R. Oral candidiasis. Postgrad Med J 2002;78:455-459
5. Sakaguchi H. Treatment and prevention of oral Candidiasis in elderly patients. Med Mycol J 2017;58:J43-J49
6. Epstein JB, Gorsky M, Caldwell J. Fluconazole mouthrinses for oral candidiasis in postirradiation, transplant, and other patients. Oral Surg Oral Med Oral Pathol Oral Radiol Endod 2002;93:671-675
7. Lyu X, Zhao C, Yan ZM, Hua H. Efficacy of nystatin for the treatment of oral candidiasis: a systematic review and meta-analysis. Drug Des Devel Ther 2016;10:1161-1171
8. Kaur IP, Kakkar S. Topical delivery of antifungal agents. Expert Opin Drug Deliv 2010;7:1303-1327
9. Wong SSW, Samaranayake LP, Seneviratne CJ. In pursuit of the ideal antifungal agent for *Candida* infections: high-throughput screening of small molecules. Drug Discov Today 2014;19:1721-1730
10. Goins RA, Ascher D, Waecker N, Arnold J, Moorefield E. Comparison of fluconazole and nystatin oral suspensions for treatment of oral candidiasis in infants. Pediatr Infect Dis J 2002;21:1165-1167
11. Shin JH, Won EJ, Kim SH, Shin JH, Lee D, Lee DH, et al. A multicenter study of antifungal use and species distribution and antifungal susceptibilities of *Candida* isolates in South Korea. J Mycol Infec 2020;25:10-16
12. Sholapurkar AA, Pai KM, Rao S. Comparison of efficacy of fluconazole mouthrinse and clotrimazole mouthpaint in the treatment of oral candidiasis. Aust Dent J 2009; 54:341-346