CASE REPORT
J Mycol Infect 2022; 27(4): 85-88
pISSN:1226-4709, eISSN:2465-8278
https://dx.doi.org/10.17966/JMI.2022.27.4.85

JMI

Deep Dermatophytosis Presented as Multiple Exophytic Masses caused by *Trichophyton rubrum* in Immunocompromised Patient with Rheumatoid Arthritis; A Case Report

Jung Eun Seol[1], Seong Min Hong[1], Seung Hee Jang[1], Sang Woo Ahn[1], Jong Soo Choi[2], Jeong Hwan Shin[3], Jayoung Kim[4] and Hyojin Kim[1†]

[1]Department of Dermatology, College of Medicine, Inje University, Busan, Korea
[2]Department of Dermatology, College of Medicine, Yeungnam University, Daegu, Korea
[3]Department of Laboratory Medicine, College of Medicine, Inje University, Busan, Korea
[4]Department of Laboratory Medicine, College of Medicine, Catholic Kwandong University, Incheon, Korea

Dermatophytes invade the stratum corneum and infect the skin, nails, and hair, mostly resulting in superficial infections. Deep dermatophytosis involving the dermis and subcutaneous layer has rarely been reported in immunocompromised individuals. Herein, we report a case of deep dermatophytosis caused by *Trichophyton rubrum*. A 71-year-old woman presented with multiple erythematous exophytic and subcutaneous nodules in both the lower legs. The patient was taking immunosuppressive agents for rheumatoid arthritis and antifungal agents for tinea pedis and onychomycosis, which was improperly ceased. Histopathological findings showed diffuse granulomatous infiltration with multinucleated cells, lymphocytes, histiocytes, and neutrophils in the dermis. Septate and branched hyphae were observed in the dermis using periodic acid-Schiff diastase and Gomori methenamine silver staining. *T. rubrum* was identified in fungal culture from the tissue sample and confirmed through phylogenetic analysis of the internal transcribed spacer and large subunit regions in ribosomal ribonucleic acid gene. Intravenous amphotericin B was administered for septic shock before the confirmation of the causative organism, which rapidly improved the condition.

Key Words: Deep dermatophytosis, *Trichophyton rubrum*

INTRODUCTION

Dermatophytes are the most common cause of superficial fungal infections in humans; *Trichophyton (T.) rubrum* is the most frequently isolated pathogen[1]. In humans, dermatophytes are mainly confined to the stratum corneum, nails, and hair. Dermatophytes do not actively penetrate deeper than the basal layer[2]. They rarely penetrate deeply into the dermis and cause invasive infections involving hair follicles; the dermis; subcutaneous tissue; and even internal organs, such as the lymph nodes, bone, and brain[1]. Invasive dermatophytosis is typically associated with immunosuppression and lymphoproliferative disorders. Compared with immunocompetent patients, patients with immunosuppression have an

Received: October 26, 2022 Revised: October 31, 2022 Accepted: October 31, 2022
†Corresponding: Hyojin Kim, Department of Dermatology, Busan Paik Hospital, College of Medicine, Inje University. 75 Bokji-ro, Busanjin-gu, Busan, 47392, Korea.
Phone: +82-51-890-6135, Fax: +82-51-890-5845, e-mail: derma09@hanmail.net
Copyright@2022 by The Korean Society for Medical Mycology. All right reserved.
©This is an open-access article distributed under the terms of the Creative Commons Attribution Non-Commercial License (http://creativecommons.org/licenses/by-nc/3.0/), which permits unrestricted non-commercial use, distribution, and reproduction in any medium, provided the original work is properly cited. http://www.ksmm.org

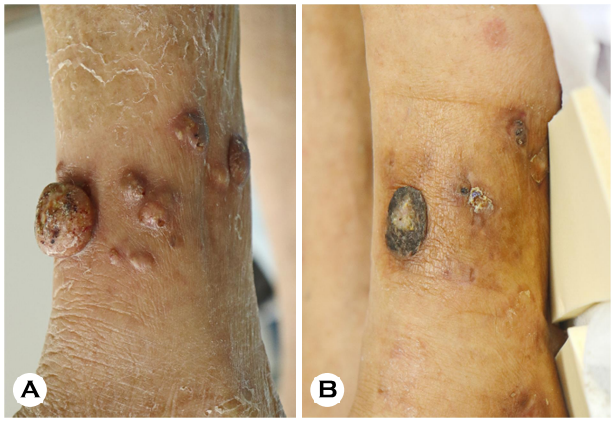

Fig. 1. (A) 71-year-old woman presented with multiple erythematous exophytic and subcutaneous nodules located on lower legs. (B) All lesions showed improvement after amphotericin B administration.

increased risk of invasive form transformation, owing to chronic infection resulting from a higher rate of recurrence and recalcitrance. Herein, we report an atypical presentation of deep dermatophytosis as multiple exophytic masses in the bilateral lower limbs.

CASE REPORT

A 71-year-old woman admitted for pneumonia was referred for an erythematous exophytic mass with multiple subcutaneous nodules on both lower legs (Fig. 1A). The initial skin lesion was detected on the left leg a month before referral, which subsequently spread to the adjacent tissue and the right leg. The patient had a history of rheumatoid arthritis and was treated immunosuppressants, such as tacrolimus, low-dose systemic steroid, leflunomide, and methotrexate, for more than 10 years. Furthermore, she had taken an antifungal medication for tinea pedis and unguium; however, she decided to discontinue the treatment.

A deep fungal infection was suspected based on her skin lesion and history. A skin biopsy was performed on her left lower leg. Histopathological examination revealed pseudoepitheliomatous epidermal hyperplasia with micro-abscess formation in the epidermis and diffuse granulomatous inflammation consisting of multinucleated giant cells, lymphocytes, neutrophils, and histiocytes in the dermis. Immunohistochemical staining with periodic acid-Schiff and Gomori methenamine silver revealed septate and branched fungal hyphae in the dermis (Fig. 2). Fungal cultures performed using biopsy

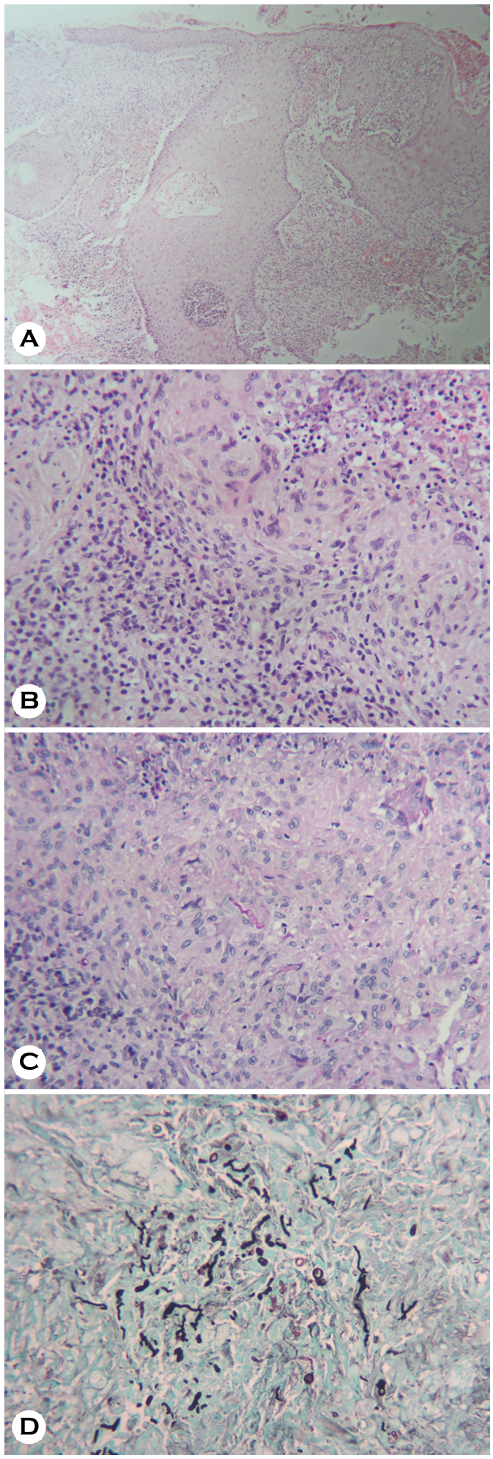

Fig. 2. (A) Microabscess, pseudoepitheliomatous hyperplasia in epidermis with dense mixed infiltration in demis consisting of neutrophils, lymphocytes, histiocytes, multi-nucleated giant cell (H&E, ×100) (B) Diffuse granulomatous infiltration with multi-nucleated cells, lymphohistiocytes, neutrophil in dermis (H&E ×400) (C, D) Septate, branching hyphae invading in dermis (PAS, GMS ×400)

Copyright@2022 by The Korean Society for Medical Mycology



Fig. 3. Fungal culture on Sabouraud dextrose agar (SDA) showed white to red-brown staining.

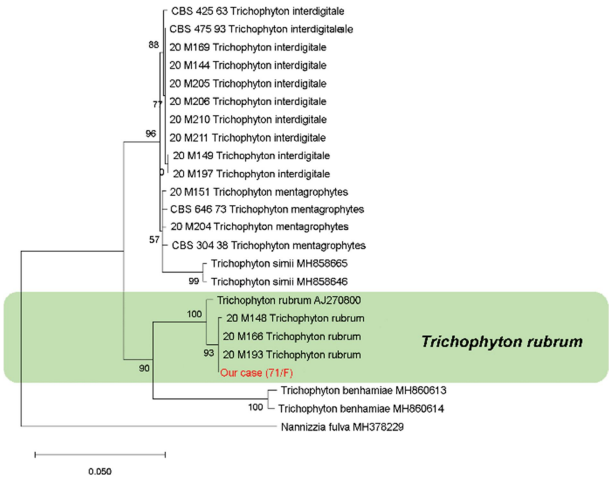

Fig. 4. Maximum Likelihood (ML) phylogenetic tree using internal transcribed spacer (ITS) and large subunit (LSU) region of ribosomal RNA gene

tissue showed red-brown pigmentation, suggesting *Trichophyton* species infection (Fig. 3). A molecular approach was used based on the sequence analysis of ribosomal DNA (rDNA). *T. rubrum* was identified by phylogenetic analysis using internal transcribed spacer and large subunit (LSU) region sequencing of ribosomal RNA gene (Fig. 4).

Before the identification of the causative organism, the patient's condition deteriorated because of septic shock. Amphotericin B was administered empirically for 6 days to prevent hematogenous dissemination, and the skin lesions resolved simultaneously (Fig. 1B).

DISCUSSION

Dermatophytes cause superficial infections of the skin and rarely cause deep infections invading the dermis in patients with acquired or innate immunosuppression. Most patients acquired immunosuppression are organ transplant recipients. However, it can occur in patients receiving immunosuppressive treatments for other diseases, such as interstitial lung disease[3] and rheumatoid arthritis, as observed in our case[4]. Recently, deep dermatophytosis has been reported in healthy individuals with a genetic predisposition to fungal organisms, such as those with autosomal recessive caspase recruitment domain-containing protein 9 (CARD9) deficiency[5] and C282Y mutation[6]. According to a recent systematic review, the most common predisposing factor for invasive dermatophytosis is superficial dermatophytosis, followed by solid organ transplantation, topical immunosuppressant use, gene mutation, diabetes mellitus, and trauma[1]. Deep dermatophytosis is classified into three types: (i) Majocchi granuloma, (ii) deeper dermal dermatophytosis, and (iii) disseminated dermatophytosis[6]. This case corresponded to deeper dermal dermatophytosis. In contrast to Majocchi granulomas, it is characterized by a rapidly growing lesion, commonly confined to the extremities without the involvement of other internal organs. Although the mechanism of fungal invasion in the dermis is yet to be clarified, the possibility of follicular invasion[7,8] or direct invasion from the epidermis into the dermis has been raised[3,9]. In most cases of deep dermatophytosis, *T. rubrum* is the most common causative agent; however, other species, such as *T. violaceum*, *T. mentagrophytes*, *T. verrucosum*, and *T. ferrugineum*, have also been found[1,7]. There is no established treatment for deep dermatophytosis; however, systemic antifungal drugs, such as terbinafine, itraconazole, and griseofulvin, are usually used. Although the treatment duration differs depending on each patient's immune status, most patients respond well to systemic antifungal drugs. In a recent study, terbinafine was recommended as the first-line treatment for immunocompromised patients as its administration is safer than azole drugs[10]. However, as resistance to antifungal drugs has increased recently, identifying the causative fungal patho-

gen is crucial. Combined treatment with multiple antifungal agents should be considered when genetic abnormalities, such as CARD9 deficiency, are present[1]. In this case report, before the pathogen was identified, the patient's systemic condition deteriorated rapidly. Therefore, systemic antibiotics and amphotericin B were simultaneously administered, and the skin lesions improved. Deep dermatophytosis can easily be mistaken for another disease, as it appears in various clinical manifestations. If treatment is delayed, immunocompetent patients can progress to a severe disease course, such as hematogenous dissemination. Hence, clinicians should differentiate this disease and conduct treatment at an appropriate time. Herein, we report a case of deep dermatophytosis in an immunocompromised patient who was successfully treated with amphotericin B.

ACKNOWLEDGEMENT

None.

CONFLICT OF INTEREST

In relation to this article, we declare that there is no conflict of interest.

ORCID

Jung Eun Seol: 0000-0002-3029-9635
Seong Min Hong: 0000-0002-8273-7350
Seung Hee Jang: 0000-0002-8343-209X
Sang Woo Ahn: 0000-0003-4820-3870
Jong Soo Choi: 0000-0003-3593-3970
Jeong Hwan Shin: 0000-0003-3960-6969
Jayoung Kim: 0000-0003-2977-1813
Hyojin Kim: 0000-0003-0987-4938

PATIENT CONSENT STATEMENT

The patient provided written informed consent for the publication and the use of her images.

REFERENCES

1. Wang R, Huang C, Zhang Y, Li R. Invasive dermatophyte infection: A systematic review. Mycoses 2021;64:340-348
2. Toussaint F, Sticherling M. Multiple dermal abscesses by *Trichophyton rubrum* in an immunocompromised patient. Front Med (Lausanne) 2019;6:97
3. Demidovich CW, Kornfeld BW, Gentry RH, Fitzpatrick JE. Deep dermatophyte infection with chronic draining nodules in an immunocompromised patient. Cutis 1995;55:237-240
4. Blank H, Smith JG Jr. Widespread *Trichophyton rubrum* granulomas treated with griseofulvin. Arch Dermatol 1960;81:779-789
5. Lanternier F, Pathan S, Vincent QB, Liu L, Cypowyj S, Prando C, et al. Deep dermatophytosis and inherited CARD9 deficiency. N Engl J Med 2013;369:1704-1714
6. Marconi VC, Kradin R, Marty FM, Hospenthal DR, Kotton CN. Disseminated dermatophytosis in a patient with hereditary hemochromatosis and hepatic cirrhosis: case report and review of the literature. Med Mycol 2010;48:518-527
7. Inaoki M, Nishijima C, Miyake M, Asaka T, Hasegawa Y, Anzawa K, et al. Case of dermatophyte abscess caused by *Trichophyton rubrum*: a case report and review of the literature. Mycoses 2015;58:318-323
8. Baker RL, Para MF. Successful use of ketoconazole for invasive cutaneous *Trichophyton rubrum* infection. Arch Intern Med 1984;144:615-617
9. Grossman ME, Pappert AS, Garzon MC, Silvers DN. Invasive *Trichophyton rubrum* infection in the immunocompromised host: report of three cases. J Am Acad Dermatol 1995;33:315-318
10. Rouzaud C, Chosidow O, Brocard A, Fraitag S, Scemla A, Anglicheau D, et al. Severe dermatophytosis in solid organ transplant recipients: a French retrospective series and literature review. Transpl Infect Dis 2018;20:e12799

Copyright@2022 by The Korean Society for Medical Mycology