CASE REPORT
J Mycol Infect 2022; 27(4): 82-84
pISSN:1226-4709, eISSN:2465-8278
https://dx.doi.org/10.17966/JMI.2022.27.4.82

JMI

Two Cases of Single-fingernail Fungal Leukonychia with Varying Manifestations

Su Min Lee, Sook Jung Yun and Jee-Bum Lee†

Department of Dermatology, Chonnam National University Medical School, Gwangju, Korea

Leukonychia is the white discoloration of the nail, and it is a common chromatic abnormality of the nail. Leukonychia can be caused by various systemic conditions; however, a fungal infection is also a probable cause. Herein, we report two cases that presented with varying patterns of single-nail leukonychia and were diagnosed with fungal leukonychia based on potassium hydroxide (KOH) examination and fungal culture. A 59-year-old man presented with asymptomatic complete whitish discoloration of the right fourth fingernail. KOH examination revealed many septate hyphae, and *Trichophyton rubrum* was identified through fungal culture and 18S rRNA sequencing. A 32-year-old man presented with asymptomatic longitudinal ridges and pitting with partial whitish discoloration of the second left fingernail persistent for 5 years. KOH examination revealed many short hyphae, and *Scedosporium* species was identified on fungal culture.

Key Words: Finger nail, Fungal leukonychia, *Scedosporium*, *Trichophyton rubrum*

INTRODUCTION

Leukonychia is a common abnormality of the nail with diverse etymologies, such as systemic diseases, hereditary causes, and dermatological conditions. Fungal infections are a possible cause of leukonychia; particularly, superficial white onychomycosis and primary subungual onychomycosis can make the nails white[1]. Fungal leukonychia usually affects the toenails, and in cases where fingernails are affected, concurrent toenail onychomycosis typically occurs[2]. We report two cases of single-fingernail leukonychia without toenail infections and other fingernail changes.

CASE REPORTS

A 59-year-old man with a history of pemphigus vulgaris presented with asymptomatic total whitish discoloration of the fourth right fingernail, the onset of which was several months ago (Fig. 1A, B). Except for the fourth nail on the right hand, no other fingernails or toenails were affected. This patient was receiving daily low-dose systemic steroids (5~10 mg methylprednisolone daily) since 2017 for pemphigus vulgaris. The patient's medical history was unremarkable for any treatment for fingernail abnormalities. To confirm onychomycosis, a nail potassium hydroxide (KOH) examination was performed, which revealed several septal mycelia. Fungal culture with subungual debris was performed on a Sabouraud dextrose agar (SDA) with cycloheximide. White fluffy colonies with a central umbo and a peripheral flat shape were

Received: September 4, 2022 Revised: September 24, 2022 Accepted: October 2, 2022
†Corresponding: Jee-Bum Lee, Department of Dermatology, Chonnam National University Medical School, 42 Jebong-ro, Dong-gu, Gwangju 61469, Korea.
Phone: +82-62-220-6684, Fax: +82-62-220-6685, e-mail: jbmlee@jnu.ac.kr
Copyright@2022 by The Korean Society for Medical Mycology. All right reserved.
This is an open-access article distributed under the terms of the Creative Commons Attribution Non-Commercial License (http://creativecommons.org/licenses/by-nc/3.0/), which permits unrestricted non-commercial use, distribution, and reproduction in any medium, provided the original work is properly cited. http://www.ksmm.org

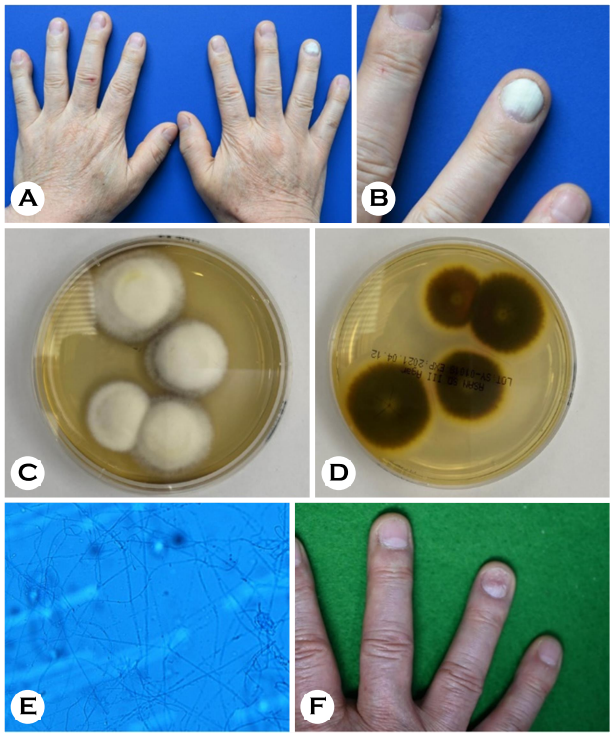

Fig. 1. (A) (B) Total whitish discoloration of right 4th fingernail in a 59-year-old male. (C) On Sabourade dextrose agar (SDA) with cycloheximide, white fluffy colonies with central umbo and peripheral flattened appearance were observed from the upper side. (D) In the bottom view, brownish to wine red color was showed. (E) In lactophenol cotton blue stain (LCBS), microconidia along the lateral side of the hyphae (F) After 3 months treatment, improvement of nail lesion was observed.

Primer Information

Sequencing Primer Name Primer Sequences	PCR Primer Name Primer Sequences
NS1 5' (GTA GTC ATA TGC TTG TCT C) 3'	NS1 5' (GTA GTC ATA TGC TTG TCT C) 3'
NS8 5' (TCC GCA GGT TCA CCT ACG GA) 3'	NS8 5' (TCC GCA GGT TCA CCT ACG GA) 3'

Subject						Score		Identities	
Accession	Description	Length	Start	End	Coverage	Bit	E-Value	Match/Total	Pct. (%)
LC369522.1	*Trichophyton rubrum*	3055	15	1673	54	3046	0.0	1656/1659	99

Kingdom	Family	Genus	Species
Eukaryota	Arthrodermataceae	*Trichophyton*	*Trichophyton rubrum*

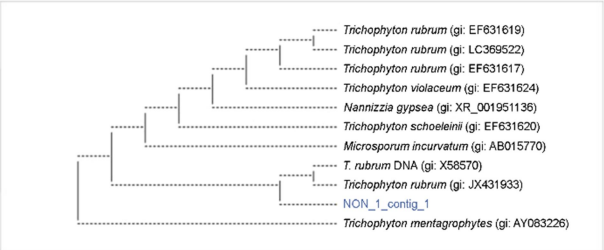

Fig. 2. As a result of 18s rRNA sequencing, *Trichophyton rubrum* was identified as the causative fungus.

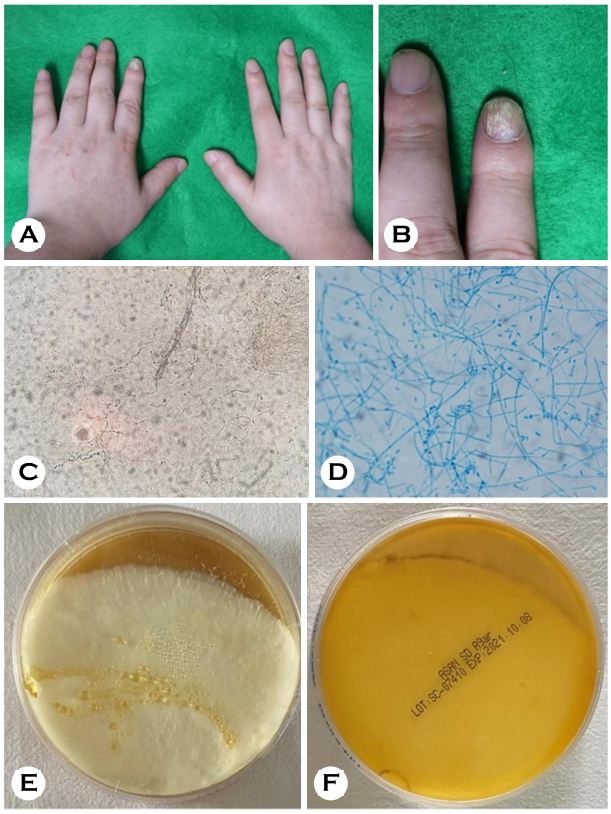

Fig. 3. (A) (B) Asymptomatic longitudinal ridges and pitting with partial whitish discoloration on left 2nd fingernail in a 32-year-old male (C) Many short hyphae with septum were observed on KOH examination. (D) In LCBS, oval shape of conidia were observed. (E) (F) On Sabourade dextrose agar (SDA), white cottony colonies were observed in the top and bottom view.

observed from the top view of the SDA plate, and a brownish to wine-red color was observed in the bottom view (Fig. 1C, D). Furthermore, microconidia were observed along the lateral side of the hyphae on lactophenol cotton blue stain (LCBS) (Fig. 1E). *Trichophyton rubrum* was suspected as the causal organism, and 18S rRNA sequencing revealed *Trichophyton rubrum* as a significant pathogen (Fig. 2). We grinded the nail surface to allow the drug to permeate well. The nail lesion improved after the application of topical efinaconazole for 3 months (Fig. 1F).

A 32-year-old man presented with asymptomatic longitudinal ridges and pitting with partial whitish discoloration on the left second fingernail for 5 years (Fig. 3A, B). The patient's medical history was unremarkable. Although he was treated with oral medication at a private clinic, no improvement was observed. The fingernail had fallen out several

times. KOH examination revealed several short hyphae (Fig. 3C). White cottony colonies were observed from the top and bottom views of the fungal culture on SDA (Fig. 3E, F). Oval-shaped conidia were observed on LCBS (Fig. 3D). Therefore, the *Scedosporium* species was identified as a causal organism. After 2 months of oral terbinafine combined with topical efinaconazole treatment, the fingernail lesion improved.

DISCUSSION

Leukonychia manifests as whitish discoloration of the nail. Its etymology ranges from genetic to acquired, such as fungal infections. Leukonychia can be caused by nail plate or nail bed abnormalities. True leukonychia and pseudo-leukonychia are caused by nail plate abnormalities, and apparent leukonychia, such as Terry's nail, are caused by nail bed abnormalities. Among fungal infections, proximal subungual onychomycosis and white superficial onychomycosis cause leukonychia, both of which originate from nail plate abnormalities[1].

The clinical features of the two patients were white superficial onychomycosis, in which they showed a superficial white patch on the nail plate.

According to Piraccini and Tosti, *Trichophyton interdigitale* is the most common causal organism in white superficial onychomycosis[2]. White superficial onychomycosis due to *Trichophyton interdigitale* always involves the toenails, usually the first one, and presents as 1~5 small whitish opaque friable patches on the nail. *Trichophyton rubrum* was found to be the cause in four of 79 patients[2]. In our cases, *Trichophyton rubrum* was found to be the causal organism in the first patient as well.

In the report by Piraccini and Tosti, 21% of the cases of white superficial onychomycosis were caused by nondermatophytes[2]. In the second patient, *Scedosporium*, a nondermatophyte, was found to be the causal agent. Although rare, *Scedosporium* has been reported to be the causal fungus in onychomycosis[3].

The involvement of more than one fingernail without a concomitant toenail infection is rare in onychomycosis, unless the patient experienced trauma or is immunosuppressed[4].

White superficial onychomycosis typically affects ≥1 toenails, most commonly the first, second, and third toenails. The involvement of the fingernails in adults has rarely been described[5].

In our cases, the first patient was on prolonged systemic steroid treatment after the diagnosis of pemphigus. Although the second patient had no history of trauma, he complained of frequent nail loss. Both patients showed the involvement of only one fingernail, and these cases were uncommon, in whom no other nails were affected.

In summary, both patients showed leukonychia on one nail without the involvement of any other nails, although the cause was a fungal infection. Our report suggests that fungal causes should be suspected in leukonychia of the nail, and KOH examination and fungal culture should be performed for an accurate diagnosis.

CONFLICT OF INTEREST

In relation to this article, we declare that there is no conflict of interest.

ORCID

Su Min Lee: 0000-0002-9322-5596
Sook Jung Yun: 0000-0003-4229-5831
Jee-Bum Lee: 0000-0002-1477-4037

PATIENT CONSENT STATEMENT

The patient provided written informed consent for the publication and the use of his images.

REFERENCES

1. Grossman M, Scher RK. Leukonychia. Review and classification. Int J Dermatol 1990;29:535-541
2. Piraccini BM, Tosti A. White superficial onychomycosis: epidemiological, clinical, and pathological study of 79 patients. Arch Dermatol 2004;140:696-701
3. Issakainen J, Heikkilä H, Vainio E, Koukila-Kähkölä P, Castren M, Liimatainen O, et al. Occurrence of *Scopulariopsis* and *Scedosporium* in nails and keratinous skin. A 5-year retrospective multi-center study. Med Mycol 2007; 45:201-209
4. Gupta AK, Stec N, Summerbell RC, Shear NH, Piguet V, Tosti A, et al. Onychomycosis: a review. J Eur Acad Dermatol Venereol 2020;34:1972-1990
5. Kornbleuth S, Hsu S. White superficial onychomycosis of the fingernail caused by *Trichophyton rubrum* in an immunocompetent patient. Cutis 1999;64:99-100

Copyright@2022 by The Korean Society for Medical Mycology