

## Tinea Corporis Caused by *Trichophyton verrucosum* Mimicking Nummular Dermatitis

Jun Suk Hong<sup>1</sup>, Dong Won Lee<sup>1</sup>, Moo Kyu Suh<sup>1†</sup>, Gyoung Yim Ha<sup>2</sup>, Tae Jung Jang<sup>3</sup> and Jong Soo Choi<sup>4</sup>

<sup>1</sup>Department of Dermatology, College of Medicine, Dongguk University, Gyeongju, Korea

<sup>2</sup>Department of Laboratory Medicine, College of Medicine, Dongguk University, Gyeongju, Korea

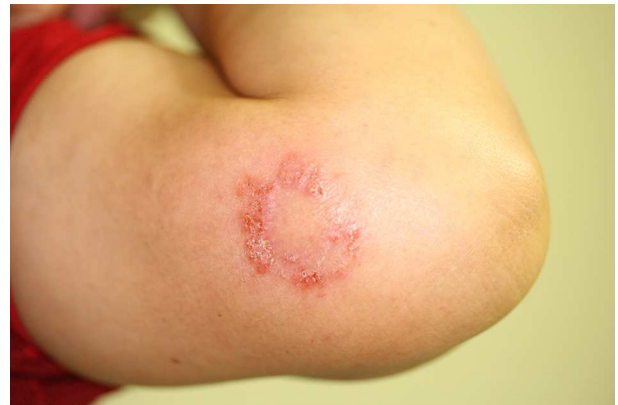<sup>3</sup>Department of Pathology, College of Medicine, Dongguk University, Gyeongju, Korea

<sup>4</sup>Department of Dermatology, College of Medicine, Yeungnam University, Daegu, Korea

Many skin conditions present as cutaneous annular lesions, thereby complicating the diagnosis based on the physical appearance alone<sup>1</sup>. As a typical example of annular lesions, nummular dermatitis presents as well-demarcated coin-shaped annular plaques formed from coalescing papules and papulovesicles. Another example of annular lesions is seen in tinea corporis, which is a superficial dermatophyte infection that can occur on any cutaneous surface, except the hands, feet, scalp, or groin; it presents as an erythematous annular plaque with a scaly, centrifugally advancing border<sup>1,2</sup>. The presentations of nummular dermatitis and tinea corporis are so similar that tinea corporis is often mistaken for nummular dermatitis, and a potassium hydroxide (KOH) preparation of the skin scrapings may help distinguish between the two conditions<sup>1</sup>. However, in atypical manifestations of tinea corporis, such as vesiculopustular lesion, the accurate diagnosis can be missed because the clinical signs and symptoms of tinea corporis are neither sensitive nor specific for dermatophytosis<sup>2,3</sup>. In particular, cutaneous lesions caused by *Trichophyton verrucosum*, which is the most common causative pathogen of dermatophytosis in cattle, are usually characterized clinically by intense inflammation because of which these lesions are often misdiagnosed as eczema<sup>4,5</sup>. Besides, in atypical cases of tinea corporis, the diagnosis can be even missed by false negative results from KOH analysis or culture. In such cases, definitive diagnosis can

easily be confirmed histologically on the basis of the presence of PAS-positive fungi in the stratum corneum or hair follicle<sup>2</sup>.

A 58-year-old female cattle keeper presented with a solitary, pruritic, 3.0 × 3.0-cm sized erythematous annular plaque with central clearing and a vesicular border on the left upper arm at one month after its emergence (Fig. 1). The results of KOH examination on the left upper arm lesion were negative. Therefore, we cultured and performed a biopsy for a definitive



**Fig. 1.** A solitary, pruritic, 3.0 × 3.0-cm sized erythematous annular plaque with central clearing and vesicular border on the left upper arm

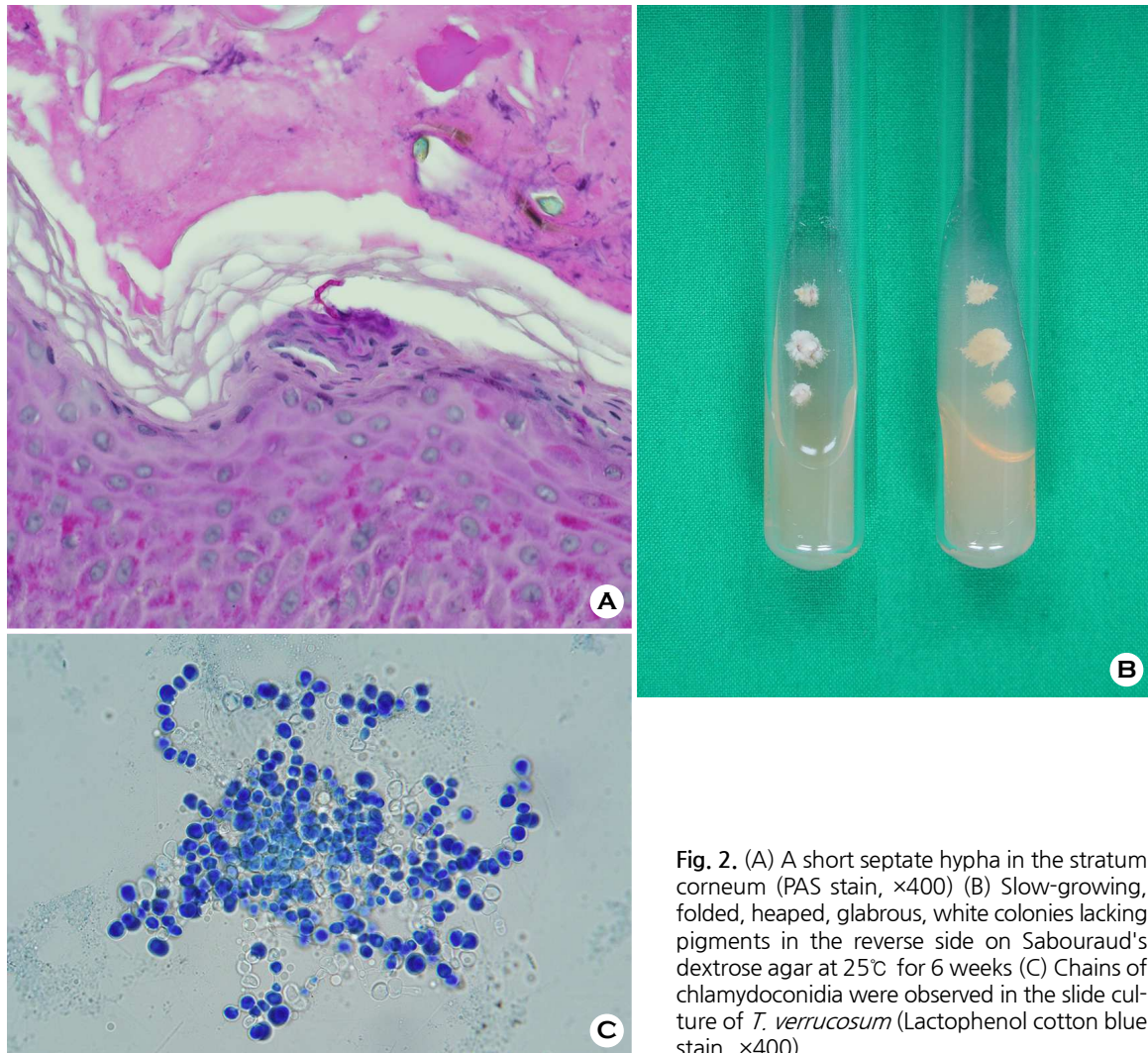
Received: December 4, 2018 Revised: December 16, 2018 Accepted: February 11, 2019

†Corresponding: Moo Kyu Suh, Department of Dermatology, College of Medicine, Dongguk University, 87 Dongdae-ro, Gyeongju, Kyungbuk, 38067, Korea.

Phone: +82-10-3805-9223, Fax: +82-54-770-8378, e-mail: smg@dongguk.ac.kr

Copyright©2019 by The Korean Society for Medical Mycology. All right reserved.

©This is an open-access article distributed under the terms of the Creative Commons Attribution Non-Commercial License (<http://creativecommons.org/licenses/by-nc/3.0/>), which permits unrestricted non-commercial use, distribution, and reproduction in any medium, provided the original work is properly cited. <http://www.ksmm.org>



**Fig. 2.** (A) A short septate hypha in the stratum corneum (PAS stain,  $\times 400$ ) (B) Slow-growing, folded, heaped, glabrous, white colonies lacking pigments in the reverse side on Sabouraud's dextrose agar at  $25^{\circ}\text{C}$  for 6 weeks (C) Chains of chlamydoconidia were observed in the slide culture of *T. verrucosum* (Lactophenol cotton blue stain,  $\times 400$ ).

diagnosis. Histopathological analysis revealed short septate hyphae in the stratum corneum (Fig. 2A). Cultures from skin biopsy specimens on Sabouraud's dextrose agar yielded slow-growing, folded, heaped, glabrous, and white colonies, which lacked pigments in the reverse side after 6 weeks (Fig. 2B). Chains of chlamydoconidia were observed in the slide culture on microscopic examination (Fig. 2C). The nucleotide sequence of the internal transcribed spacer of the clinical isolate was identical to that of *T. verrucosum* strain CBS 562.50 (GenBank accession number MH856755). The patient was treated with 100 mg of oral itraconazole daily for 1 month, and the skin lesion improved completely.

We diagnosed tinea corporis caused by *T. verrucosum* mimicking nummular dermatitis on the basis of clinical findings, pathological findings, fungal culture, and molecular biological

analysis. We have reported this case to emphasize the importance of fungal culture and histopathological examination for accurate diagnosis in atypical and difficult cases.

**Key Words:** Nummular dermatitis, Tinea corporis, *Trichophyton verrucosum*

## CONFLICT OF INTEREST

In relation to this article, we declare that there is no conflict of interest.

## ORCID

Jun Suk Hong: 0000-0001-8033-8260  
Dong Won Lee: 0000-0002-6006-9670  
Moo Kyu Suh: 0000-0002-7629-8363  
Gyoung Yim Ha: 0000-0003-4767-2333  
Tae Jung Jang: 0000-0003-3789-8152  
Jong Soo Choi: 0000-0003-3593-3970

## REFERENCES

1. Traves KP, Savage K, Studdiford JS. Annular lesions: diagnosis and treatment. *Am Fam Physician* 2018;98:283-291
2. Ziemer M, Seyfarth F, Elsner P, Hipler UC. Atypical manifestations of tinea corporis. *Mycoses* 2007;50 Suppl 2: 31-35
3. Kelly BP. Superficial fungal infections. *Pediatr Rev* 2012; 33:e22-37
4. Roman C, Massai L, Gianni C, Crosti C. Case reports. six cases of infection due to *Trichophyton verrucosum*. *Mycoses* 2001;44:334-337
5. Hong JS, Lee DW, Suh MK, Ha GY. Macroscopic and microscopic findings of *Trichophyton verrucosum* isolated from cattle. *J Mycol Infect* 2018;23:118-119