Korean J Med Mycol 22(4), 2017
http://dx.doi.org/10.17966/KJMM.2017.22.4.188

Computed-Tomography Findings of Aspergilloma

Yong Woo Choi[1], Joonsoo Park[1] and Hyun Hee Kwon[2†]

Department of Dermatology, School of Medicine, Catholic University of Daegu, Daegu, Korea[1]
Department of Internal Medicine, School of Medicine, Catholic University of Daegu, Daegu, Korea[2]

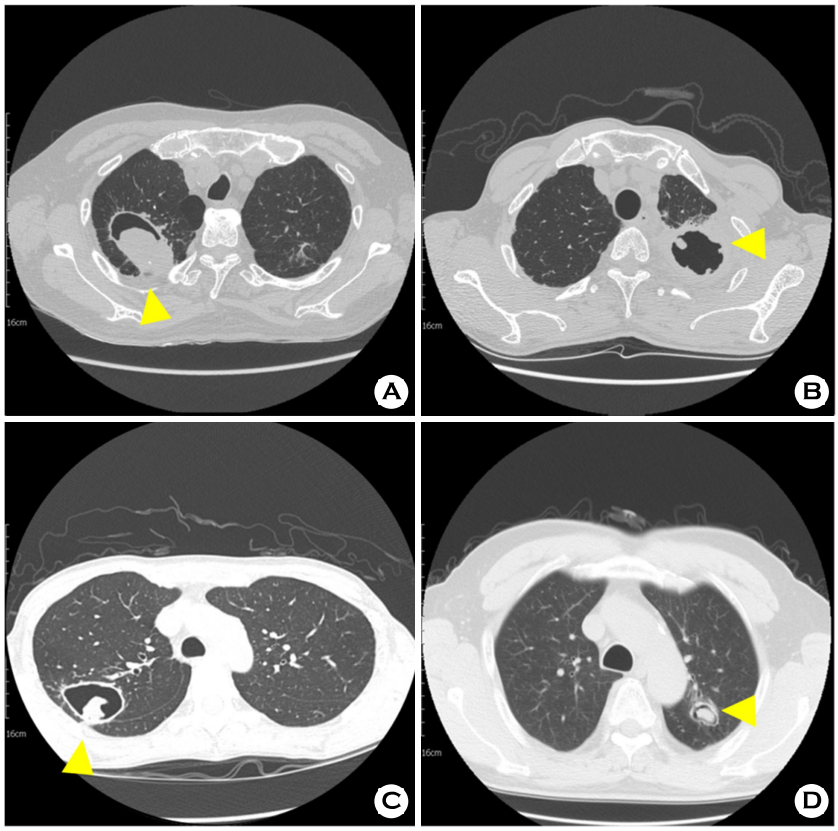

Fig. 1. A: The axial view of CT scan shows large cavitary nodule with air crescent formation in right upper lobe (Yellow arrow). **B:** The axial view of CT scan shows large cavity containing small fungus balls in left upper lobe (Yellow arrow). **C:** The axial view of CT scan shows large cavitary nodule with air crescent formation in right upper lobe (Yellow arrow). Few fibrotic changes are presented. **D:** The axial view of CT scan shows small cavitary nodule with air crescent formation in left upper lobe (Yellow arrow). Few fibrotic changes are presented.

Received: September 30, 2017, Revised: October 19, 2017, Accepted: October 24, 2017
†Corresponding author: Hyun Hee Kwon, Department of Internal Medicine, School of Medicine, Catholic University of Daegu, 33 Duryugongwon-ro 17gil, Namgu, Daegu, 42472, Korea.
Tel: +82-53-650-4708, Fax: +82-53-650-4891, e-mail: heeya0035@naver.com
Copyright@2017 by The Korean Society for Medical Mycology (pISSN:1226-4709, eISSN:2465-8278). All right reserved.
This is an open-access article distributed under the terms of the Creative Commons Attribution Non-Commercial License(http://creativecommons.org/licenses/by-nc/3.0/), which permits unrestricted non-commercial use, distribution, and reproduction in any medium, provided the original work is properly cited. http://www.ksmm.org

Aspergillosis is a mycotic disease caused by *Aspergillus* species, usually *Aspergillus fumigatus*[1]. Saprophytic aspergillosis, so called aspergilloma, is characterized by *Aspergillus* infection without other tissue invasion[2]. Aspergilloma typically leads to conglomeration of interrelated fungal hyphae admixed with mucus and cellular debris within a preexistent pulmonary cavity or bronchus[2]. At computed tomography (CT), mycetomas are characterized by the existence of a solid, round or oval mass with soft-tissue opacity within a lung cavity[2].

The "air crescent" sign is the mass that separated from the wall of the cavity by an airspace of variable size and shape[3]. Other causes of the air crescent sign include angioinvasive aspergillosis, echinococcal cyst, and rarely, tuberculosis, tuberculosis cavity, lung abscess, bronchogenic carcinoma, and *P. carinii* pneumonia[3]. The mass is typically spherical or ovoid, and usually moves when the patient changes position[2,3]. In axial sections of CT scan shows a relatively thin walled cavity containing a hyperdense soft tissue accentuation with surrounding air lucency. Few fibrotic changes are seen surrounding the cavity (Fig. 1-A, B, C, D).

Aspergillosis is a serious complication that is frequently seen in immunocompromised patients[2]. Although CT findings in various type of pulmonary aspergillosis may be nonspecific, in the appropriate clinical setting, familiarity with the thin-section CT findings may help establish the specific diagnosis.

[Korean J Med Mycol 2017; 22(4): 188-189]

Key Words: Aspergilloma, Aspergillosis, Fungus ball

Conflict of interest

In relation to this article, I declare that there is no conflict of interest.

REFERENCES

1. Franquet T, Müller NL, Giménez A, Guembe P, de La Torre J, Bagué S. Spectrum of pulmonary Aspergillosis: Histologic, cinical, and radiologic findings. Radiographics 2001;21:825-837
2. Godet C, Laurent F, Bergeron A, Ingrand P, Beigelman-Aubry C, Camara B, et al. CT imaging assessment of response to treatment in chronic pulmonary aspergillosis. Chest 2016;150:139-147
3. Raju S, Ghosh S, Mehta AC. Chest CT sighs in pulmonary disease: A pictorial review. Chest 2017; 151:1356-1374