대한의진균학회지 제 3권 제 1호 1998

■ Invited Article ■

Pityrosporum (Malassezia) Related Diseases Especially Seborrheic Dermatitis

Yoshihiro Sei, Ayumu Oshima, Atuhiro Nakabayashi, Taizo Hamaguchi, Junya Ninomiya and Takasi Iizuka

Department of Dermatology, Showa University Fujigaoka Hospital

=Abstract=

The cause of seborrheic dermatitis is unknown, although many attempts have been made to relate it to infection with bacteria or with *Malassezia furfur*. Recently, there have been many studies concerning the efficacy of anti-fungal agents against seborrheic dermatitis. In this occasion, I introduce the result of studies concerning the efficacy of anti-mycotic drugs against dandruff and seborrheic dermatitis in Japan and in our outpatient clinic of dermatology. I also report the results of our laboratory studies concerning the mechanism of seborrheic dermatitis.

We produced the animal models of seborrheic dermatitis. Lesions in immunized guinea pigs developed faster than those of non immunized guinea pigs. The anti-Malassezia IgY seems to delay the development of the lesion.

Malassezia spores were detected from lesional skin by direct light microscopy method in our outpatient clinic. Approximately 85% of the facial sites and 75% of the scalp sites were positive in total.

One of our clinical studies was a double-blind, comparative study conducted at 8 institutions on the usefulness of shampoo containing 0.75% miconazole nitrate (MZS) for the treatment of dandruff. Shampoo vehicle (BSS) without the reagent served as the control. MZS was evaluated as useful in 34 of the 58, and BSS in 19 of the 50 subjects, thus MZS was significantly more useful than BSS (p=0.020).

The other clinical study concerned on the efficacy of ketoconazole cream used in 168 patients for the treatment of seborrheic dermatitis. This study was done as an open trial by multiple institutes. Approximately 80% evaluated as effective, in total. In 23 valuable cases, fungus disappeared in 16 cases (69.6%).

It is concluded that anti-fungal agents have potential value as a new therapeutic agent -an alternative to steroids- for the treatment of seborrheic dermatitis. **[Kor J Med Mycol 3(1): 15-23]**

Key Words: *Malassezia furfur*, Seborrheic dermatitis

INTRODUCTION

Genus *Malassezia* is one of the members of the human skin flora. This genus is also implicated in several skin diseases such as tinea versicolor, *Pityrosporum (Malassezia)* folliculitis, seborrheic dermatitis, psoriasis vulgaris and atopic dermatitis[1]. In tinea versicolor or *Pityrosporum (Malassezia)* folliculitis, it is clear

Corresponding author: Yoshihiro Sei, M.D., Department of Dermatology, Showa University Fujigaoka Hospital, Fujigaoka 1-30, Aobaku, Yokohama, 227-8501 JAPAN

that the genus *Malassezia* is the causative agent of the disease.

Concerning atopic dermatitis, several studies now indicate that genus *Malassezia* may be an important allergen in some patients, especially in adult patients with the head and the neck distribution of the disease[2]. Two years ago, I reported the relationship between *Malassezia* and atopic dermatitis at the 9th Korea-Japan joint meeting of dermatology in Pusan. My conclusion was that *Malassezia* exacerbated atopic dermatitis in parts of head and neck.

Seborrheic dermatitis has a characteristic distribution in areas with a rich supply of sebaceous glands. The cause of seborrheic dermatitis is unknown, although there have been many studies concerning the efficacy of antifungal agents against seborrheic dermatitis[3~6]. On this occasion, I will report the results of the study conducted in Japan on the effectiveness of the shampoo[7] and cream[8~10]. The relationship between the improvement in clinical symptoms, such as dandruff and pruritus, and the decrease in the number of *Malassezia*, that is mycological response is examined in particular. Also, I present data from our laboratory investigations on part of the mechanisms of seborrheic dermatitis[11,12].

SEBORRHEIC DERMATITIS; IT'S CLINICAL SIGNS AND DIAGNOSIS

Clinical signs: Seborrheic dermatitis has a characteristic distribution in areas with a rich supply of sebaceous glands, namely the scalp, face, nose, ear and upper trunk[6]. The lesions are red and covered with greasy scales. Figure 1 shows the clinical appearance of seborrheic dermatitis on the face.

Histopathology: Figure 2 shows the histology of seborrheic dermatitis. The horny layer shows parakeratosis mainly surrounding the hair follicle. In the epidermis, slight to moderate acanthosis and spongiosis can be seen. The dermis shows mild chronic inflammatory infiltrates. Figure 3 shows the spores in the hair follicle of seborrheic dermatitis.

Differential diagnosis: For differential diagnosis of seborrheic dermatitis, we have to take details of case history. Contact dermatitis, atopic dermatitis and collagen diseases have to be differentiated. For this purpose, we usually use a "sebumeter" which easily measures the total sebum level on skin surface. In addition to the sebum level, we detect the fungal elements within the lesion.

Detection methods: To detect the fungal elements within the scales of patient's skin especially on the scalp and face, we usually use potassium hydroxide containing Parker's blue-black ink (Parker-KOH). In the scales of patients, some of them are oval type spores and the others are orbicular type spores. Figure 4 shows the spores detected in the scales. In some instances, those two types are observed within the same scales. The oval type spores are difficult to detect under a light microscope just after staining with the Parker-KOH. However after 15 minutes or more, they can be observed in the scales.

A count of over 10 spores per one high power field is defined as positive[13]. It is very important to set correctly the iris diaphragm of substage condenser. When the iris diaphragm is closed, like the same way to detect the dermatophytes, one can not detect the spores within the samples. Only when the iris diaphragm is opened, one may be able to detect many spores within the same samples. Figure 5 is the photograph of scanning electron microscopy of lesional skin of seborrheic dermatitis. Spores were sighted mainly between the horny cells.

Spore positive ratio by sex and site was presented on Figure 6. In the males, 99 of the 109 facial sites and 94 of the 123 scalp sites were positive. In the females, 13 of the 23 facial sites and 27 of the 39 scalp sites were positive. Approximately 85% of the facial sites and 75% of the scalp sites were positive in to-

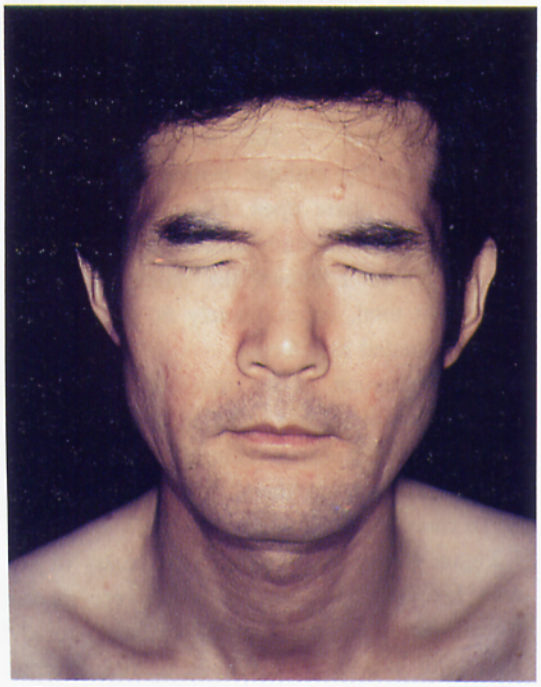

Fig. 1. The clinical manifestations of seborrheic dermatitis.

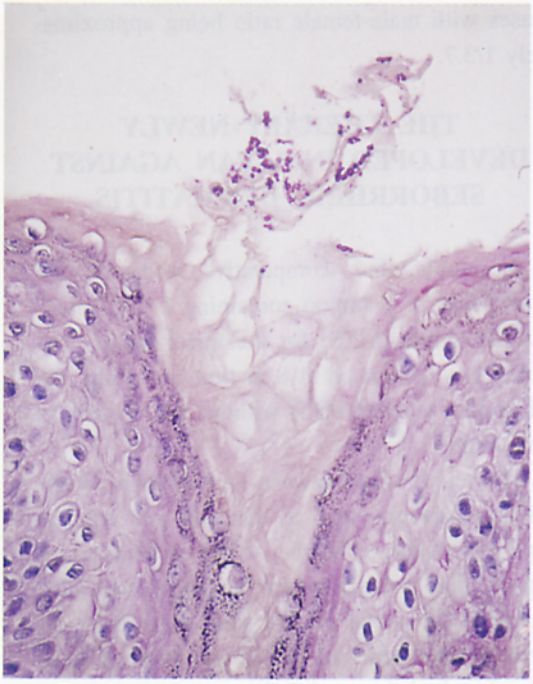

Fig. 3. PAS positive spores in the hair follicle of seborrheic dermatitis.

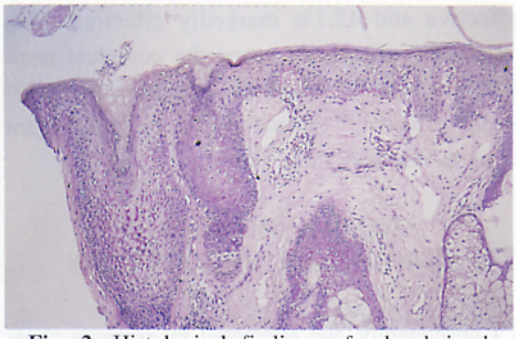

Fig. 2. Histological findings of seborrheic dermatitis.

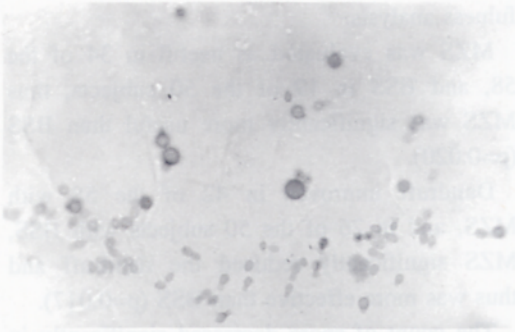

Fig. 4. Spores stained with Parker-KOH in the scale of seborrheic dermatitis.

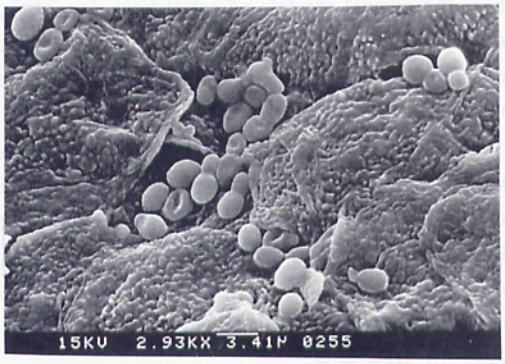

Fig. 5. Scanning electron micrograph of spores in the scale of seborrheic dermatitis.

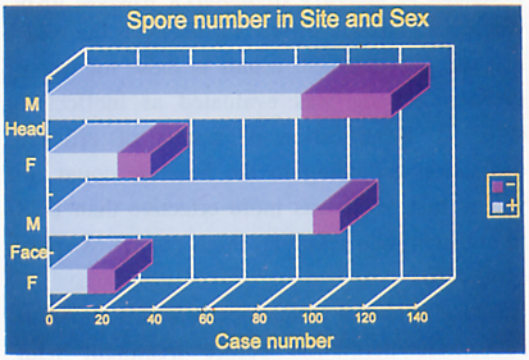

Fig. 6. Spore positive ratio by sex and site.

tal. There were 232 male cases and 62 female cases with male-female ratio being approximately 1/3.7.

THE THERAPY NEWLY DEVELOPED IN JAPAN AGAINST SEBORRHEIC DERMATITIS

A double-blind, comparative study on the usefulness of shampoo containing 0.75% miconazole nitrate (MZS) for the treatment of dandruff was conducted at 8 institutions, using the shampoo vehicle (BSS) without the reagent as the control[7].

The relationship between improvement in clinical symptoms (such as dandruff and itching) and the decrease in the count of *Malassezia* spore (that is mycological response) was also studied. Of a total of 134 subjects studied, 58 were shampooed with MZS, and 50 with BSS. One hundred thirty of these were included in a safety analysis, and 108 in an efficacy and usefulness analysis.

MZS was evaluated as useful in 34 of the 58, and BSS in 19 of the 50 subjects, thus MZS was significantly more useful than BSS (p=0.020).

Dandruff improved in 42 of the 58 with MZS, and in 26 of the 50 subjects with BSS, MZS significantly reduced the dandruff and thus was more effective than BSS (p=0.017).

The count of spore decreased significantly in the subjects for whom the shampooing was evaluated as effective (p=0.0001), whereas there was no significant difference between the baseline and post-treatment counts in those for whom the shampooing was evaluated as ineffective (Fig. 7). Stratification of results of efficacy evaluation according to the baseline count revealed that MZS was more effective than BSS in subjects with relatively high counts of spore (p=0.038).

Figure 8 shows the clinical manifestations of seborrheic dermatitis before treatment with anti-fungal cream. The complete resolution of lesions was observed after treatment for two weeks (Fig. 9).

A topical anti-fungal agent, ketoconazole cream, was used in 168 patients with seborrheic dermatitis[8~10]. This study was done as an open trial by multiple institutes. This study includes the phase open, bilateral-paired comparison, long-term study and mycological evaluation. Table 1 shows the summary of efficacy. In total, approximately 80% of lesions were evaluated as effective.

The evaluation of the mycological efficacy of ketoconazole cream revealed that fungus decreased or disappeared (culture) in all 23 valuable cases. Among them, fungus disappeared in 16 cases (69.6%).

Figure 10 shows the efficacy summary in our own hospital. 312 sites, in total, were treated by different manners. Steroid was used for 77 sites with excellent therapeutic results. In contrast to that, anti-fungal agent resulted 3% exacerbated, 5.1% ineffective, 50% moderately effective and 42.1% markedly effective. This "markedly effective" means the complete resolution of lesions. When one compares the "markedly effective" cases only, anti-fungal agent is more effective than steroid.

ANIMAL MODELS OF SEBORRHEIC DERMATITIS

Consequently, we attempted to examine some mechanisms of developing the lesion. To produce the animal models of seborrheic dermatitis, we apply the fungal solution onto the back and the ears of guinea pigs. The details have been reported in the literature[11,12].

Strain: *M. furfur* isolated and identified from patients with seborrheic dermatitis is processed in Dixon's broth (bactoxigal 20 g, malt extract 40 g, glycerol 2.5 ml, tween 40 10 ml in 1 L of water). Fungal elements were harvested and washed with physiological salt solution and diluted for 20% w/w.

Animals: 21 male Hartley strain guinea pigs

Table 1. Summary of efficacy in patients treated with ketoconazole cream

Location	No. of patient	Percent
Head	29/43	67.4
Face	77/89	86.5
Auricle	6/10	60.0
Armpit	6/6	100
Trunk	1/2	50
Total	119/150	79.3

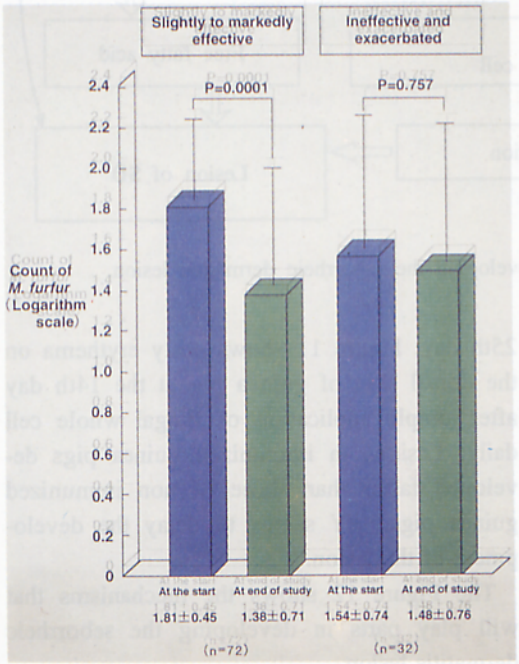

Fig. 7. Changes in count of *M. furfur* and efficacy.

Fig. 8. Clinical manifestations before treatment with anti-fungal cream.

Fig. 9. Clinical manifestations -2 weeks after treatment by anti-fungal cream.

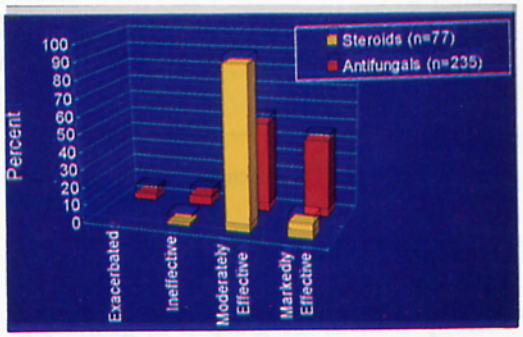

Fig. 10 Efficacy of steroids and anti-fungal agent in our own hospital.

Fig. 11. Experimental production of seborrheic dermatitis like lesions in guinea pigs. This photograph shows scaly erythema on the dorsal skin of guinea pig at the 14th day after daily application of whole fungal cells.

(Group A-E) were used.

Methods of Examination:

Using guinea pigs:

Group A: Guinea pigs were infected daily for 4 weeks on the shaved skin in the middle

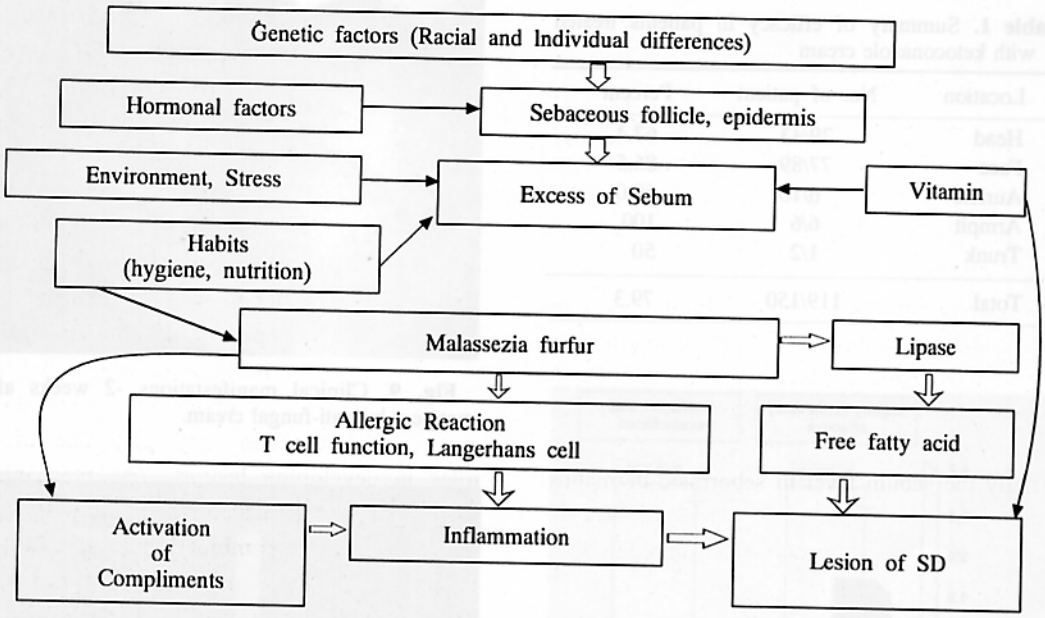

Fig. 12. The mechanisms that play parts in developing the seborrheic dermatitis lesion.

of the back with an inoculum (100 μl) without occlusion.

Group B-E: In the group B-E, guinea pigs were immunized to *M. furfur* by inoculation with occlusion for 48 hours once a week for 3 times. Thereafter, in Group B, guinea pigs were infected in the same manner as group A. And in Group C-E, guinea pigs were infected daily for 4 weeks on the shaved skin in the middle of back with an inoculum (50 μl) without occlusion. Three kinds of IgY were applied; namely, in Group C, IgY against cytosol of *M. furfur*, in Group D, IgY against cell wall of *M. furfur* and in Group E, IgY against whole cell of *M. furfur* was used respectively.

Production of Specific IgY against *M. furfur*:

1. Hen is immunized against cytosol, cell wall and whole cell of *M. furfur*.

2. IgY in egg yolk is purified by λ-carrageenan method.

Results: Seborrheic dermatitis-like lesions were observed on the back and the ears in some guinea pigs after 7 days. Erythema had appeared on 9/12 backs and 10/12 ears on the 25th day. Figure 11 shows scaly erythema on the dorsal skin of guinea pig at the 14th day after simple application of fungal whole cell daily. Lesions in immunized guinea pigs developed faster than those of non immunized guinea pigs. IgY seems to delay the development of the lesion.

The Figure 12 shows the mechanisms that will play parts in developing the seborrheic dermatitis lesion.

CONCLUSION

When we observe the erythematous skin rash of head and face, we usually diagnose atopic dermatitis, photodermatoses, collagen disease, contact dermatitis or seborrheic dermatitis. When the lesion is limited to head and face and the oily scales are observed, almost all of these cases can be diagnosed as seborrheic dermatitis. To confirm diagnosis of tinea versicolor, it is indispensable to conduct a direct identification of fungal elements. Likewise, we attempt a direct examination for the fungal elements in lesion of seborrheic dermatitis[14]. There

are many studies reporting that the number of spore is not different from lesional skin or healthy skin[15]. These reports are mainly based on culture of pathogens. Our results of direct examination, on the contrary, revealed that in seborrheic dermatitis, there are many spores in the lesion compared to non-lesional skin or healthy person.

We have also measured the total sebum of the skin by a sebumeter. Seborrheic dermatitis develops under the excess amount of sebum. The results of the sebumeter measurements are almost equal to the results of Bergbrant[15]. Briefly the sebum level in seborrheic dermatitis skin was 150 μg/cm^2, in contrast to that in healthy skin 100 μg/cm^2 and that in atopic dermatitis skin 60 μg/cm^2 respectively[16]. In patients with seborrheic dermatitis the sebaceus glands are often enlarged. Seborrheic dermatitis appears to be associated with parkinsonism where sebum excretion is increased[6].

Concerning histopathology of the seborrheic dermatitis, the picture varies according to the stage of the disease. Clinically, seborrheic dermatitis does not reveal characteristic feature, therefore the histological appearance of seborrheic dermatitis is not characteristic. It is said to be halfway between psoriasis and spongiotic dermatitis. The most important diagnostic signs of seborrheic dermatitis are mounds of scale-crusts containing neutrophils at the tips of the dilatated horn-filled follicular infundibula[6].

The experimental production of seborrheic dermatitis-like lesions on rabbits and guinea pigs has been reported.

Characteristics of IgY are as follows[17]:

1. In immunized hen, a specific antibody is produced and transferred to egg yolk.

2. It is easy to purify the antibody, because IgY exists only in egg yolk, thus, the procedure is suitable for mass production.

3. It belongs to IgG class, but It is different form human IgG in following parameters.

a. Molecular weight is 180,000 (IgG; 150,000).

b. Its' isoelectric point is 1 lower in pH than that of IgG.

c. It cannot activate compliment in mammalian species.

d. It has less affinity to protein A and rheumatoid factor than IgG does.

We think that IgY coats the surface of *M. furfur* antigen after pre-incubation. Subsequently, IgY is gradually released because of the skin's ability to shed water to develop inflammation. Previous authors speculated on the various mechanisms of seborrheic dermatitis. Our results of animal model explain that the delayed type allergic reaction may play one of the roles in developing lesions. The mechanisms to develop or to exacerbate the lesion by *M. furfur* may be the combination of delayed type hypersensitivity and non-immunological response such as activation of complement or irritation with free fatty acids.

Anti-fungal agent showed the excellent result when compared with steroid. This result may be the consequence to decrease in the fungal elements within lesions. Among many of the drugs, ketoconazole is widely used drug to fight seborrheic dermatitis[3~6]. This has been confirmed by a double blind study[3~4].

Consequently the Ministry of Health and Welfare in Japan has approved ketoconazole cream for the treatment of seborrheic dermatitis on 2nd July 1997. In addition, a double blind study has been completed for the shampoo containing miconazole nitrate that counteracts against dandruff and seborrheic dermatitis[7]. Seborrheic dermatitis will develop the lesion at first due to the disposition, next due to the environment and finally due to *M. furfur*.

Since topical steroids, which are generally used to treat seborrheic dermatitis, present problems because of their adverse reactions, it is concluded that anti-fungal agents have potential value as a new therapeutic agent, an alternative to the steroids.

Recently, genus *Malassezia* are divided into 7 species according to the report of E. Gueho et al[18]. Finally, we identified five species from

the lesion of the seborrheic dermatitis, tinea versicolor and dandruff on the patient's skin. In our own cases, the strain that are maintained in dixon medium are divided into five species according to Guillot's report[19]. Three strains are *M. furfur*, 3 strains *M. pachydermatis*, 4 strains *M. sympodialis*, 3 strains *M. slooffiae* and 2 strains *M. globosa*. We have been unable to prove the relationship between the species and the severity of diseases. We continue to identify the strain of *Malassezia* in the skin for the purpose of understanding more about seborrheic dermatitis.

REFERENCES

1. Roberts SOB, Mackenzie DWR. Mycology In: Textbook of dermatology, Blackwell Scientific, 1992; 1176-1180
2. Clemmensen OJ, Hjorth N. Treatment of dermatitis of the head and neck with ketoconazole in patients with type 1 sensitivity to Pityrosporum orbiculare. Semin Dermatol 1983; 2: 26-29
3. Skinner RB, Noah PW, Taylor RM, et al. Double-blind treatment of seborrheic dermatitis with 2% ketoconazole cream. J Am Acad Dermatol 1985; 12: 852-856
4. Segal R, David M, Ingber A, Lurie R, Sandbank M. Treatment with Bifonazole shampoo for seborrhea and seborrheic dermatitis; A rondomized, double-blind study. Acta Dermatol Venereol (stockh) 1992; 72: 454-455
5. Ortonne JP, Lacour JP, Vitetta A Le Fichoux Y. Comparative study of ketokonazole 2% foaming gel and betamethasone dipropionate 0.05% lotion in the treatment of seborrheic dermatitis in adults. Dermatology 1992; 184: 275-280
6. Burton JL. Seborrheic dermatitis. In: Textbook of dermatology, Blackwell Scientific, 1992; 545-551
7. SEI Y, Takiuchi I, Watanabe S, et al. Study on the usefulness of shampoo containing 0.75% Miconazole nitrate for the treatment of Dandruff -A double-blind, comparative study. Jap J Med Mycol 1997; 38: 87-97
8. KCZ cream clinical research group for seborrheic dermatitis. Clinical effect of KCZ (Ketoconazole) cream on seborrheic dermatitis. J Clinical Therapeutic & Med 1994; 10: 1277-1290
9. KCZ cream clinical research group for seborrheic dermatitis: Clinical evaluation of KCZ (Ketoconazole) cream on seborrheic dermatitis - double-blind bilateral comparative study with once and twice a day application. J Clinical Therapeutic & Med 1994; 10: 1291-1309
10. Kato T, Tsunoda A, Maruyama R, Nishioka K. Evaluation of the clinical and mycological efficacy of ketoconazole cream in the treatment of seborrheic dermatitis. The Nishinihon J Dermatol 1995; 57: 382-388
11. Nakabayashi A, Nakamura J, Ninomiya J, Watanabe H, Sei Y. Relationship of seborrheic dermatitis and *Malassezia* -An animal model of seborrheic dermatitis. Jap J Med Mycol 1995; 36: 297-302
12. Nakabayashi A, Ninomiya J, Iizuka J, Yoshihiro Sei Y. Relationship of seborrheic dermatitis and *Malassezia* -Production of experimental seborrheic dermatitis in guina pigs, detection of antibody against *Malassezia* in serum. 141, 1997 Proceeding of 13th congress of the international society for human and animal mycology.
13. Madelene CYH, Henderson CL, Barker DC, Haberfelde G. Correlation of *Pityrosporum ovale* density with clinical severity of seborrheic dermatitis as assessed by a simplified technique. J Am Acad Dermatol 1990; 23: 82-86
14. Sei Y, Hamaguti T, Ninomiya J, Atuhiro Nakabayashi A, Takiuchi I. Seborrheic dermatitis: Treatment with anti-mycotic agents. J Dermatol 1994; 21: 334-340
15. Bergbrant IM. Seborrheic dermatitis and *Pityrosporum ovale*: Cultral, immunological and clincal studies. Acta Derm Venereol (supple) 1991; 167: 1-36
16. Sei Y, Nakabayashi A, Junya Ninomiya, Iwao Takiuchi. Seborrheic dermatitis and *Malassezia*. The archives of the first Dermatological Mycology Club 1994; 68-74

17. Yamamoto T, Kim M. Basic research and applications of egg yolk antibody. Nippon Nogeigaku Kaishi 1993; 67: 1421-1439
18. Gueho E, et al. The genus *Malassezia* with description of four new species. Antonie van Leeuwenhoek 1996; 69: 337-355
19. Guillot J, et al. Identification of *Malassezia* species A practical approach. J Mycol Med 1996; 6: 103-110