CASE LETTER
J Mycol Infect 2021; 26(2): 45-47
pISSN:1226-4709, eISSN:2465-8278
https://dx.doi.org/10.17966/JMI.2021.26.2.45

JMI

First Report of Chromoblastomycosis caused by *Fonsecaea nubica* in South Korea

Kyung Duck Park[1], Eun Hye Lee[1], Seon Hwa Lee[1], Yong Jun Bang[2], Jae Bok Jun[2], Jong Soo Choi[3], Dae-Lyong Ha[1], Jun Young Kim[1], Yong Hyun Jang[1], Seok-Jong Lee[1] and Weon Ju Lee[1†]

[1]Department of Dermatology, School of Medicine, Kyungpook National University, Kyungpook National University Hospital, Daegu, Korea
[2]Institute of Medical Mycology, Catholic Skin Clinic, Daegu, Korea
[3]Department of Dermatology, College of Medicine, Yeungnam University, Daegu, Korea

Chromoblastomycosis is a chronic granulomatous or verrucous skin condition that is mainly caused by *Fonsecaea pedrosoi*, *Phialophora verrucose*, and *Cladophialophora carrionii*[1]. The recent taxonomic revision of the genus *Fonsecaea* has recognized four species: *F. pedrosoi*, *F. monophora*, *F. nubica*, and *F. pugnacius*[2]. In this case report, we introduce the first case of *F. nubica* skin infection in Korea.

An 84-year-old female visited our clinic with a soft, micaceous, scaly plaque surrounded by an erythematous scarring on the left inner wrist and dorsal hand area. The patient could not recall its onset or any history of trauma, but she reported its chronic progression over several years, which was accompanied by a painful or burning sensation. The patient had no significant past history of illnesses. The KOH examination of the wrist lesion showed sclerotic cells. The fungal culture showed a black-gray velvety colony (Fig. 1A) with *Cladosporium*-type conidia (Fig. 1B). The skin biopsy obtained from the granulation tissue showed aggregated neutrophil infiltration and lymphohistiocytes on the perivascular area of the dermis. Sclerotic cells were identified in this area (Fig. 1C). The evaluation of homology was done using the Basic Local Alignment Search Tool on the GenBank database. The internal transcribed spacer (ITS) region of ribosomal DNA was identified as *F. nubica* (used primers were ITS1 and ITS4). Gene sequencing revealed 100% homology with strain CBS 121720 and CGMHD 0745. Identity with other *Fonsecaea* species were 97.55% with *F. pedrosoi* type strain CBS 271.37 and 96.30% with *F. monophora* type strain CBS 269.37 (Fig. 2). The patient was treated with 100 mg itraconazole taken orally twice a day. After nine months, three coin-sized, wart-like, granulomatous plaque lesions remained (Fig. 1D), and local cryotherapy was also applied. Two months after the combination treatment, the patient demonstrated a good clinical improvement.

Although the four *Fonsecaea* species have similar morphologies, they have different pathogenicity. *F. pedrosoi* and *F. nubica* appear to be exclusively associated with chromoblastomycosis, whereas *F. monophora* was found to cause chromoblastomycosis and infections in other organs, including the brain, gallbladder, and lymph nodes[2]. The presence of muriform cells (Medlar bodies or sclerotic cells) and the identification of an etiological agent in a microbiological culture are necessary to confirm the diagnosis of chromoblastomycosis[3]. *Fonsecaea* species are often misidentified due to their indistinct morphological features. Moreover, the reclassification of the genus *Fonsecaea* is being made by molecular genetics. For strain DUMC 0401, it was reported as *F. pedrosoi* in 2010 by Lim SW et al.[4]; its ITS sequence was 99.47% identical with that of the present case. Based on the results of the phylogenetic analysis, this strain should be

Received: March 15, 2021 Revised: May 10, 2021 Accepted: June 4, 2021
†Corresponding: Weon Ju Lee, Department of Dermatology, Kyungpook National University Hospital, 130 Dongduk-ro, Jung-gu, Daegu, 41944, Korea.
Phone: +82-53-420-5838, Fax: +82-53-426-0770, e-mail: weonju@knu.ac.kr
Copyright@2021 by The Korean Society for Medical Mycology. All right reserved.
This is an open-access article distributed under the terms of the Creative Commons Attribution Non-Commercial License (http://creativecommons.org/licenses/by-nc/3.0/), which permits unrestricted non-commercial use, distribution, and reproduction in any medium, provided the original work is properly cited. http://www.ksmm.org

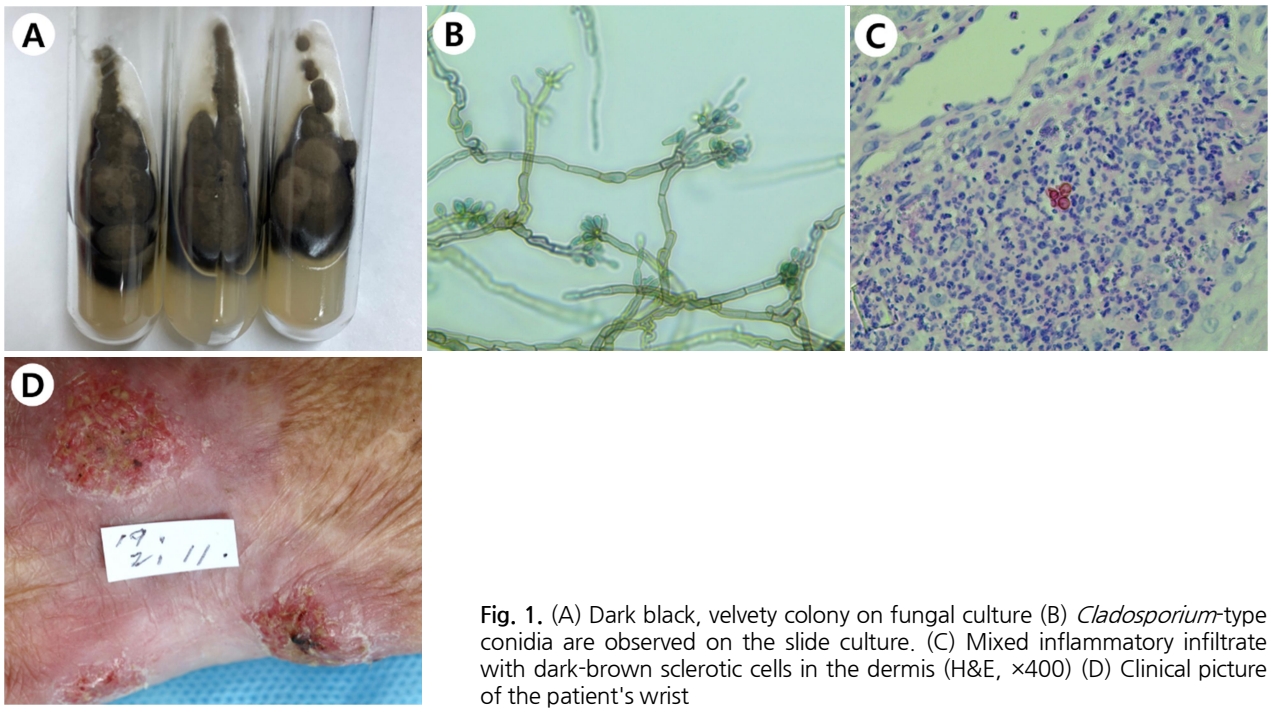

Fig. 1. (A) Dark black, velvety colony on fungal culture (B) *Cladosporium*-type conidia are observed on the slide culture. (C) Mixed inflammatory infiltrate with dark-brown sclerotic cells in the dermis (H&E, ×400) (D) Clinical picture of the patient's wrist

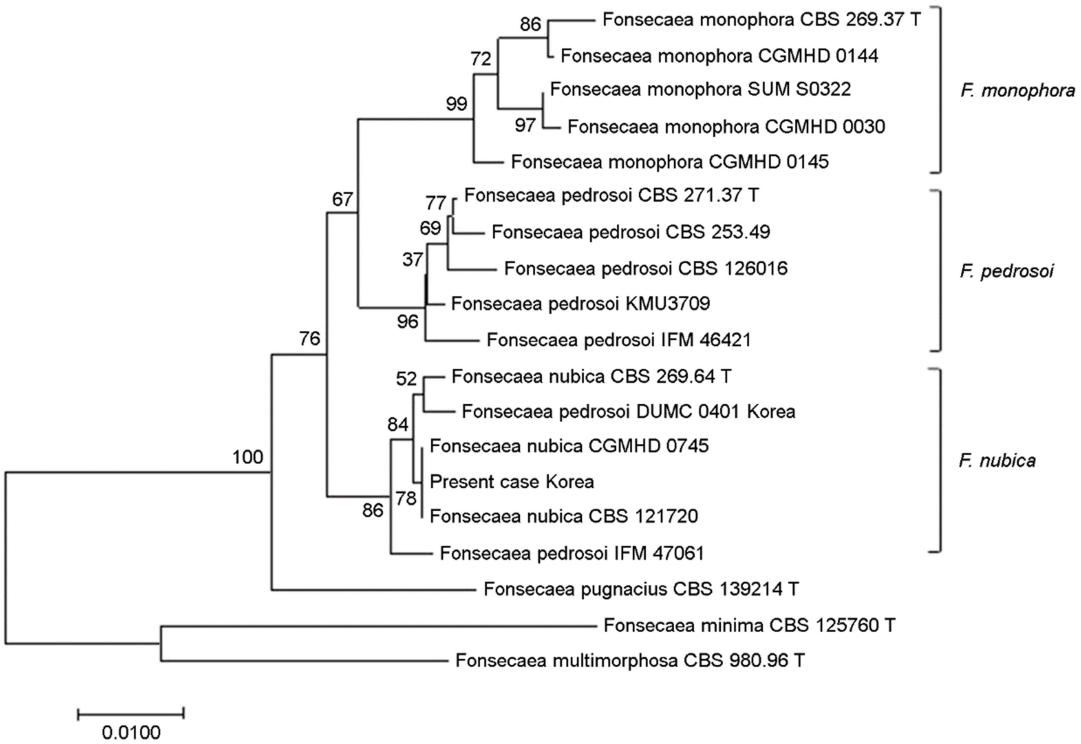

Fig. 2. Phylogenetic tree of *Fonsecaea nubica* using the Neighbor-Joining method with ribosomal RNA gene ITS sequence. The optimal tree is shown with the sum of the branch length = 0.21440491. The percentage of replicate trees in which the associated taxa were clustered together in the bootstrap test (500 replicates) is shown next to the branches. The evolutionary distances were computed using the Maximum Composite Likelihood method. The evolutionary analyses were conducted in MEGA7

Copyright@2021 by The Korean Society for Medical Mycology

reclassified as *F. nubica* (Fig. 2). It is possible that there had been previous unreported cases of chromoblastomycosis caused by *F. nubica* in Korea. The treatment of chromoblastomycosis is challenging as there is currently no treatment of choice. Many modalities, including systemic antifungal agents, immunomodulatory therapy, physical methods, photodynamic therapy, and surgical excision, have been used in previous reports[5]. Itraconazole is the most commonly used first-line agent. A successful treatment with voriconazole or posaconazole has also been described. In this case, we were able to get good results using oral itraconazole, followed by a combination therapy with cryotherapy.

Keywords: *Fonsecaea nubica*

ACKNOWLEDGEMENT

The authors declare that there are no funding sources.

CONFLICT OF INTEREST

In relation to this article, we declare that there is no conflict of interest.

ORCID

Kyung Duck Park: 0000-0002-6067-7262
Eun Hye Lee: 0000-0002-4886-5439
Seon Hwa Lee: 0000-0003-4178-8968
Yong Jun Bang: 0000-0001-7242-9306
Jae Bok Jun: 0000-0003-4834-4526
Jong Soo Choi: 0000-0003-3593-3970
Dae-Lyong Ha: 0000-0002-2268-4795
Jun Young Kim: 0000-0002-2999-1018
Yong Hyun Jang: 0000-0003-1706-007X
Seok-Jong Lee: 0000-0002-6131-632X
Weon Ju Lee: 0000-0001-5708-1305

PATIENT CONSENT STATEMENT

The patient provided written informed consent for the publication and the use of her images.

REFERENCES

1. Krzyściak PM, Pindycka-Piaszczyńska M, Piaszczyński M. Chromoblastomycosis. Postepy Dermatol Alergol 2014; 31:310-321
2. Fransisca C, He Y, Chen Z, Liu H, Xi L. Molecular identification of chromoblastomycosis clinical isolates in Guangdong. Med Mycol 2017;55:851-858.
3. Queiroz-Telles F, Esterre P, Perez-Blanco M, Vitale RG, Salgado CG, Bonifaz A. Chromoblastomycosis: an overview of clinical manifestations, diagnosis and treatment. Med Mycol 2009;47:3-15
4. Lim SW, Suh MK, Kang GS, Ha GY, Kim H, Choi JS, et al. Molecular phylogenetics of *Fonsecaea* strains isolated from chromoblastomycosis patients in South Korea. Mycoses 2011;54:e415-e420
5. Yang CS, Chen CB, Lee YY, Yang CH, Chang YC, Chung WH, et al. Chromoblastomycosis in Taiwan: a report of 30 cases and a review of the literature. Med Mycol 2018; 56:395-405