CASE REPORT
J Mycol Infect 2025; 30(4): 154-159
pISSN:3058-423X, eISSN:3058-4302
https://dx.doi.org/10.17966/JMI.2025.30.4.154

JMI

First Molecular Confirmation of *Trichophyton indotineae* in South Korea: A Case Report

Bo Young Moon[1], Jong Soo Choi[1†], Dong Hoon Shin[1], Joon Goon Kim[1], Jae Bok Jun[2], Young Jun Bang[2], Jin Park[3], Seun Kang[4], Jahyeon Sim[4] and Kyung-Tae Lee[4]

[1]Department of Dermatology, College of Medicine, Yeungnam University, Daegu, Korea
[2]Daegu Catholic Dermatology Clinic, Daegu, Korea
[3]Department of Dermatology, College of Medicine, Jeonbuk National University, Jeonju, Korea
[4]Korea Zoonosis Research Institute, Jeonbuk National University, Iksan-si, Korea

Trichophyton indotineae is an emerging terbinafine-resistant dermatophyte within the *T. mentagrophytes* / *T. interdigitale* complex. Herein, we describe the first two confirmed Korean cases of *T. indotineae* infection. Both patients had chronic and extensive dermatophytosis involving the trunk, buttocks, thighs, and groin in case 1 and confined to the right lower leg and ankle in case 2. In both cases, the eruption failed to respond to terbinafine or itraconazole and was aggravated by intermittent corticosteroid use. Cultures produced white cottony colonies with grape-like microconidia and negative urease reactions. Internal transcribed spacer (ITS) region sequencing identified *T. indotineae*, and analysis of the squalene epoxidase (SQLE) gene showed L393F mutation, which was associated with terbinafine resistance. Antifungal susceptibility testing revealed terbinafine resistance but susceptibility to itraconazole. After withdrawal of corticosteroids and maintenance of continuous itraconazole therapy, case 1 showed near-complete clinical remission with minimal residual scaling, whereas case 2 achieved complete clinical and mycological remission. These findings suggest possible local transmission and emphasize the importance of molecular confirmation and antifungal stewardship in Korea.

Key Words: Antifungal susceptibility, Dermatophyte, Korea, Squalene epoxidase, Terbinafine resistance, *Trichophyton indotineae*

INTRODUCTION

In 2020, *Trichophyton indotineae* was recognized as a distinct species within the TMTI complex after characterization of the highly terbinafine-resistant genotype VIII[1]. Since 2018, an epidemic-like increase in recalcitrant dermatophytosis has been documented in India, which was largely attributed to the inappropriate use of topical steroid-antifungal combinations and incomplete antifungal therapy[2,3]. Following its initial description, *T. indotineae* has been reported across Asia, the Middle East, Europe, and North America[4-7]. By 2024-2025, confirmed cases of *T. indotineae* had also emerged in Taiwan and Thailand[8,9].

In Korea, clinicians have increasingly suspected terbinafine-resistant dermatophytosis. However, to date, no infections had been molecularly confirmed as *T. indotineae*. Herein, we report two such cases and discuss their clinical course, laboratory confirmation, and implications for local transmission

Received: November 15, 2025 Revised: November 22, 2025 Accepted: December 9, 2025
†Corresponding: Jong Soo Choi, Department of Dermatology, College of Medicine, Yeungnam University, 170 Hyeonchung-ro, Nam-gu, Daegu 42415, Korea.
Phone: +82-53-620-3742, Fax: +82-53-620-4459, e-mail: apsmm08@gmail.com
Copyright@2025 by The Korean Society for Medical Mycology. All right reserved.
This is an open-access article distributed under the terms of the Creative Commons Attribution Non-Commercial License (http://creativecommons.org/licenses/by-nc/3.0/), which permits unrestricted non-commercial use, distribution, and reproduction in any medium, provided the original work is properly cited. http://www.ksmm.org

and antifungal stewardship.

CASE REPORT

A 36-year-old man presented with multiple pruritic plaques involving the trunk, buttocks, and legs that had persisted for more than one year. The eruption began as small erythematous annular plaques on the thighs and gradually expanded, forming large confluent scaly plaques (Fig. 1, A1 and A2). The patient had been treated with topical terbinafine preparation and oral terbinafine (200-375 mg/day) for three months without improvement. In fact, the lesions became more extensive. Subsequently, he received oral itraconazole (200 mg/day) irregularly for about five months. However, this regimen only led to brief periods of partial improvement. For severe itching,

Fig. 1. Clinical features and treatment response in two Korean patients with dermatophytosis caused by *Trichophyton indotineae*. (A1 and A2) Before adequate treatment, case 1 showed extensive annular and polycyclic erythematous plaques with scaly active borders on the trunk, buttocks, and thighs, which were partly modified by intermittent potent topical corticosteroids. (A3 and A4) Near-complete clearance with faint post inflammatory hyperpigmentation at five months after corticosteroid withdrawal and continuous oral itraconazole; (B1) Before adequate treatment, case 2 showed coalescent annular plaques with peripheral scale on the right lower leg and ankle. (B2) Complete clinical remission after supervised itraconazole therapy and discontinuation of steroid-containing topical preparations

he intermittently received short courses of oral methylprednisolone and used topical antifungal-corticosteroid combination creams (clotrimazole-hydrocortisone, econazole-triamcinolone acetonide, and isoconazole nitrate-diflucortolone valerate), but the eruption progressively worsened. The patient had no history of overseas travel.

Several months after his eruption began, his Korean partner developed similar pruritic annular plaques, raising suspicion of household transmission. A 29-year-old woman presented with large coalescent annular plaques on her right ankle and lower leg, accompanied by intense pruritus and excoriations (Fig. 1, B1). She had taken oral terbinafine (250 mg/day) for three months without significant response. Subsequent treatment with oral itraconazole (200 mg/day) for five months, together with the same topical antifungal-corticosteroid combination creams as case 1 and intermittent short courses of oral methyl-prednisolone, produced only transient relief. Moreover, the affected area slowly enlarged during this period. The patient also denied any travel abroad.

In both patients, the lack of response to an apparently adequate course of oral terbinafine raised strong suspicion for terbinafine-resistant dermatophytosis. Irregular itraconazole therapy combined with the intermittent use of corticosteroids did not induce remission. Therefore, all topical and systemic corticosteroids were discontinued, and itraconazole was switched to another generic formulation and administered at 200 mg/day under close supervision. Both patients steadily improved with strict adherence to this regimen. After five months, case 2 showed complete clinical and mycological remission, whereas case 1 showed near-complete clearance with only faint residual scaling on the buttocks and thighs (Fig. 1, A3, A4, and B2). Follow-up cultures were negative in both cases, although a few hyphae were still detectable on direct KOH examination in case 1.

Direct KOH examination of skin scraps from both patients revealed branching septate hyphae. Meanwhile, cultures on Sabouraud dextrose agar and potato dextrose cornmeal agar with Tween 80, incubated at 25-30℃, produced colonies within 10 days. The colonies were white to gray in color, fluffy, and somewhat cottony with yellow-brown reverse pigmentation (Fig. 2, A and B).

Microscopic examination revealed numerous pyriform microconidia arranged in grape-like clusters, spiral hyphae, and frequent macroconidia, which are features compatible with the TMTI complex (Fig. 2, C and D). Urease test on Christensen's urea agar remained negative after 14 days, whereas *T. mentagrophytes* and *T. interdigitale* controls typically became positive within one week (Fig. 2, E). The negative urease reaction supported *T. indotineae* as the presumptive species.

DNA sequencing of the internal transcribed spacer (ITS) region showed 100% identity with the *T. indotineae* type strains NUBS19006 (NR_173767) and NUBS19007 (LC-508728). Meanwhile, squalene epoxidase (SQLE) gene sequencing identified a c.1179A>T substitution at codon 393, resulting in the L393F amino acid change.

Antifungal susceptibility testing was performed according to the CLSI M38-A3 protocol. The minimum inhibitory concentrations (MICs) are summarized in Table 1. Both isolates demonstrated high-level resistance to terbinafine (MIC values >10 μg/mL) while remaining susceptible to itraconazole and posaconazole.

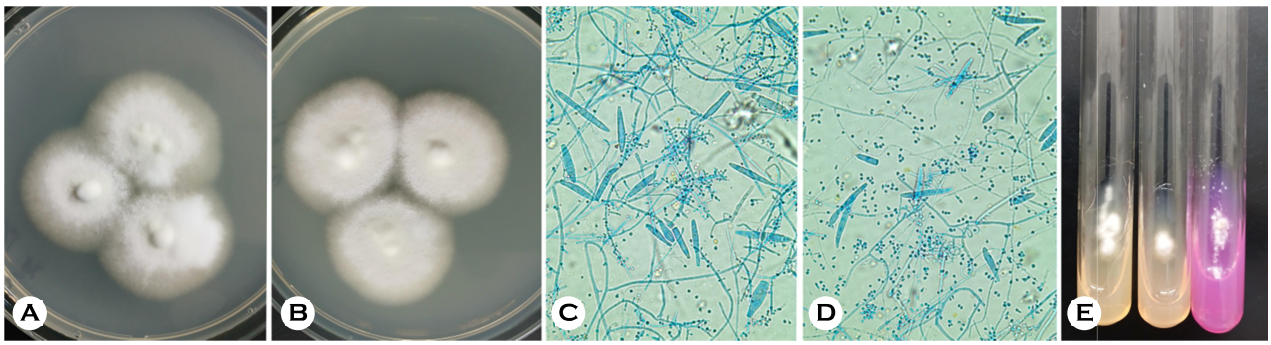

Fig. 2. Mycological findings of *Trichophyton indotineae* isolates from the two patients. (A and B) Colonies on potato dextrose cornmeal agar with Tween 80 after 14 days at 25-30℃, showing white to gray cottony surfaces compatible with the *T. mentagrophytes* / *T. interdigitale* complex; (C and D) Lactophenol cotton blue mounts (×400) with numerous pyriform microconidia in grape-like clusters, spiral hyphae, and macroconidia; (E) Urease test on Christensen's urea agar after 14 days; Both clinical isolates remain urease-negative, whereas the *T. interdigitale* control is urease-positive, supporting identification of *T. indotineae*.

Copyright@2025 by The Korean Society for Medical Mycology

Table 1. Minimum inhibitory concentrations of antifungal agents for two *Trichophyton indotineae* isolates determined by the CLSI M38-A3 method (μg/mL)

Antifungal agents§	Case 1	Case 2
TBF	10.67	25.33
KCZ	0.54	0.54
MCZ	0.58	1.02
CTZ	1.67	3.33
ICZ	0.07	0.08
FCZ	49.00	96.00
VCZ	0.46	0.54
PSC	0.06	0.21
IVZ	4.17	4.00
AmB	0.13	0.06
GRF	0.54	0.58

§Abbreviations: AmB, amphotericin B; CTZ, clotrimazole; FCZ, fluconazole; GRF, griseofulvin; ICZ, itraconazole; IVZ, isavuconazole; KCZ, ketoconazole; MCZ, miconazole; PSC, posaconazole; TBF, terbinafine; VCZ, voriconazole

DISCUSSION

These two cases represent the first molecularly confirmed *T. indotineae* infections acquired in Korea. The lack of travel history in both patients and the occurrence of a similar eruption in a household contact of case 1 suggest that an imported terbinafine-resistant strain may now be circulating domestically, as has been observed in other regions[5,6,9].

Morphologic differentiation among members of the TMTI complex is difficult and often unreliable[10]. In our patients, the colony morphology and microscopic findings were compatible with the TMTI complex, but not distinctive for *T. indotineae*. The negative urease tests raised suspicion, whereas definitive identification required ITS sequencing. This finding highlights the need for access to molecular tools and updated matrix-assisted laser desorption/ionization time-of-flight databases or species-specific polymerase chain reaction assays, where available[7,11].

Terbinafine resistance in *T. indotineae* has been associated with structural alterations in SQLE that reduce terbinafine binding while preserving enzyme function. The F397L substitution is most frequently reported worldwide, followed by L393F, with other substitutions being less commonly described[7,10,12]. Our isolates carried L393F and showed high terbinafine MICs, consistent with these reports.

Clinicians should consider *T. indotineae* when patients present with large, scaly plaques involving the trunk and groin while sparing the feet and nails, and fail to respond to a 4~6-week course of appropriately dosed terbinafine[3,13,14]. A negative urease test in a TMTI-complex isolate further raises suspicion for this species[10]. In such cases, mycological confirmation, including culture, molecular identification, and antifungal susceptibility testing, is important for patient management and surveillance[7,11].

Itraconazole is generally effective against *T. indotineae*. However, clinical outcomes may be compromised by irregular intake, suboptimal formulations, or concurrent corticosteroid use[14,15]. In our patients, *in vitro* susceptibility testing suggested that itraconazole remained active, and clinical failure appeared to be driven primarily by irregular dosing, concomitant use of systemic and topical corticosteroids, and possibly formulation-dependent differences among itraconazole generics. Both patients showed gradual but sustained improvement under supervised itraconazole monotherapy at 200 mg/day with complete withdrawal of corticosteroids, resulting in near-complete clearance with minimal residual scaling and low-level residual hyphae on KOH in case 1 and complete clinical and mycological remission in case 2. Because therapeutic drug monitoring was not performed, our experience cannot be taken as proof of superiority of one generic over another. However, the temporal association suggests that formulation-dependent bioavailability and consistent intake may play a clinically relevant role in real-world practice[15].

For symptom control, patients with severe pruritus are often prescribed with short courses of topical or systemic corticosteroids. However, in active dermatophytosis, corticosteroids can modify lesion morphology, delay diagnosis, and prolong the disease course[2,3,13]. During antifungal therapy, symptomatic relief should primarily rely on nonsteroidal measures, including oral antihistamines, emollients, and cooling agents. If corticosteroids are considered unavoidable, they should be used at the lowest effective potency and for the shortest possible duration under close follow-up.

From a public health standpoint, the emergence of *T. indotineae* in Korea highlights the need for coordinated antifungal resistance surveillance. In Europe, reference laboratory networks and standardized susceptibility testing have enabled earlier recognition of resistant dermatophytes[4,16]. However, antifungal susceptibility testing is rarely performed in routine practice in Korea, largely because it is not reimbursed. The inclusion of such testing within insurance coverage, together with national guidelines recommending when to test, would facilitate systematic monitoring of MIC trends and SQLE

mutations. Ongoing data collection will be essential for updating treatment recommendations and supporting antifungal stewardship.

This report is limited by the small number of patients, lack of therapeutic drug monitoring for itraconazole, and absence of confirmatory testing in household contacts. Moreover, although case 2 achieved complete clinical and mycological cure, case 1 still showed minimal residual scaling and a few hyphae on KOH at the last follow-up. Therefore, longer observation is needed to confirm durable mycological cure. Our statement that these are the first molecularly confirmed *T. indotineae* cases in Korea is based on extensive searches of domestic and international literature and conference abstracts available at the time of writing. However, unpublished or unrecognized cases may exist.

CONCLUSION

T. indotineae has now been identified as a terbinafine-resistant dermatophyte causing extensive tinea corporis and cruris in Korea. This species should be suspected when large, intensely pruritic plaques on the trunk and groin persist despite standard terbinafine therapy and when urease-negative isolates of the TMTI complex are recovered. Corticosteroid withdrawal, use of adequately dosed itraconazole, and access to molecular identification and antifungal susceptibility testing will be crucial to treat and limit the spread of *T. indotineae*.

ACKNOWLEDGEMENT

This work was supported by the Basic Science Research Program of the National Research Foundation of Korea, funded by the Ministry of Science and ICT (RS-2022-NR072215). This paper was also supported by the Fund of Biomedical Research Institute, Jeonbuk National University Hospital.

CONFLICT OF INTEREST

In relation to this article, we declare that there is no conflict of interest.

ORCID

Bo Young Moon: 00009-0009-9193-3482
Jong Soo Choi: 0000-0003-3593-3970
Dong Hoon Shin: 0000-0003-3130-1989
Joon Goon Kim: 0000-0002-4620-3699
Jae Bok Jun: 000-0003-4834-4526
Young Jun Bang: 000-0001-7242-9306
Jin Park: 0000-0002-8830-5479
Seun Kang: 0009-0001-5884-7517
Jahyeon Sim: 0009-0009-4732-249X
Kyung-Tae Lee: 0000-0002-0068-6220

PATIENT CONSENT STATEMENT

The patients provided written informed consent for the publication and the use of their images.

REFERENCES

1. Kano R, Kimura U, Kakurai M, Hiruma J, Kamata H, Suga Y, et al. *Trichophyton indotineae* sp. nov.: A new highly terbinafine-resistant anthropophilic dermatophyte species. Mycopathologia 2020;185:947-958
2. Nenoff P, Verma SB, Uhrlaß S, Burmester A, Gräser Y. A clarion call for preventing taxonomical errors of dermatophytes using the example of the novel *Trichophyton mentagrophytes* genotype VIII uniformly isolated in the Indian epidemic of superficial dermatophytosis. Mycoses 2019;62:6-10
3. Verma SB, Panda S, Nenoff P, Singal A, Rudramurthy SM, Uhrlass S, et al. The unprecedented epidemic-like scenario of dermatophytosis in India: I. Epidemiology, risk factors and clinical features. Indian J Dermatol Venereol Leprol 2021;87:154-175
4. Lockhart SR, Smith DJ, Gold JAW. *Trichophyton indotineae* and other terbinafine resistant dermatophytes in North America. J Clin Microbiol 2023;61:e0090323
5. Caplan AS, Todd GC, Zhu Y, Sikora M, Akoh CC, Jakus J, et al. Clinical course, antifungal susceptibility, and genomic sequencing of *Trichophyton indotineae*. JAMA Dermatol 2024;160:701
6. Er YX, Leong KF, Foong HBB, Abdul Halim AA, Kok JS, Yap NJ, et al. Dermatophytoses caused by *Trichophyton indotineae*: The first case reports in Malaysia and the global epidemiology (2018-2025). J Fungi 2025;11:523
7. Xie W, Liang G, Kong X, Tsui CKM, She X, Liu W, et al. Genomic epidemiology and antifungal resistance of emerging *Trichophyton indotineae* in China. Emerg Microbes Infect 2025;14:2498571

Copyright@2025 by The Korean Society for Medical Mycology

8. Prunglumpoo S, Krongboon K, Intarachaieua K, Kazushi A, Bunnag T, Paunrat W, et al. Emergence of resistant dermatophytosis caused by *Trichophyton indotineae*: First case series in Thailand. Med Mycol Case Rep 2025;48:100713
9. Wang HT, Li ML, Wu WL, Wu CJ, Liu WT. Emergence of terbinafine-resistant *Trichophyton indotineae* dermatophytosis in a familial cluster in Taiwan: Successful management with prolonged oral itraconazole. J Microbiol Immunol Infect 2025;S1684-1182(25)00138-0
10. Tan TY, Wang YS, Wong XYA, Rajandran P, Tan MG, Tan AL, et al. First reported case of *Trichophyton indotineae* dermatophytosis in Singapore. Pathology 2024;56:909-913
11. Baron A, Hamane S, Gits-Muselli M, Legendre L, Benderdouche M, Mingui A, et al. Dual quantitative PCR assays for the rapid detection of *Trichophyton indotineae* from clinical samples. Med Mycol 2024;62:myae067
12. Singh A, Masih A, Khurana A, Singh PK, Gupta M, Hagen F, et al. High terbinafine resistance in *Trichophyton interdigitale* isolates in Delhi, India harbouring mutations in the squalene epoxidase gene. Mycoses 2018;61:477-484
13. Uhrlaß S, Verma SB, Gräser Y, Rezaei-Matehkolaei A, Hatami M, Schaller M, et al. *Trichophyton indotineae*—An emerging pathogen causing recalcitrant dermatophytoses in India and worldwide—A multidimensional perspective. J Fungi 2022;8:757
14. Gupta AK, Venkataraman M, Hall DC, Cooper EA, Summerbell RC. The emergence of *Trichophyton indotineae*: Implications for clinical practice. Int J Dermatol 2023;62:857-861
15. Sehgal IS, Vinay K, Dhooria S, Muthu V, Prasad KT, Aggarwal AN, et al. Efficacy of generic forms of itraconazole capsule in treating subjects with chronic pulmonary aspergillosis. Mycoses 2023;66:576-584
16. Arendrup MC, Friberg N, Mares M, Kahlmeter G, Meletiadis J, Guinea J, et al. How to interpret MICs of antifungal compounds according to the revised clinical breakpoints v. 10.0 European committee on antimicrobial susceptibility testing (EUCAST). Clin Microbiol Infect 2020;26:1464-1472