IMAGES IN MYCOLOGY

J Mycol Infect 2018; 23(3): 82-83
pISSN:1226-4709, eISSN:2465-8278
http://dx.doi.org/10.17966/JMI.2018.23.3.82

JMI

Microscopic Findings of Macroconidia in *Epidermophyton floccosum*

Yong Woo Choi[1], Nuri Na[1], Yong Joon Bang[2] and Joonsoo Park[1†]

[1]Department of Dermatology, School of Medicine, Catholic University of Daegu, Daegu, Korea
[2]Catholic Skin Clinic, Medical Mycology, Daegu, Korea

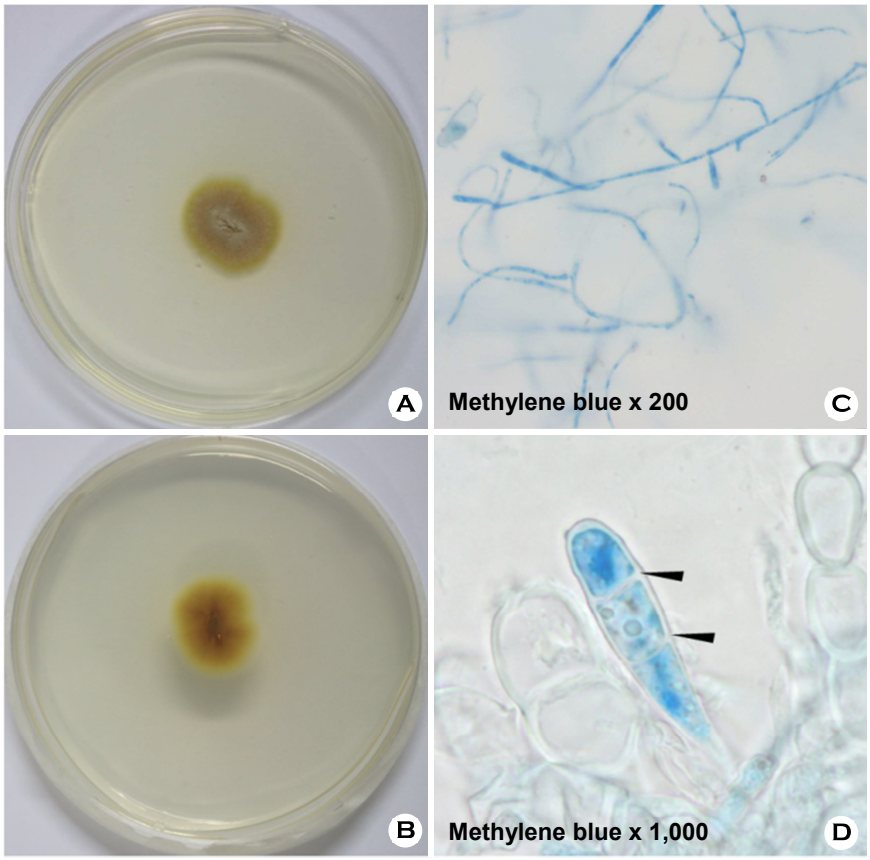

Fig. 1. (A) Colonies are khaki to dark-green with raised and folded centers and a powdery surface. **(B)** The reverse pigment is ocher and mustard-yellow. **(C)** The morphology as seen under a microscope shows characteristic smooth, thin-walled macroconidia growing directly from hyphae. Numerous club-shaped macroconidia are observed (methylene blue x200). **(D)** Pyriform macroconidia are slightly rough walled (black arrow heads) and club shaped with a blunt tip (methylene blue x1,000).

Received: June 8, 2018 Revised: June 20, 2018 Accepted: September 19, 2018
†Corresponding: Joonsoo Park, Department of Dermatology, School of Medicine, Catholic University of Daegu, 33 Duryugongwon-ro 17gil, Namgu, Daegu, 42472, Korea.
Phone: +82-53-650-4161, Fax: +82-53-650-4891, e-mail: magincia@cu.ac.kr
Copyright@2018 by The Korean Society for Medical Mycology. All right reserved.
This is an open-access article distributed under the terms of the Creative Commons Attribution Non-Commercial License (http://creativecommons.org/licenses/by-nc/3.0/), which permits unrestricted non-commercial use, distribution, and reproduction in any medium, provided the original work is properly cited. http://www.ksmm.org

Copyright@2018 by The Korean Society for Medical Mycology

Epidermophyton floccosum is a filamentous fungus that causes skin and nail infections in humans[1]. This anthropophilic dermatophyte can lead to diseases such as tinea pedis, tinea cruris, tinea corporis, and onychomycosis[2]. *E. floccosum* is the only species in the genus *Epidermophyton*. During the twentieth century, this species was the fourth most common cause of dermatophytosis in North America[3]. Although this ascomycete has a worldwide distribution, it is more commonly isolated in patients from tropical and subtropical areas[2]. The non-soil-associated fungus requires no specific growth conditions and displays characteristic smooth club-shaped macroconidia under the microscope[2]. Diagnostic approaches to the fungal infection include a physical examination, followed by testing skin and other cultures, and molecular detection.

As observed under a microscope, *E. floccosum* forms dull green or khaki colonies with a suede-like powdery surface that is raised and folded in the center with a flat periphery[2]. An ocher, deep-yellowish brown to mustard-yellow reverse pigment is usually present[2]. The morphology of *E. floccosum* is characteristic of smooth, thin-walled macroconidia, which are often produced in clusters and grow directly from hyphae[2,3]. Numerous chlamydospores can be present, particularly in old cultures[3]. The early morphology of macroconidia growth exhibits lateral or terminal outgrowths from mature hyphae and initially lacks a basal septum. As the culture ages, macroconidia can transform into chlamydoconidia; therefore, they are best observed in their earlier stages[3]. No microconidia are produced, which differentiates this genus from the other genera of dermatophytes. When differentiating this species from other species of dermatophytes, consideration should be given to the characteristic macroscopic and microscopic findings of *E. floccosum*.

Key Words: Dermatophyte, *Epidermophyton floccosum*, Macroconidia

CONFLICTS OF INTEREST

In relation to this article, I declare that there is no conflict of interest.

REFERENCES

1. Guy S, Richard CS. Identfying filamentous fungi: a clinical laboratory handbook. Belmont, CA: Star Pub, 1996
2. Rippon JW. Medical mycology: the pathogenic fungi and the pathogenic actinomycetes. 3rd ed. Philadelphia: WB Saunders Co, 1988
3. Kane J. Laboratory handbook of dermatophytes: a clinical guide and laboratory handbook of dermatophytes and other filamentous fungi from skin, hair, and nails. Belmont, CA: Star Pub, 1997