CASE REPORT
J Mycol Infect 2023; 28(3): 74-78
pISSN:1226-4709, eISSN:2465-8278
https://dx.doi.org/10.17966/JMI.2023.28.3.74

JMI

A Case of Disseminated Coccidioidomycosis Confirmed by Skin Biopsy in Korea

Yi Na Yoon, Ji Won Lim, Hyung Seok Son, Young Ah Cho, Yang Won Lee, Yong Beom Choe and Da-Ae Yu†

Department of Dermatology, Konkuk University School of Medicine, Seoul, Korea

Disseminated coccidioidomycosis is an uncommon fungal infection primarily observed in immunocompromised individuals. Infection typically occurs when individuals inhale fungal spores in endemic areas such as the southwestern United States and parts of Central and South America. However, globalization has increased the number of reported cases outside endemic areas. Herein, we present an unusual case of coccidioidal meningitis, a rare but fatal complication of disseminated coccidioidomycosis, in an immunocompetent patient who previously resided in an endemic area.

Key Words: Coccidioidal meningitis, Coccidioidomycosis

INTRODUCTION

Coccidioidomycosis, also known as Valley Fever, is a dimorphic fungal infection caused by *Coccidioides immitis* and *Coccidioides posadasii*. These species are present in either a mycelium state or a spherule state. In natural environments such as soil, the organism exhibits mycelial growth through apical extension. When the soil is disturbed by natural processes or human activities, the spores (known as arthroconidia) can become airborne, potentially causing illness when inhaled. It is endemic to the southwestern United States, as well as to some regions of Mexico, Central America, and South America[1]. Most coccidioidal infections are asymptomatic; however, in approximately one-third of cases, it progresses to pulmonary infection and represents a major cause of community-acquired pneumonia in areas with a high disease prevalence. Coccidioidomycosis rarely manifests as extrapulmonary infections of the skin, bones, joints, or central nervous system[2]. Disseminated coccidioidomycosis is commonly observed in older adults and patients with immunosuppressive conditions (such as AIDS and cancer) or those receiving immunosuppressive drugs[2]. Herein, we report an unusual case of coccidioidal meningitis in a young, immunocompetent patient in Korea.

CASE REPORT

A 35-year-old man presented with a two-month history of fever, headache, cough, and an erythematous plaque with grouped vesicles on the left side of his forehead (Fig. 1). This patient, a resident of Los Angeles, USA, often jogged in dusty environments. The patient returned to Korea for treatment owing to the persistence of severe headaches and cough. Peripheral blood test results were as follows: white blood cell (WBC) count: 11,700/mm^3 (neutrophils:

Received: July 21, 2023 Revised: August 16, 2023 Accepted: September 21, 2023
†Corresponding: Da-Ae Yu, Department of Dermatology, Konkuk University School of Medicine, 120-1 Neungdong-ro, Gwangjin-gu, Seoul 05030, Korea.
Phone: +82-2-2030-5172, Fax: +82-2-2030-5179, e-mail: 20220196@kuh.ac.kr
Copyright@2023 by The Korean Society for Medical Mycology. All right reserved.
This is an open-access article distributed under the terms of the Creative Commons Attribution Non-Commercial License (http://creativecommons.org/licenses/by-nc/3.0/), which permits unrestricted non-commercial use, distribution, and reproduction in any medium, provided the original work is properly cited. http://www.ksmm.org

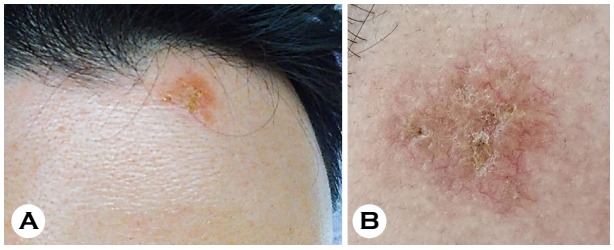

Fig. 1. An erythematous patch with a crust overlying telangiectasia on the left forehead (A, B)

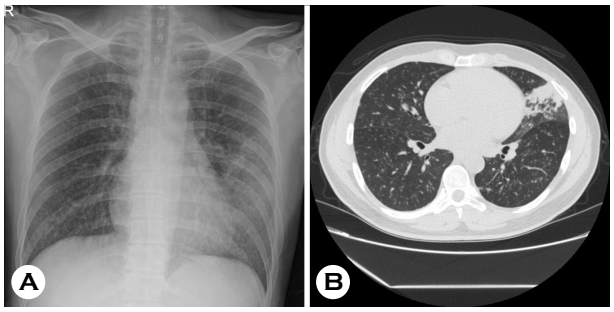

Fig. 2. (A) Haziness in the left lung and right lower lung on the initial chest X-ray (B) Chest CT scan showing multiple tiny nodules in both lungs and consolidation in the left upper lobe

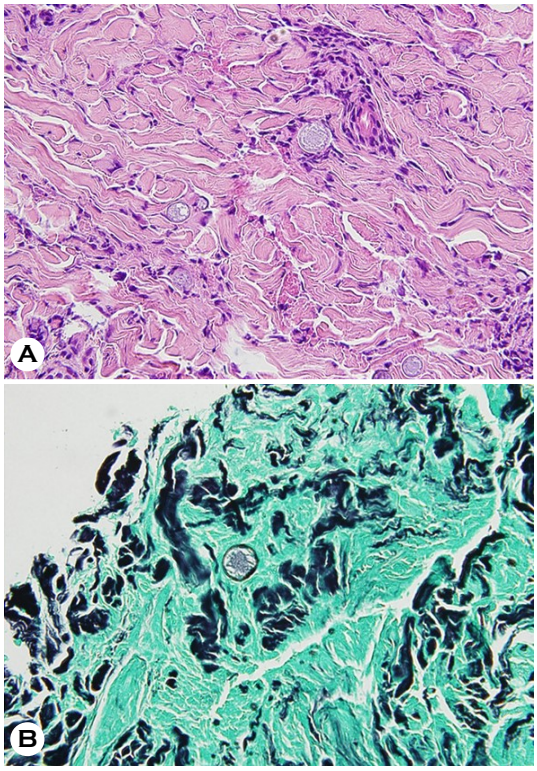

Fig. 3. Histopathology revealed multiple spherules filled with endospores (A: H&E stain ×400, B: Gomori's methenamine silver stain ×400).

45%; lymphocytes: 30%; monocytes: 3%; eosinophils: 15%; basophils: 1%): hemoglobin: 14.4 g/dL; platelets: 414:000/mm^3; and high-sensitivity C-reactive protein (HS-CRP): 4.82 mg/mm^3. Chest radiography findings indicated haziness in the left and right lower lungs, and chest computed tomography (CT) scans revealed multiple tiny nodules, consolidation in both lungs, and lymphadenopathy (Fig. 2). Tuberculosis was suspected; therefore, treatment with antituberculosis medications was initiated. However, his fever persisted, and blood test results indicated eosinophilia; therefore, the patient was hospitalized for further workup. Polymerase chain reaction analyses performed after hospitalization were negative for tuberculosis, and no other respiratory pathogens were detected. Furthermore, bacteria, fungi, and *Mycobacterium tuberculosis* were not identified via culture.

The patient was referred to the Department of Dermatology for a skin lesion biopsy. An erythematous plaque was identified on the left side of his forehead, and, according to the patient, clustered vesicles had appeared and disappeared repeatedly two months earlier. Under the clinical impression of lupus vulgaris, sarcoidosis, or herpes simplex virus infection, a 3-mm punch biopsy was performed. Histological examination results revealed pseudoepitheliomatous hyperplasia in the upper epidermis and thick-walled spherules surrounded with exudative granulomas, suggesting coccidioidomycosis (Fig. 3). The patient was subsequently diagnosed with disseminated coccidiomycosis involving the skin.

The patient's respiratory symptoms worsened, and bronchoscopy and bronchoalveolar lavage were performed. The differential leukocyte count revealed an increase in the neutrophil count to 79.3%, and *Coccidioides* species were identified in the fungal culture (Fig. 4). The patient subsequently complained of hiccups and numbness in his left limbs, and loss of consciousness was observed after his headache and vomiting had worsened. The patient was transferred to the intensive care unit, and spinal tapping was performed. His cerebrospinal fluid (CSF) examination results were as follows: WBC count: 631/μL; protein: 70.1 mg/dL; and glucose: 38 mg/dL, and brain magnetic resonance imaging (MRI) revealed hydrocephalus in both lateral ventricles (Fig. 5). Emergency external ventricular drain (EVD) placement was performed.

In the CSF, the *Coccidioides* antigen and antibody test

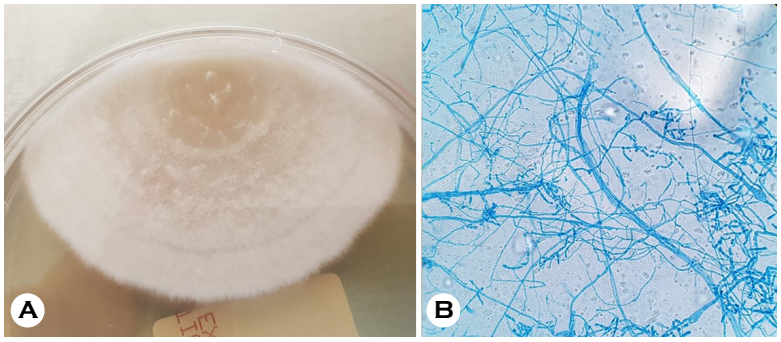

Fig. 4. (A) On Sabouraud dextrose agar (SDA), a colony with white, cottony aerial mycelium was observed. (B) Septate and branched hyphae with thick-walled, barrel-shaped arthroconidia that alternate with empty cells (lactophenol cotton blue stain, ×400)

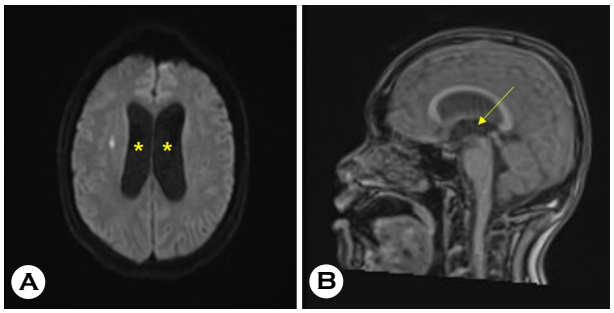

Fig. 5. Brain MRI showing enlargement of (A) both lateral ventricles (*) and (B) the third ventricle (yellow arrow)

results were negative, whereas the serum antigen and antibody test results were positive. Subsequent whole-genome sequencing conducted for species identification confirmed it as *Coccidioides immitis*. Consequently, the patient was diagnosed with coccidioidal meningitis and treated with intravenous fluconazole (1,200 mg/day). Despite the administration of fluconazole and EVD, the hydrocephalus did not improve. After three weeks of treatment, the patient was administered voriconazole; however, his overall condition, including hyponatremia and pneumonia, deteriorated. Intravenous amphotericin and high-dose steroids with antibiotics were administered but the systemic infection did not improve, and the patient died due to disseminated intravascular coagulation and multiple organ failure.

DISCUSSION

There has been a recent increase in the geographical range of *Coccidioides* species and the number of reported cases owing to changes in both climate and population dynamics[3]. In Korea, 18 cases (including the current one) have been reported since its discovery in 1976[4]. Of these, 11 patients had extrapulmonary involvement, and >50% of them presented with disseminated infections. Skin involvement was the most common (six cases), and articular, bone, and bone marrow involvement has also been reported. Brain involvement was also confirmed in two cases, including one case of mild CNS symptoms and one case of severe meningitis with blurred vision and gait disturbance[5,6]. Extrapulmonary infections account for only a minority of all infections (approximately 1%), and disseminated infections are more common in patients of Asian ethnicity than in those living in endemic regions. They are also more common in men, children, people of non-European ethnicity, and immunocompromised individuals[7,8].

Coccidioidal meningitis is a significant complication of the disseminated form of the disease. The most common symptom is headache. Other clinical manifestations may include vomiting, fever, altered levels of consciousness, or cognitive impairment. The development of hydrocephalus can confound the treatment of meningitis. Neurosurgical consultation and ventricular shunt placement may be required to control the intracranial pressure[2]. Coccidioidal meningitis has previously been associated with a 100% mortality rate within two years of its diagnosis. However, with the advent of intrathecal amphotericin B treatment in 1957, the mortality rate decreased by 30%[9,10]. Subsequently, the introduction of azoles in the 1990s revolutionized the management of coccidioidomycosis, rendering oral azoles the standard treatment in current practice[1].

In the absence of contraindications, oral azole antifungal therapy is the standard initial treatment for almost all patients diagnosed with coccidioidal meningitis, and these patients require lifelong treatment[11]. Among various azole antifungal agents, fluconazole has remained the primary therapeutic option for over two decades. A daily dose of 400 mg was initially administered. However, owing to high clinical failure

Copyright@2023 by The Korean Society for Medical Mycology

rates, higher daily doses ranging from 800 mg to 1,200 mg are currently commonly administered to treat coccidioidal meningitis[12,13]. Patients who continue to exhibit clinical manifestations or fail to demonstrate improvement in CSF findings despite high-dose fluconazole monotherapy are administered alternative azoles or placed on intrathecal amphotericin B therapy[11,14].

In the first reported case of coccidioidal meningitis in Korea, the patient experienced recurrent and worsening meningitis symptoms despite receiving maintenance therapy with azole antifungals; however, significant improvement was observed after the administration of intrathecal amphotericin B[6]. Our patient exhibited no improvement in impaired consciousness despite the use of fluconazole and voriconazole; thus, intrathecal amphotericin B was considered. However, repeated EVD insertion and lumbar drainage did not affect the patient's hydrocephalus, and a local infection developed at the lumbar drainage site. Intrathecal amphotericin B could not be administered to avoid the risk of exacerbating the patient's hydrocephalus and spreading the infection through the drainage site.

Coccidioidomycosis may be effectively diagnosed by clinically suspecting the possibility of infection based on a history of travel or residence in an endemic area. Pulmonary coccidioidomycosis is often undetected because its initial symptoms resemble those of bacterial or viral infections[2]. To confirm the diagnosis, a biopsy and fungal culture can be conducted on the involved tissue; however, considerable time is required to obtain fungal culture results. Although our patient resided in Los Angeles, coccidioidomycosis was not suspected during the first visit because of the nonspecificity of his systemic symptoms. Information concerning the patient's history of jogging in dusty neighborhoods was only obtained immediately before the skin biopsy, and this paucity of available information delayed the diagnosis. This patient presented with non-specific skin lesions such as erythematous plaques with recurrent vesicles; however, histopathological findings from the skin lesions provided the first indication of coccidioidomycosis, which was crucial for the diagnosis of the condition. *Coccidioides* species were identified in fungal cultures conducted on the skin, lung, and CSF but only after the disease had progressed to cause neurological impairment. Although antifungal treatment was initiated simultaneously with the skin biopsy, the disease had rapidly progressed to meningitis. Therefore, it was difficult to prevent further disease progression.

Herein, we report a case of coccidioidal meningitis that occurred as a complication of disseminated coccidioidomycosis invading the skin and lungs in a healthy young man with no underlying diseases. While Korea is not an endemic area for *Coccidioides*, its incidence has increased over the past 20 years with increased travel to high-risk areas. Delayed diagnosis of coccidioidal meningitis can be fatal even in immunocompetent patients. Therefore, coccidioidomycosis should be suspected when patients who visit endemic areas present with lung consolidation and nodules accompanied by nonspecific symptoms such as fever, myalgia, and skin lesions. Furthermore, thorough history-taking and prompt diagnosis are essential for the timely treatment and prevention of complications.

ACKNOWLEDGEMENT

The authors declare that there is no acknowledgment.

CONFLICT OF INTEREST

In relation to this article, we declare that there is no conflict of interest.

ORCID

Yi Na Yoon: 0000-0001-8050-1750
Ji Won Lim: 0009-0000-2069-8053
Hyung Seok Son: 0000-0002-0607-7530
Young Ah Cho: 0000-0002-3082-0857
Yang Won Lee: 0000-0003-1268-1248
Yong Beom Choe: 0000-0002-3074-7602
Da-Ae Yu: 0000-0001-8158-9766

PATIENT CONSENT STATEMENT

The patient provided written informed consent for the publication and the use of his images.

REFERENCES

1. Bays DJ, Thompson GR 3rd. Coccidioidomycosis. Infect Dis Clin North Am 2021;35:453-469
2. Crum NF. Coccidioidomycosis: A contemporary review. Infect Dis Ther 2022;11:713-742
3. Benedict K, McCotter OZ, Brady S, Komatsu K, Sondermeyer Cooksey GL, Nguyen A, et al. Surveillance

for coccidioidomycosis - United States, 2011-2017. MMWR Surveill Summ 2019;68:1-15
4. Kim B, Kim N, Hwang YY, Kang HR, Shin S. Molecular identification of *Coccidioides posadasii* in synovial fluid in Korea. Lab Med Online 2021;11:60-63
5. Lee JM, Bae SH, Lee SN, Park KH, Park CK, Yoon HK, et al. A case of disseminated coccidioidomycosis involving the lymph nodes, the skin, and the brain. Korean J Med 2012;82:734-738
6. Lee JW, Kim SI, Kim YJ, Kwon JC, Lim YJ, Park MH, et al. A case of coccidioidal meningitis. Infect Chemother 2012; 44:75-79
7. Wang XL, Wang S, An CL. Mini-review of published reports on coccidioidomycosis in China. Mycopathologia 2015;180:299-303
8. McConnell MF, Shi A, Lasco TM, Yoon L. Disseminated coccidioidomycosis with multifocal musculoskeletal disease involvement. Radiol Case Rep 2016;12:141-145
9. Winn WA. The use of amphotericin B in the treatment of coccidioidal disease. Am J Med 1959;27:617-635
10. Einstein HE, Holeman CW Jr, Sanddidge LL, Holden DH. Coccidioidal meningitis. The use of amphotericin B in treatment. Calif Med 1961;94:339-343
11. Ho J, Fowler P, Heidari A, Johnson RH. Intrathecal amphotericin B: A 60-year experience in treating coccidioidal meningitis. Clin Infect Dis 2017;64:519-524
12. Johnson RH, Einstein HE. Coccidioidal meningitis. Clin Infect Dis 2006;42:103-107
13. Vincent T, Galgiani JN, Huppert M, Salkin D. The natural history of coccidioidal meningitis: VA-Armed Forces cooperative studies, 1955-1958. Clin Infect Dis 1993;16: 247-254
14. Galgiani JN, Ampel NM, Blair JE, Catanzaro A, Geertsma F, Hoover SE, et al. 2016 Infectious Diseases Society of America (IDSA) clinical practice guideline for the treatment of coccidioidomycosis. Clin Infect Dis 2016;63: e112-e146

Copyright@2023 by The Korean Society for Medical Mycology